

Perioperative Very Late Stent Thrombosis treated with Thrombosuction

S Sikdar MD,DM, D Kumar MD, DM, S Basu MD, DM, V Mohanty MD, DM, J Naik MD, DM, S Banerjee MD, DM

Medical Superspecialty Hospital, 127 Mukundapur Kolkata, India

INTRODUCTION

With widespread use of Drug Eluting Stents (DES), perioperative dual antiplatelet issues are becoming more frequent. The risk of perioperative bleeding needs to be balanced against the devastating complication of stent thrombosis since mortality rates for stent thrombosis range from 20% to 45%¹. Usually these issues are a concern within the first year after stent implantation. We report a case where perioperative withdrawal of dual antiplatelets prior to a non-cardiac surgery lead to stent thrombosis and cardiogenic shock, five years post implantation.

CASE REPORT

A 64 year non diabetic, non hypertensive lady had a 3x 23 sirolimus eluting stent (Cypher®) for 90 % mid Left Anterior Descending (LAD) coronary artery eccentric lesion implanted 5 years ago. She was on regular dual antiplatelet therapy consisting of Aspirin 75 mg and Clopidogrel 75 mg. She came for cardiac clearance for laproscopic cholecystectomy a week before surgery, with a history of atypical chest pain. A coronary angiogram was done which revealed only minor plaque in mid LAD proximal to the stented portion. Other coronary arteries were normal. Clearance was granted. She was taken off dual antiplatelet five days before surgery with concurrence of the cardiologist

as per usual practice. At the time she was taken to the operating theatre(OT) her electrocardiogram(ECG) and Echocardiogram were normal. Half an hour into surgery she developed hypotension (BP 80/60), ST elevation in lead I in ECG monitor leads and falling oxygen saturation. A 12-lead ECG showed anteroseptal ST elevation myocardial infarction (STEMI). Echocardiography suggested the LAD territory was hypokinetic with a left ventricular ejection fraction (LVEF) of 40% from eyeball appearances. Thrombolysis was out of question in view of surgery. After surgery she was transferred to the catheter lab, already on mechanical ventilator support, after a loading dose of clopidogrel (300mg) and aspirin (300mg). Coronary angiography (CAG) revealed stent thrombosis with a filling defect visible inside the stent diagonally with sluggish distal flow (Fig 1). An XB 3.5 guiding catheter (Johnson & Johnson Medical®) was used to engage the left system and the LAD was wired. A thrombsuction run was done and white clot aspirated. Since flow improved after nitroprusside infusion (Fig 2) we decided to terminate the procedure. Because of the fear of bleeding from the gallbladder bed GP IIb/IIIa inhibitors were not used. There was resolution of ST segment elevation postprocedure and the patient made an uneventful recovery. She was started on dual antiplatelets prior to discharge and is on regular follow up for more than a year.

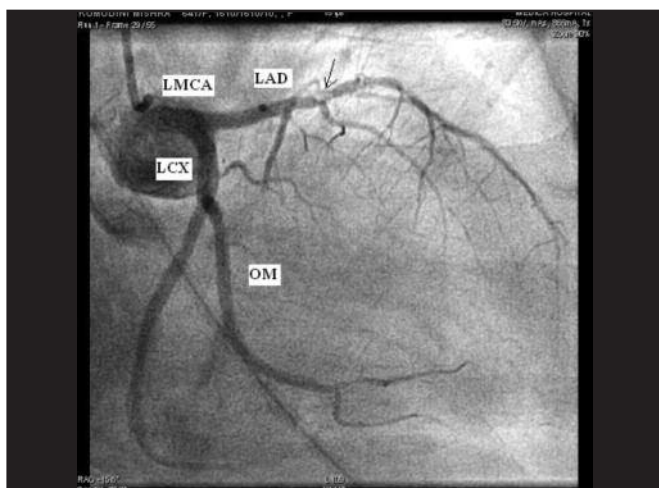


Fig. 1: Left coronary angiogram in Right Anterior Oblique view with caudal tilt showing thrombus inside the Left Anterior Descending (LAD) stent at diagonal origin. Note the haziness marked by arrow, indicating a filling defect inside the stent. LCX= Left circumflex, LMCA= Left Main Coronary Artery, OM = Obtuse Marginal.

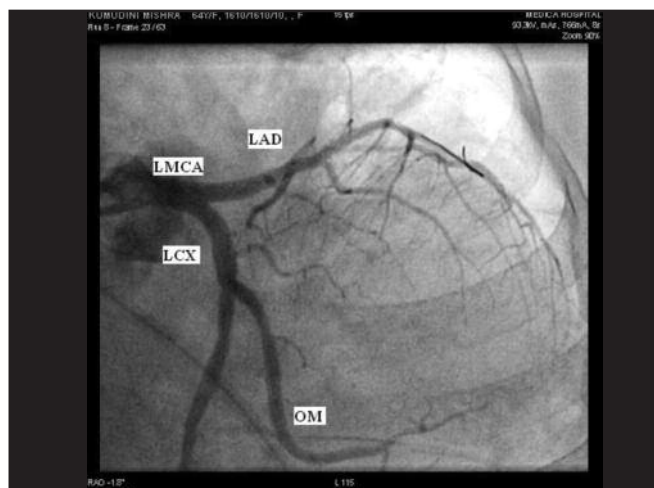


Fig. 2: Post thrombosuction left coronary angiogram in the same view shows that the filling defect has disappeared. Abbreviations are as in the previous figure.

This article was accepted: 13 February 2012

Corresponding Author: Sunandan Sikdar, Medical Superspecialty Hospital, 127 Mukundapur Kolkata, India

Email: sunandansikdar@gmail.com

DISCUSSION

Current American College of Cardiology (ACC)/American Heart Association (AHA) /Society for Cardiovascular Angiography and Interventions (SCAI) recommendations for the prevention of stent thrombosis after coronary stent implantation state that, at a minimum, patients should be treated with clopidogrel 75 mg and aspirin 325 mg for 1 month after bare-metal stent implantation, 3 months after sirolimus drug eluting stent (DES) implantation, 6 months after paclitaxel DES implantation, and ideally, up to 12 months if they are not at high risk for bleeding. However reports of very late stent thrombosis (defined as stent thrombosis after 1 year) in perioperative period is scant. Late acquired incomplete stent apposition due to positive remodelling, delayed endothelization and hypersensitivity reactions, possibly to polymers coated on the stent and chronic pan-arterial inflammation have been implicated as contributing factors to delayed stent thrombosis. Stenting of small vessels, multiple lesions, long stents, overlapping stents, ostial or bifurcation lesions, prior brachytherapy, suboptimal stent result (underexpansion, malapposition, or residual dissection), low ejection fraction, advanced age, diabetes mellitus and renal failure are the substrates where risk of stent thrombosis is higher¹. Sousa *et al* have shown that healing and endothelization of stent struts may continue up to 4 years after DES implantation². Noncardiac surgical procedures is the second commonest cause of premature dual antiplatelet therapy discontinuation (12–30% of discontinuation cases)³. As far noncardiac surgery is concerned, the continuation of dual antiplatelet therapy in the perioperative period increases bleeding risk, whereas dual antiplatelet therapy interruption increases stent thrombosis risk. There is little or no indication to interrupt antiplatelet drugs for dental procedures as oral bleeding can be easily controlled but for more invasive surgeries decision is difficult. For patients treated with DES who are to undergo subsequent procedures that mandate discontinuation of thienopyridine therapy, aspirin should be continued if at all possible and the thienopyridine restarted as soon as possible after the procedure¹. In some surgeries where the fear of bleeding is uppermost in the mind of the surgeon (e.g neurosurgery, spinal surgery, eye surgery) , oral antiplatelet has to be stopped 5 days or more before surgery. In these scenarios, an option is the use of intravenous, short-acting glycoprotein IIb/IIIa inhibitors after discontinuation and until 8–12 hours before surgery³. Thus many patients undergoing DES implantation requires surgery at a future time point and the decision “ to or not to ” withhold becomes a double edged sword. One study⁴ of 141 patients who underwent surgery requiring antiplatelet agent discontinuation within 12

months of DES implantation found a 5% stent thrombosis rate, the majority of which were lethal . The authors found that the predictors of Stent thrombosis to be older age (> 65 yrs) , use of paclitaxel eluting stents and prolonged period (> 7 days) of clopidogrel discontinuation. However none of these were present in our patient, though sirolimus related stent thrombosis has also been reported⁵ about after noncardiac surgery 3 years after implantation.

CONCLUSION

Our case is unique in view of the fact that we had a very late perioperative Stent thrombosis (~ 5 years), which would have been fatal had it been in a non cath lab centre. As our case shows time of implant may not be protective in few cases and caution should be exercised in daily practice before withholding dual antiplatelet therapy prior to surgery and the risk of stent thrombosis fully explained to everyone concerned. The case also lends support to the AHA guideline that aspirin should be continued if at all possible and the thienopyridine restarted as soon as possible after the procedure to minimize the concerns about late-stent thrombosis . Our experience support the presumption that the duration of dual antiplatelet therapy should indeed be extended especially in patients in whom first generation DES is implanted and those with higher risk of stent thrombosis mentioned above. The result suggest that stand alone thrombosuction without ballooning or stenting may be sufficient in many cases.

REFERENCES

1. Grines CL, Bonow RO, Casey DE, Jr, Gardner TJ *et al*. Prevention of Premature Discontinuation of Dual Antiplatelet Therapy in Patients With Coronary Artery Stents: A Science Advisory From the American Heart Association, American College of Cardiology, Society for Cardiovascular Angiography and Interventions, American College of Surgeons, and American Dental Association, With Representation From the American College of Physicians. *Circulation* 2007; 115: 813-8.
2. Sousa JE, Costa MA, Farb A, Abizaid A *et al*. Images in cardiovascular medicine. Vascular healing 4 years after the implantation of sirolimus-eluting stent in humans: a histopathological examination. *Circulation* 2004; 110: e5-6
3. Moussa ID, Colombo A. Antiplatelet Therapy Discontinuation Following Drug-Eluting Stent Placement: Dangers, Reasons, and Management Recommendations. *Catheterization and Cardiovascular Interventions* 2009; 74: 1047-54.
4. Rhee SJ, Yun K H, Lee SR, Chae JK, Nam CW, Jun DH, Jeong JW. Drug-eluting stent thrombosis during perioperative period. *Int Heart J* 2008; 49: 135-42.
5. Nasser M, Kapeliovich M, Markiewicz W. Late thrombosis of sirolimus-eluting stents following noncardiac surgery. *Catheter Cardiovasc Interv* 2005; 65: 516-9.