

Isolated Optic Neuritis Secondary to Presumed Tuberculosis In An Immunocompetent Child

Norazizah Mohd Amin, MD*, Wan Hazabbah Wan Hitam, MSurg (Ophthal)*, Rohaizan Yunus, MMed (Rad)**, I Shatriah, MMed (Ophthal)*

*Department of Ophthalmology, **Department of Radiology, School of Medical Sciences, Universiti Sains Malaysia, 16150 Kubang Kerian, Kelantan, Malaysia

SUMMARY

Isolated optic neuritis as a presenting sign of tuberculosis in children is uncommon. We report a case of an immunocompetent child who displayed features of bilateral optic neuritis secondary to presumed tuberculosis. It is essential to highlight this alarming presentation in a child, as the presence of tuberculosis has re-emerged as a serious public health problem especially in developing countries.

KEY WORDS:

Isolated Optic Neuritis, Presumed Tuberculosis, Immunocompetent, Child

INTRODUCTION

Tuberculosis (TB) has been declared as a global emergency by the World Health Organization as it remains the most common single cause of morbidity and mortality worldwide. In 2009, it caused 1.7 million deaths including 380 000 people with HIV and 9.4 million new cases including 1.1 million cases among people with HIV infection. TB primarily affects the lungs but the proportion of cases with extrapulmonary TB has increased in recent years in immunocompromised individuals especially in children and females.

TB is still a public health dilemma in Malaysia despite preventive measures and control taken. The number of new cases has increased from 15 000 new cases in 2002 up to 16 665 in 2006¹. Ishak *et al* in 2008 reported an observational case series of ocular TB in immunocompetent patients in a tertiary hospital in Malaysia². Granulomatous anterior uveitis (75%) was the most common ocular finding observed, followed by posterior uveitis (58%), papillitis (8%), choroidal tubercle (8%), panophthalmitis (8%) and masquerade syndrome mimicking ocular tumor (8%)².

Intraocular manifestations of TB are rare in children. Isolated optic neuritis as a presenting sign of TB within paediatric population is extremely uncommon. An immunocompetent child with isolated bilateral optic neuritis secondary to presumed TB is presented in this report. This case highlights a rare appearance of childhood TB in a developing country where the dreaded TB infection remains endemic.

CASE REPORT

An 11-year-old healthy girl presented with complaint of blurred vision in the left eye for five days prior to consultation. It was associated with retro-orbital discomfort and pain on ocular movement. There was no history of eye redness or diplopia. She denied recent upper respiratory tract infection, trauma or vaccination. There was no history of convulsions, altered sensorium or neurological deficits.

The patient has a strong family history of recent TB infection. Her father has been treated for active pulmonary TB, while her grandfather had completed the regime two years back. However, there was no history of prolonged fever, chronic cough, haemoptysis, loss of appetite or weight loss. She completed her vaccination schedules including the BCG vaccination.

Her visual acuity was 6/24 improving to 6/12 with a pinhole in her right eye and 2/60 even with a pinhole in her left eye. The left pupil reaction was sluggish with the presence of afferent pupillary defect. Anterior segment examination in both eyes was essentially normal and quiet.

Fundoscopy revealed diffuse hyperaemic swollen optic disc with evidences of tortuous and dilated veins in both eyes, which were more prominent in the left eye (Figure 1). The macula and retina were normal. Colour vision testing was performed with Farnsworth-Munsell 100-hue test affecting in both eyes. Centrocecal scotoma was documented with visual field testing in the right eye, while the patient refused to complete the test in her left eye.

General examination revealed a healthy, conscious and well orientated child. Central nervous system examinations including other cranial nerves were essentially normal. Respiratory examination was normal, and no organomegaly or lymphadenopathy elicited.

Baseline haematological investigations revealed evidence of anaemia with haemoglobin 8.0 gm % and ESR was 107 mm/hour. Connective tissue screening and work-up for sarcoidosis were negative. The Mantoux test was significantly positive with 35 mm diameter area of induration. Lumbar puncture was performed with opening pressure of 20 cm H₂O. The biochemistry analysis was normal with a negative culture result. Electrophoresis of cerebral spinal fluid did not reveal oligoclonal bands.

This article was accepted: 8 January 2012

Corresponding Author: Shatriah Ismail, Department of Ophthalmology, School of Medical Sciences, Universiti Sains Malaysia, 16150 Kubang Kerian, Kelantan, Malaysia Email: shatriah@kck.usm.my

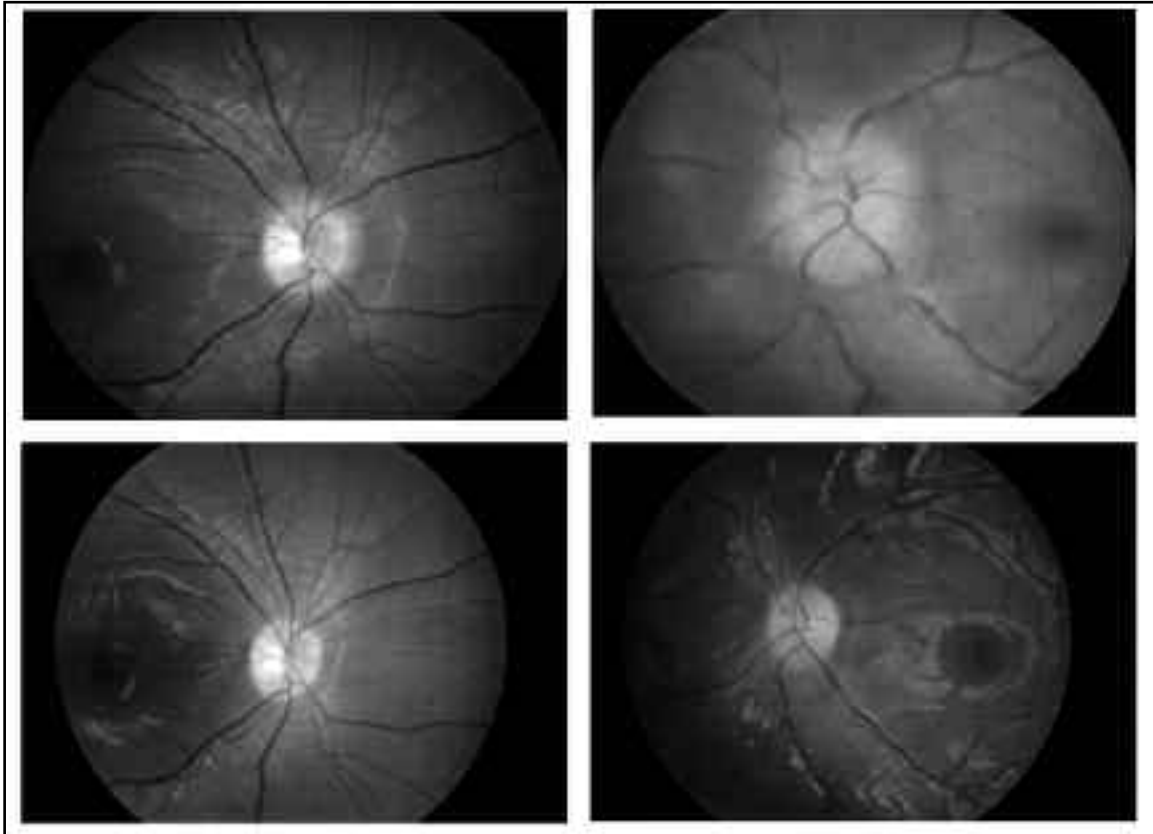


Fig. 1: (a and b): Fundus photograph shows swollen optic disc in both eyes, which was worse in the left eye on presentation. (c and d): Slight pallor of the optic disc in both eyes is observed at one year after termination of anti-tuberculous treatment.

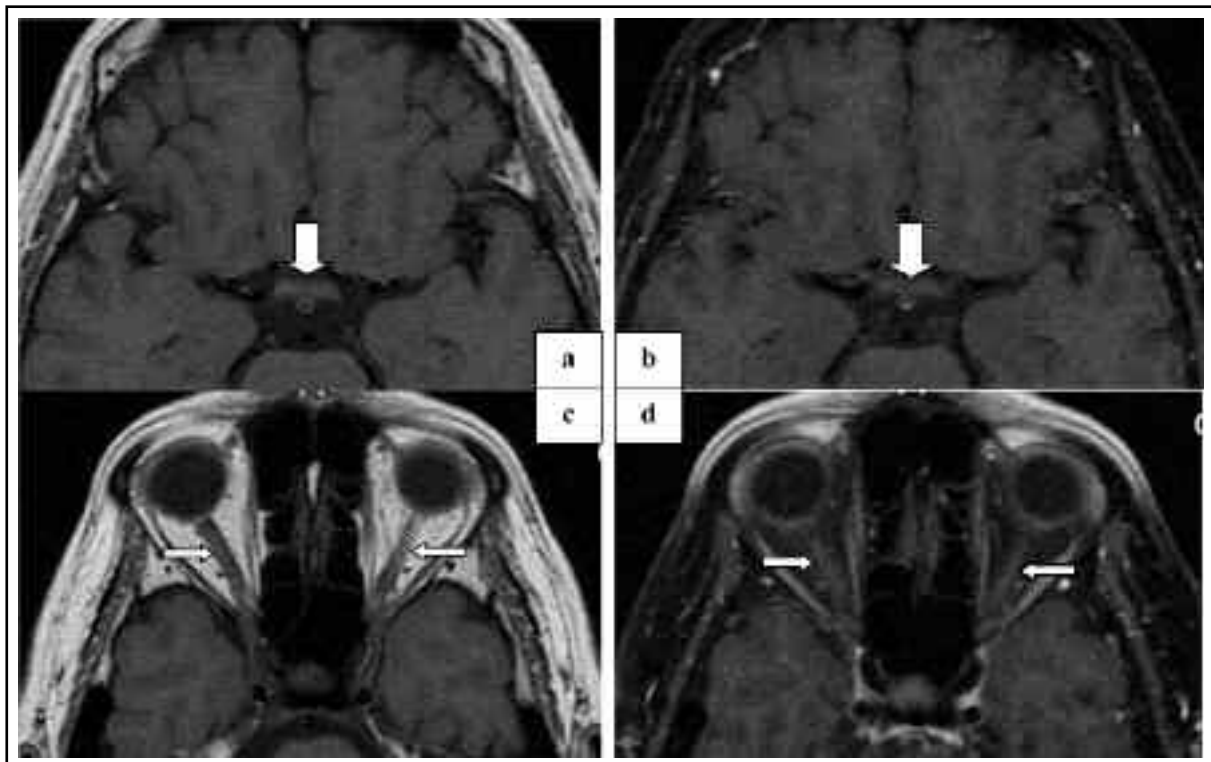


Fig. 2: (2a and 2c - T1WI: 2b and 2d - T1WI with gadolinium): MRI of the orbit at presentation shows enhancement of the optic chiasma (wide arrow) and bilateral optic nerve enhancement (narrow arrow).

The chest x-ray was reported normal. The Magnetic Resonance Imaging (MRI) of brain and orbit revealed bilaterally swollen optic nerves and diffuse high signal intensities in the region of the optic nerves on T1 weighted images, suggestive of bilateral optic neuritis (Figure 2). Paranasal sinuses were normal. There was no evidence of sinusitis.

She was started on Directly Observed Treatment anti-tuberculous regime that included isoniazid, rifampicin and pyrazinamide with concurrent prescription of pyridoxine daily for the initial two months. She showed significant clinical improvement after completing the intensive course of anti-tuberculous regime. She completed the treatment after nine months with no notable serious side effects.

One month after completing the anti-tuberculous therapy, her visual acuity improved to 6/7.5 in the right eye and 6/12 in the left eye. Ocular examination revealed a normal pupillary response with no relative afferent pupillary reflex. The fundoscopy assessment showed resolving optic disc swelling in both eyes. A repeat ESR was 54 mm/hour.

Her best corrected visual acuity was 6/7.5 in both eyes at one year after termination of the anti-tuberculous treatment. The optic disc was slightly pale bilaterally. Colour vision and visual field testing were normal. She has not undergone any similar attacks or recurrence for the past two years of follow-ups since the initial diagnosis was made.

DISCUSSION

Reports prove that ocular TB as one of an extrapulmonary form of diseases caused by *Mycobacterium tuberculosis* is significantly on the increase. It may involve various segments of the eye with diverse clinical manifestations that include anterior uveitis, intermediate uveitis, posterior uveitis, retinitis and retinal vasculitis, neuroretinitis and optic neuropathy, and endophthalmitis or even panophthalmitis.

Optic neuropathy develops either from direct infection induced by the *mycobacteria* or from a hypersensitivity to the infectious agent. Optic nerve involvement may manifest as an optic nerve tubercle, papilloedema, papillitis, retrobulbar neuritis, neuroretinitis or opticochiasmatic arachnoiditis.

Definitive diagnosis of TB is always a challenge. Our patient presented with typical symptom of bilateral optic neuritis, with no other systemic involvement or manifestation. The presumptive cause of TB was high in our patient in view of history of close contact with TB patients, high ESR and significantly indurated skin reaction after Mantoux test. The therapeutic response that is characterized by improvement in vision in both eyes and the decrease in thickness of optic nerves in MRI following anti-tuberculous treatment also supports the diagnosis of ocular TB in our patient.

As the cerebral spinal fluid outgoing pressure and analysis were normal in our patient, we feel that it is less likely that she has optic neuropathy related to early tubercular meningitis. Idiopathic bilateral optic neuritis is still a possibility that we are unable to exclude completely in this case.

In children, the optic nerve involvement is frequently related to tubercular meningitis which occurs mainly at the retrobulbar level³. Isolated optic neuritis had been described in adults with TB. Based on our PubMed search, isolated optic neuritis due to TB has not been reported before in children. It is important to have a high degree of suspicion of TB when treating children with acute optic neuritis in widespread TB areas. However, TB has never been reported as a cause of childhood optic neuritis in large case series.

The Centers for Disease Control, Atlanta in 2003 recommends the use of all four drugs (isoniazid, rifampicin, pyrazinamide, and ethambutol) for an initial two month period followed by a choice of different options over next four to seven months for treatment of TB. Drug regimens for ocular TB are similar to those for pulmonary or extrapulmonary TB. Our patient responded well to a nine month regime of isoniazid, rifampicin and pyrazinamide.

Optic neuritis had been reported following use of isoniazid in a 10-year old boy who was treated for TB meningitis⁴. To date, there is no published confirmed optic neuritis due to ethambutol in children, though it had been reported extensively in adults.

Ethambutol was avoided to prevent further risk of ocular toxicity in our patient. Ethambutol is in general undesirable in children less than three years of age due to concerns about risk of ocular toxicity and the difficulty in assessing ocular function in young children⁵. During treatment, she was closely monitored for drug toxicity. Her final visual outcome was satisfactory.

In conclusion, TB is a possible cause of optic neuritis in children especially those living in TB endemic area. Early diagnosis and prompt treatment is mandatory to prevent substantial visual loss. It is necessary to alert the managing ophthalmologists of this rare entity.

ACKNOWLEDGEMENT

The authors would like to acknowledge Mrs. Cathy Pinchen-Syakir for her assistance in preparing this manuscript.

REFERENCES

1. National tuberculosis control programme, Disease Control Division. Ministry of Health Malaysia. 2008.
2. Ishak SR, Jaffar NT, Shaharuddin B, Tajudin LSA. Ocular tuberculosis in immunocompetent patients. *International Medical Journal*. 2008; 15: 295-9.
3. Schoeman JF, Andronikou S, Stefan DC, et al. Tuberculous meningitis-related optic neuritis: recovery of vision with thalidomide in 4 consecutive cases. *J Child Neurol*. 2010; 25: 822-8.
4. Kulkarni HS, Keskar VS, Bavdekar SB, et al. Bilateral optic neuritis due to isoniazid (INH). *Indian Pediatr*. 2010; 47: 533-5.
5. World Health Organization. Ethambutol efficacy and toxicity. Literature review and recommendation for daily and intermittent dosage in children. Geneva, Switzerland: WHO, 2006.