

Dapsone Syndrome – First Malaysian Paediatric Case Report

Z Zurina, MRCPCH*, O Elizawaty, MBChB**, S Thevarajah, MMed***, O Norlijah, MRCP*

*Paediatric Department of Faculty of Medicine and Health Sciences, Universiti Putra Malaysia, 43400 UPM Serdang, Selangor, **Paediatric Department, Hospital Serdang, Jalan Puchong, 43000 Kajang, Selangor, ***Dermatology Department, Hospital Kuala Lumpur, Jalan Pahang, 50586 Kuala Lumpur

SUMMARY

Dapsone syndrome is a potentially fatal hypersensitivity reaction to sulphone. We report a 12-year-old girl who developed high grade fever associated with intense jaundice, exfoliative skin rash and hepatomegaly after five weeks of starting the multidrug regimen for the treatment of Hansen's disease. Laboratory investigations revealed presence of leucocytosis with eosinophilia, deranged liver enzymes and an abnormal coagulation profile. Immediate cessation of the offending drug and administration of steroid proved successful. A high level of clinical awareness is fundamental for early diagnosis of dapsone syndrome as initiation of a prompt treatment may lead to rapid recovery.

KEY WORDS:

Dapsone syndrome, Drug hypersensitivity reaction, Drug reaction with eosinophilia and systemic symptoms (DRESS), Leprosy

INTRODUCTION

Dapsone syndrome is a potentially fatal hypersensitivity reaction to sulphone characterised by high fever associated with exfoliative dermatitis and internal organ involvement following exposure to the offending drug.¹ Occurrence of dapsone syndrome is rare and this is the first reported paediatric case from our country. This report deals with a 12-year-old girl who presented with typical features of dapsone syndrome following five weeks of therapy.

CASE REPORT

A 12-year-old girl presented with a week's history of spiking fever associated with loose watery stools, vomiting and poor oral intake. After four days of symptoms, she started to develop progressive right hypochondrial pain and generalized body rash. There was a history of dark coloured urine but no pale stools documented.

Two months prior to presentation, she consulted a dermatologist for a paraesthetic hypopigmented skin lesion over her left forearm and right deltoid region. Her elder brother was diagnosed to have Hansen's disease and had completed therapy. She was empirically started on tablet dapsone 100mg/day and clofazimine 100mg/day in view of history of contact despite a normal skin biopsy result. Tablet rifampicin was added one month later after no improvement

observed following initial therapy. All her medications were discontinued after the first dose of rifampicin following the onset of the above symptoms.

Upon admission she was febrile (temperature 39.80C), toxic looking and appeared lethargic. She was deeply jaundiced, pale and mildly dehydrated. She was tachycardic (pulse rate 120/min.) and normotensive (blood pressure 97/50mmHg). There was an erythematous exfoliative maculopapular rash involving her face, torso and all four limbs with tender hepatomegaly measured 8cm below right costal margin. No lymphadenopathy noted.

Laboratory investigations revealed Hemoglobin 8.1g/dl, total white count 39,000/mm³ (38%neutrophil, 29%lymphocytes, 28%monocytes and 4%eosinophil), platelet count 403,000/mm³, erythrocytes sedimentation rate was 88mm/hr and C-reactive protein 6.06mg/dL. She had deranged liver enzymes and coagulopathy (total bilirubin 493.2µmol/L, direct bilirubin 256.5µmol/L, aspartate transaminase AST365U/L, lactate dehydrogenase 1098U/L, alkaline phosphatase 404U/L, prothrombin time 27.2sec, activated partial thromboplastin time 55.8sec and International Normalised Ratio INR1.99). Septic screening (blood, urine and stool) were negative for bacterial growth. Cytomegalovirus IgM was detected and other serology test for hepatitis A, hepatitis B, hepatitis C virus, Ebstein-Barr virus and leptospira IgM were negative. She had a low complement level (C3 0.48g/L and C4 0.06g/L) but other autoimmune marker was negative. Antistreptolysin O titre and blood film for malaria parasite was negative. Ultrasonogram of hepatobiliary tract revealed a thickened gall bladder wall associated with pericholecystic collection and positive sonographic Murphy's sign suggestive of acute acalculous cholecystitis. Microscopic examination of the skin biopsy showed non-specific perivascular lymphocytic infiltrates.

Diagnosis of dapsone syndrome was not suspected until later when she failed to show any clinical response to an adequate dose of broad spectrum antibiotics. Intravenous hydrocortisone was started and a dramatic improvement was observed in both her clinical and biochemical markers. Systemic steroid was continued for ten days before it was tapered down over two-week period. She was allowed home after all her blood parameters returned to normal.

This article was accepted: 23 December 2011

Corresponding Author: Zurina Zainudin, Department of Paediatrics, Faculty of Medicine and Health Sciences, University Putra Malaysia (UPM), 43400 Serdang, Selangor, Malaysia Email: zurina@medic.upm.edu.my / zue.zurina@gmail.com

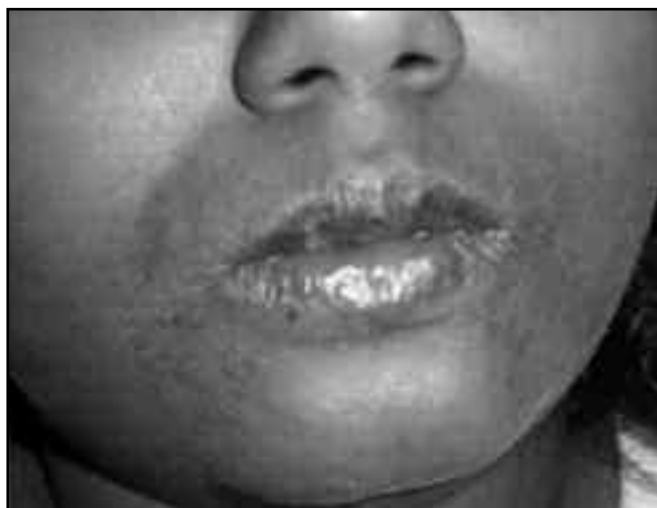

Fig. 1: Generalized blanching erythematous exfoliative maculopapular rash involving her face.

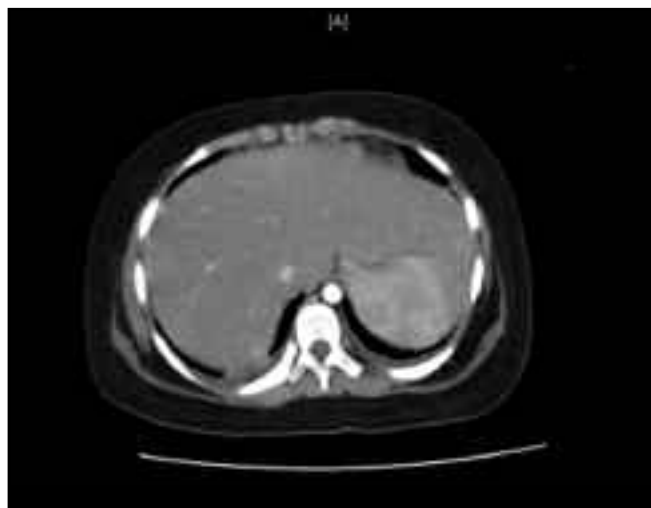


Fig. 2: Computed tomography of the abdomen revealed a homogenous enlarged liver, poorly distended gallbladder with presence of fluid in the gallbladder bed, ascites and bilateral pleural effusion.

DISCUSSION

The importance of antimicrobial and anti-inflammatory activity of Dapsone had long been identified. It has remained as a first-line therapy for leprosy for over decades and has also been found to be of value in the treatment of various skin diseases as well as for prophylaxis of *Pneumocystis carinii*^{1,2}. Although it is considered a safe drug, its use may be associated with various serious side effects including dapsone syndrome^{1,2}.

Dapsone syndrome is a rare but potentially fatal hypersensitivity reaction characterized by high grade fever associated with exfoliative dermatitis and internal organs involvement manifested within several weeks to as long as 6 months after the initiation of dapsone¹. It is considered as part of syndrome of drug rash with eosinophilia and systemic symptoms (DRESS), a serious adverse reaction that has been reported in association with various drugs^{1,2}.

This case illustrates the classical presentation of dapsone syndrome fulfilling all the criteria suggested by Richardus and Smith. These include presence of at least two signs and symptoms (fever, skin eruption, lymphadenopathy and liver pathology) manifesting within 8 weeks of starting therapy and resolution following withdrawal of treatment. They also recommended that the symptoms should be unrelated to leprosy and not attributable to any other drugs used simultaneously³.

Our patient was started on multidrug regimen for the treatment of leprosy. The possibility of her symptoms being induced by clofazimine was doubtful as hepatotoxicity associated with clofazimine has never been reported in any indexed medical journal before. In addition the child only received a single dose of rifampicin which made it a very unlikely causative agent either.

Serum antibody titre for cytomegalovirus (CMV) was later detected to be positive however a more specific test CMV-DNA (polymerase-chain reaction) were not carried out. CMV infections in an immunocompetent patient is known to be asymptomatic or results in a mild "infectious mononucleosis like" illness. Very rarely it produced prolonged fever with severe hepatitis⁴. However acalculous cholecystitis and pleural effusion associated with CMV infection in an otherwise healthy patient has been reported in world literature. Most of the clinical features that our patient presented with could be attributed to an acute CMV infection except for the presence of eosinophilia and exfoliative dermatitis.

Management of the Dapsone syndrome includes immediate discontinuation of the offending agent and supportive therapy depending on the organ involvement^{1,2}. Our patient responded well and showed dramatic recovery following the introduction of glucocorticosteroid even though there has been no comparative studies done looking at its effectiveness. Her treatment was slowly tapered down over a period of 4 weeks to avoid recurrence of symptoms as Dapsone may persist in the system for up to one month via protein binding and enterohepatic circulation^{2,5}. Rapid cessation of steroid may result in relapse.

CONCLUSION

This case illustrates the typical manifestation of Dapsone syndrome. A high level of clinical awareness is fundamental for early diagnosis as immediate cessation of the drug and early commencement of systemic corticosteroid may lead to rapid recovery and avoiding severe morbidity or even death. Delayed recognition of the syndrome could also lead to unnecessary extensive investigation.

ACKNOWLEDGEMENT

We thank all the staffs of paediatric ward 5B of Hospital Serdang for their assistance in the management of our patient. We also wish to thank Dr. Mohan a/l Arumugam of Dermatology Unit of Hospital Serdang for carrying out the skin biopsy procedure and his contribution in the management of our patient.

REFERENCES

1. Kosseifi SG, Guha B, Nassour DN, Chi DS, Krishnaswamy G. The Dapsone hypersensitivity syndrome revisited: a potentially fatal multisystem disorder with prominent hepatopulmonary manifestations. *J Occup Med Toxicol* 2006; 1: 9.
2. Siegfried E, Nopper AJ, Draelos Z *et al.* Principles of Treatment in Pediatric Dermatology. In: Schachner LA, Hansen RC (3rd ed). *Pediatric Dermatology*. Philadelphia: Elsevier Limited, 2003: 122-4.
3. Richardus JH, Smith TC. Increased incidence in leprosy of hypersensitivity reactions to dapsone after introduction of multidrug therapy. *Lepr Rev* 1989; 60: 267-73.
4. Powell DA. Hansen Disease (*Mycobacterium leprae*). In: Behrman RE, Kliegman RM, Jenson HB (17th ed). *Nelson Textbook of Pediatrics*. Philadelphia: Saunders, 2004: 974-5.
5. Alves-Rodrigues EN, Ribeiro LC, Silva MD, Takiuchi A, Fontes CJ. Dapsone syndrome with acute renal failure during leprosy treatment: case report. *Braz J Infect Dis* 2005; 9 (1): 84-6.