

Habitual Non-Traumatic Cricothyroid Joint Dislocation: A Rare Case of Rotated Larynx

M Irfan, MD, MMed (ORL-HNS), D Yahia, MBBS, N H Nik Fariza Husna, MD, MMed (ORL-HNS), W D Wan Shah Jihan, MBBS, MMed (ORL-HNS), A Baharudin, MBBS, MMed (ORL-HNS)

Department of Otorhinolaryngology-Head & Neck Surgery, School of Medical Sciences, Universiti Sains Malaysia Health Campus, 16150 Kota Bharu, Kelantan, Malaysia

SUMMARY

A case of a 21 year old gentleman is described, with no history of preceding trauma, presenting with intermittent dysphagia to solids and fluids for 4 years. Neck examination at rest was normal. However on deep inspiration, the right thyroid lamina protrudes or becomes more prominent. The patient is able to return the larynx to its normal position with manual manipulation. Laryngeal examination with fiberoptic scope during rest and deep breath shows gross rotation of the laryngeal structures for more than 60° on deep breath, with the vocal cords axis rotated to the left side. Management was conservative.

KEY WORDS:

Cricothyroid joint, Dislocation, Habitual

INTRODUCTION

The larynx possesses small joints that enable the airway conduit to accommodate the varied range of movements that is required for voice production and effective protection of the larynx. Among them are the cricothyroid joint (CTJ). It is a synovial joint which articulates the inferior horn of the thyroid cartilage to the facet of the cricoid cartilage. This allows the thyroid cartilage to glide forward or backward on the cricoid cartilage. By moving the thyroid angle anteriorly, the vocal cord will be lengthened and the tension is achieved. The muscle involved is the cricothyroid muscle. The cricothyroid joint, as for the other synovial joints are subject to dislocation. It can be traumatic or habitual in etiology¹. The phenomenon may be attributed to the laxity of the muscles or ligaments, which in normal condition hold the larynx in position.

CASE REPORT

A 21-year-old Malay male presented with a four year history of intermittent anterior neck swelling. The swelling did not increase in size but was only noticeable after he takes a large bolus of solid food or after taking a deep breath. It was also associated with dysphagia, hoarseness and mild dyspnea.

Neck examination at rest was normal. On deep breath, the normal laryngeal prominence was lost and the right thyroid lamina became prominent in the midline. Voluntary inspiration with neck extension revealed tense left strap and sternocleidomastoid muscles, seen around neck when the

larynx became rotated. The patient was able to reposition the larynx to the normal position. Direct laryngeal examination at rest showed normal position of the arytenoid prominence with normal vocal cord axis (Figure 1). During deep breath, laryngeal examination showed gross rotation of the laryngeal structures (Figure 1b). CT scan was performed and the diagnosis of rotated larynx was confirmed (Figures 2a&b).

The patient was assessed by a speech therapist using the perceptual method with free conversation voice sample. He was found to have thoracic type breathing and was able to vocalize 12 words in one sentence. The voice quality and pitch loudness were appropriate.

The final diagnosis of recurrent habitual dislocation of the larynx secondary to anatomical and functional abnormality of the neck muscles was established. Non-surgical conservative management which includes breathing and speech exercise was instituted. A follow up visit showed the patient could tolerate the symptoms.

DISCUSSION

CTJ dislocation is rarely reported. Common traumatic causes for CTJ dislocation are related to known events; such as dental procedures, choking or being strangled from behind, trauma from windshield or steering wheel injuries, struck in the neck by assailants and attempted hanging². A non-traumatic cause is rarely described in the literature. Knight in 1960 published a series of 9 cases of CTJ dislocation, 8 of them developed the symptoms following physical traumatic event (sports, motor vehicle accident, and acute head turning or leaning backwards) and only 1 without any preceding history of trauma. However, the single non-traumatic CTJ dislocation case was successfully reduced with finger manipulation and the was no repeated event following treatment².

In this case, there was no significant history of trauma to the laryngeal framework and the patient started to notice his problem 4 years prior to the presentation. There is a possibility that he already had a degree of CTJ laxity, combined with muscle abnormality or any degree of muscle incoordination. In a recent 50 cadaveric laryngeal specimens study, Windisch revealed 3 types of cricothyroid articular joint surfaces morphology. 17% of the specimens (described as Type 3) showed the articular surface on the thyroid and

This article was accepted: 11 November 2011

Corresponding Author: Irfan Mohamad, Department of Otorhinolaryngology-Head & Neck Surgery, School of Medical Sciences, Universiti Sains Malaysia Health Campus, 16150 Kota Bharu, Kelantan, Malaysia Email: irfan@kb.usm.my

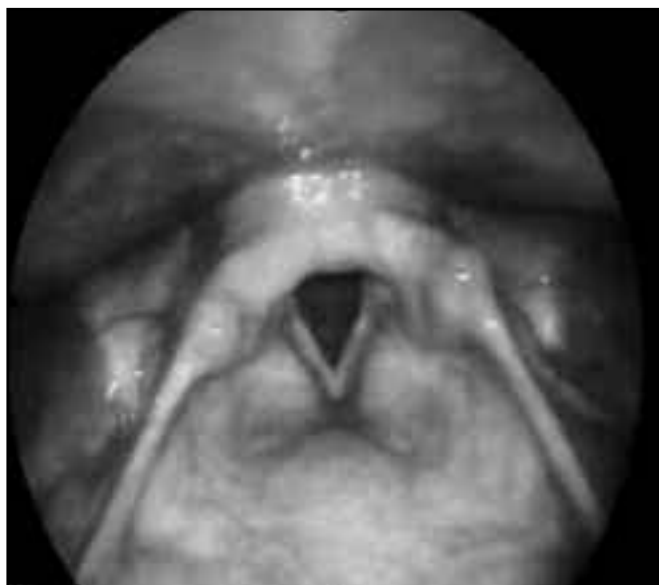

Fig. 1a: Appearance of laryngoscopic finding at rest.

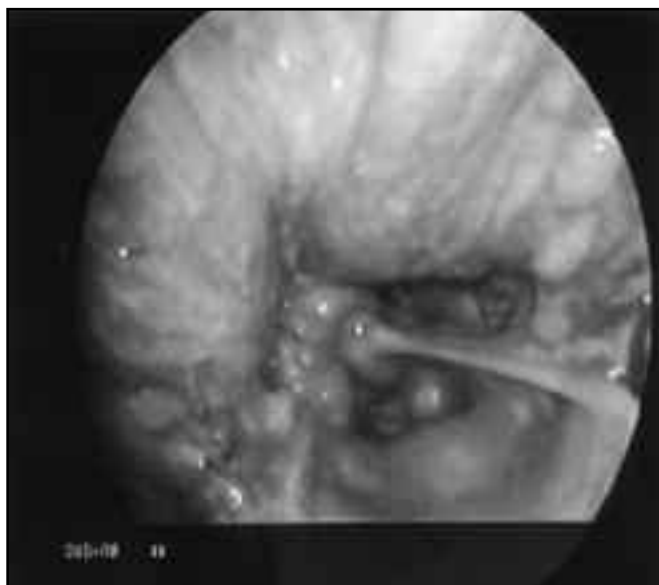


Fig. 1b: The laryngeal inlet rotated to the left.

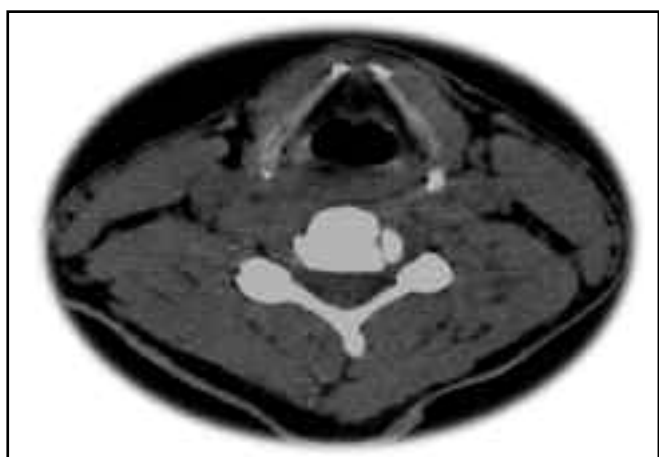


Fig. 2a: CT scan at rest.

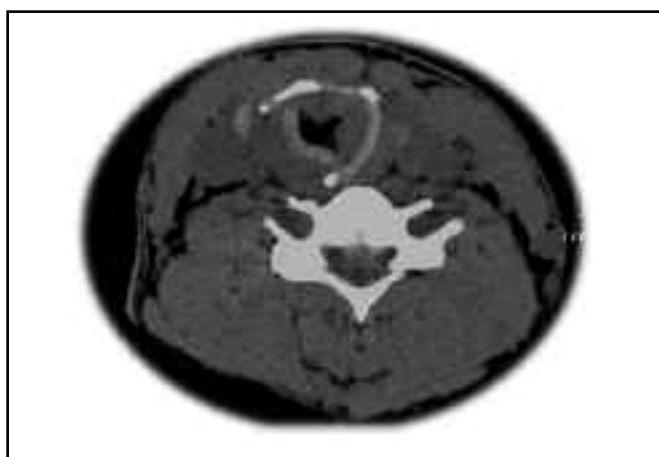


Fig. 2b: CT scan during phonation showed rotation of the inlet axis to the left.

cricoid was flat or showed a tiny protuberance and the ligaments which enclose the joint were very loose³. This variation may contribute to the dislocation of the joint.

CTJ dislocation may manifest with airway or alimentary symptoms such as dyspnea or dysphagia. Mild form of dyspnea may not be appreciated but this can be pronounced during phonation. Thus assessment of phonation is taken as one of the effective measure to determine the adequacy of the glottis adducting and abducting abilities. Objective measurement such as maximum phonation time (MPT) can be relied on before deciding the need of further therapeutic options. Although free conversation voice sample or rough estimation of 10 words (counting up 1 to 10) are often used in the assessment, the more objective MPT usually require the patient to phonate stable vowels such as /a/ as long as possible using habitual vocal pitch and loudness. In a study involving 90 Iranian samples (45 males and 45 females), the

MPT was 26 seconds and female was significantly lower than male⁴.

Treatment of CTJ dislocation includes postural (encourage good posture-head and neck in relax position), relaxation (create awareness of tension, increase smooth muscle coordination and efficient use of muscular energy), breathing exercise and soft neck collar. Surgery is the other option if conservative techniques failed.

Due to its complex anatomy, surgery to the CTJ is not without potential complications. Even a simple procedure nearby the joint, such as cricothyroidotomy has been reported to trigger neo-ossification within the joint which lead to voice changes⁵. Breaching the capsule of the joint or manipulating the joint may induce further ankylosing of the CTJ. Impairment to the elevation of the larynx may also worsen the patient's dysphagia.

CONCLUSION

Although it is rare, laryngeal joint dislocation does occur. Education on proper posture, relaxation and breathing technique and avoiding odd positioning of the neck is essential if conservative management is opted. Fixed dislocation can be reduced under general anaesthesia.

REFERENCES

1. Jackson C, Jackson CL. "The larynx and its Diseases" p.100. WB Saunders Co, Philadelphia, 1937. (Secondary reference)
2. Knight JS. Cricothyroid dislocation. *Laryngoscope* 1960; 70(9): 1256-67.
3. Windisch G, Hammer GP, Prodinger PM, Friedrich G, Anderhuber F. The functional anatomy of the cricothyroid joint. *Surg Radiol Anat* 2010; 32: 135-9.
4. Dehqan A, Ansari H, Bakhtiar M. Objective voice analysis of Iranian speakers with normal voices. *J Voice* 2010; 24(2): 161-7.
5. Chang CY, Thomas JP. Neo-ossification of the cricothyroid joint after elective cricothyroidotomy: a case report and discussion on the merits of this procedure. *J Trauma* 2008; 65(5): 1146-50.