

# Endonasal Endoscopic Transsphenoidal Pituitary Surgery for Pituitary Adenoma: A retrospective Analysis Of Surgical Outcome

Mohd Sazafi Mohd Saad, MD, Balwant Singh Gendeh, MS ORL-HNS, Salina Husain, MS ORL-HNS

UKM Medical Center, ORL-HNS, Jalan Yaacob Latif, Bandar Tun Razak, Cheras, Kuala Lumpur, 56000, Malaysia

## SUMMARY

The purpose of this retrospective joint rhino-neurosurgical study from January 1998 until September 2009 is to document the demographic data, clinical presentations, radiological findings, approaches and incidence of residual tumour. Forty-seven patients with pituitary adenoma underwent trans-sphenoidal hypophysectomy of which 25 patients with complete medical and radiological data were included in the study. The medical and radiological data were analyzed. There were 12 males and 13 females with age ranging from 17 to 76 years old (mean 49.2). Fourteen of the patients were Chinese, eight Malays and three Indians. Twelve of the patients had functioning tumour of which five each presented with acromegaly and Cushing disease respectively and two with amenorrhoea. The rest of 13 patients had non functioning tumour presenting with visual disturbances. Sixteen of the patients had pituitary macroadenomas and the rest 9 microadenomas. Eighteen patients had undergone transcolumellar trans-sphenoidal hypophysectomy and the rest 7 patients had undergone transnasal transsphenoidal hypophysectomy. About 68.8% of pituitary macroadenomas had residual tumour, compared to only 22.2% of patient with pituitary microadenomas. Radiologically, about 45.5% of residual macroadenoma had suprasellar extension and the majority had spread to suprasellar cistern and carvenous sinus (54.5%). About 16.6% of patients had undergone post operative radiotherapy. In conclusion, this study showed that patient with pituitary macroadenomas had higher incidence of residual tumour compared to pituitary microadenomas

## KEY WORDS:

*Hypophysectomy; Transcolumellar, Endonasal endoscopic; Pituitary adenoma, Macroadenoma, Microadenoma, Residual tumour*

## INTRODUCTION

Pituitary adenomas account for about 10% of intracranial neoplasms<sup>1</sup>. They often remain undiagnosed, and small pituitary tumors have an estimated prevalence of 16.7%<sup>1</sup>. The diagnosis is generally entertained either on the basis of visual impairment arising from the compression of the optic nerve by the tumour, or on the basis of manifestations of excess hormone secretion, the specifics depend on the type of hormone.

Pituitary adenomas can be differentiated by measuring the size of the tumour. The radiological classification of pituitary adenomas is listed on Table I. Pituitary macroadenomas are defined as intrasellar adenomas of less than 1 cm in diameter without sellar enlargement whereas pituitary macroadenomas measure larger than 1 cm in diameter with generalized sellar enlargement and may cause symptoms of mass effect.

Initially the endoscopic transeptal approach was the principal method in pituitary surgery which provides a straight and quick access to the sella turcica which can be achieved by four techniques namely sublabial transeptal approach, endonasal transeptal approach, transcolumellar approach and lately by the direct transsphenoidal approach<sup>6</sup>. The sublabial approach was the common technique in the late 1960s which was often complicated by numbness of the upper lip and teeth, septal perforation and crust formation<sup>7,8</sup>. In view of these problems, surgeons have been seeking an alternative approach.

The endonasal transeptal approach gives good exposure and straight access to the sphenoid, avoiding the access through the oral cavity<sup>9</sup>. It is associated with shorter operative time and hospitalization<sup>10</sup>. However, this method requires relatively large nose to allow the placement of both endoscope and surgical instruments at the same time<sup>11</sup>, which make this method less suitable in oriental races that have small nostrils. This approach is more suitable in Caucasian and Indian races.

The refined transcolumellar approach was first suggested by McCurdy and colleagues in 1978<sup>12</sup>, and allows midline access in patients with narrow external nares. The disadvantages of this approach are an external incision which may result in a columellar scar and deformity in approximately 2% of patients and post operative nasal tip oedema which can persist up to 3 months in thick skin patients<sup>6,13</sup>.

Currently, direct endoscopic endonasal transsphenoidal hypophysectomy is considered the technique of choice when pituitary surgery is indicated and is useful approach in overcoming the post operative complications. The advantages of this approach is that it does not utilize a nasal speculum, gives a clearer panoramic view, allow more complete removal and does not require post operative nasal packing.

This article was accepted: 18 September 2011

Corresponding Author: Balwant Singh Gendeh, UKM Medical Center, ORL-HNS, Jalan Yaacob Latif, Bandar Tun Razak, Cheras, Kuala Lumpur, 56000 Malaysia Email: bsgendeh@gmail.com

The mortality rate related to pituitary tumours is low. Morbidity related to pituitary macroadenomas is associated with suprasellar expansion of the tumour into the optic chiasm and the cranial nerves adjacent to the cavernous sinus and may include permanent visual loss, ophthalmoplegia, and other neurological complications. Partial or complete engulfment of the carotid may occur in macroadenoma due to lateral extension. The grading scheme for suprasellar extension is listed on Table II. For pituitary microadenomas, the cure rate is greater than 50% on complete excision<sup>2</sup>. Tumour larger than 1 cm has higher residual tendency and may require additional treatment such as radiotherapy or radiosurgery. Reports of the incidence of postoperative CSF leak in the literature range from 1.5% to 4.2%<sup>3</sup>. The incidence of CSF leak was 50% higher with macroadenoma surgery.

#### *Pituitary Surgery*

The endonasal endoscopic transsphenoidal approach is the quickest direct route to the sella turcica and is useful in overcoming the complications of sublabial, endonasal transseptal and transcolumellar approach. The two nostril and four hand technique was first advocated by Prof Heinz Stammberger Graz, Austria for endoscopic cranial base surgery.

The pure endoscopic transsphenoidal approach involves identifying the sphenoid ostium in the spheno-ethmoidal recess. Initially a transoral bilateral greater palatine infiltration along with the septum is performed with ropivacaine and adrenaline (1:100,000). The sphenoid ostium is enlarged inferomedially with Kerrison punch forceps initially and subsequently enlarged maximally in all directions. Once the vital structures in the lateral wall of sphenoid sinus are identified, a subectomy (removal of posterior nasal septum) along with sphenoid rostrum is performed to enhance bilateral exposure. In addition, the intersinus septum and the sphenoid air cells exenterated. An incision is made over the mid-portion of the mucosa of the sella turcica and the mucosa elevated and the bone removed for adequate exposure. The sella dura is incised and the pituitary adenoma removed by bilateral application of suction by the neuro surgeon.

#### **MATERIALS AND METHODS**

This retrospective study reviewed the clinical records of patients who were diagnosed to have pituitary adenomas from January 1998 until September 2009 at the Universiti Kebangsaan Malaysia Medical Centre (UKMMC). The patient's demographic data, clinical presentations, radiological findings, approaches and recurrence rates of the tumour were analysed. Forty seven patients with pituitary adenoma underwent transsphenoidal of which 25 patients with adequate data were included in the study. Twenty two patients were excluded from the study due to unavailability of medical record. All patients underwent either preoperative magnetic resonance imaging (MRI) or computer tomography (CT) scans, and endocrinology, neurosurgical and ophthalmological evaluations. The MRI that has been used is Siemens Avanto 1.5T manufactured in Germany, using pituitary protocol to measure the pituitary size pre and post operatively. All the operations were a combined otorhinological and neurosurgical team effort.

#### **RESULTS**

There were twelve males and thirteen females in this series. The age ranging from 17 to 76 years (mean of 49.2 years). Ten were Chinese, 7 were Malays and 3 were Indians. Sixteen patients had pituitary macroadenoma and 9 had pituitary microadenoma. Twelve cases had functioning tumour in this series. The majority of the patients presented with visual disturbances, followed by acromegaly, Cushing disease and amenorrhoea. (Figure 1).

Ten of the patients had bitemporal visual field loss, one patient had colour desaturation and diplopia and 2 patients had ophthalmoplegia. Post operatively, the vision improved in 9 patients, and in the rest remained the same. In term of hormonal changes pre and post operatively, the hormones level normalized in 7 patients post operatively.

Out of 13 referral cases of pituitary macroadenomas, three of them had residual tumour and the rest were newly diagnosed at the time of presentation. In the 3 cases of residual pituitary macroadenomas, one patient had undergone transsphenoidal surgery via endonasal transseptal approach and 2 cases via sublabial approach. About 68.8% of pituitary macroadenomas had residual tumour, while only 22.2% of patient with pituitary microadenomas developed residual tumour (Figure 2).

Eighteen of the patients had undergone transcolumellar transsphenoidal hypophysectomy and 7 patients had undergone transnasal transsphenoidal hypophysectomy. Radiologically, the majority (54.5%) of residual macroadenoma had spread to both suprasellar cistern and cavernous sinus and the rest (45.5%) had suprasellar extension only.

In our series, only 4% of the patient developed CSF leak. Other complication such as diabetes insipidus was noted in 8 patients in this series (32%).

#### **DISCUSSION**

In general, pituitary adenomas are diagnosed more frequently in women than in men probably because of the association of these tumours with menstrual irregularities<sup>14</sup> which correlates with our study. This study also showed that Chinese have the highest proportion of pituitary adenomas followed by Malay and Indian. The incidence of pituitary adenoma increases with age, peaking between the third and sixth decades<sup>14</sup>. In our series, the peak age is at sixth decades accounting for 9 patients.

Pituitary adenoma can be divided into functioning and non functioning tumours, or according to size namely microadenomas or macroadenomas. Functioning pituitary adenomas can be clinically classified by means of the hormone they secrete. These tumours become symptomatic because they secrete hormones such as growth hormone, adrenocorticotropic hormone (ACTH) and prolactin. The endocrine classification of pituitary adenomas is listed in Table III.

The incidence of residual tumour is higher in pituitary macroadenoma. This is probably due to size and extension of tumour to surrounding structures namely suprasellar extension to optic chiasm and lateral extension to engulf the

**Table I: The radiological classification for pituitary adenomas**

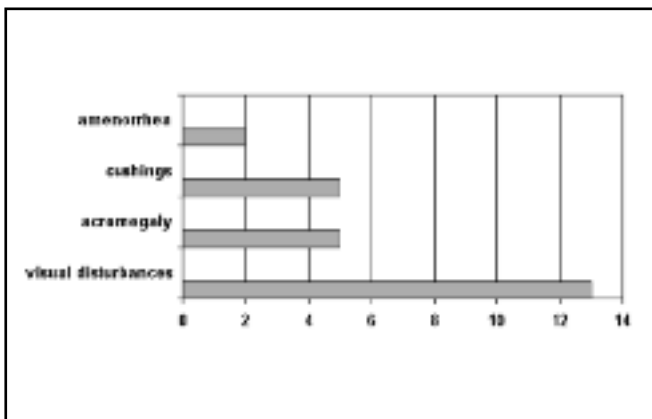
- 0 : Normal pituitary appearance
- I : enclosed within the sella turtica, microadenoma, smaller than 10 mm
- II : enclosed within the sella tursica, macro adenoma, 10 mm or larger
- III: invasive, locally, into the sella
- IV: invasive, diffusely, into the sella

**Table II: The grading scheme for suprasellar extensions**

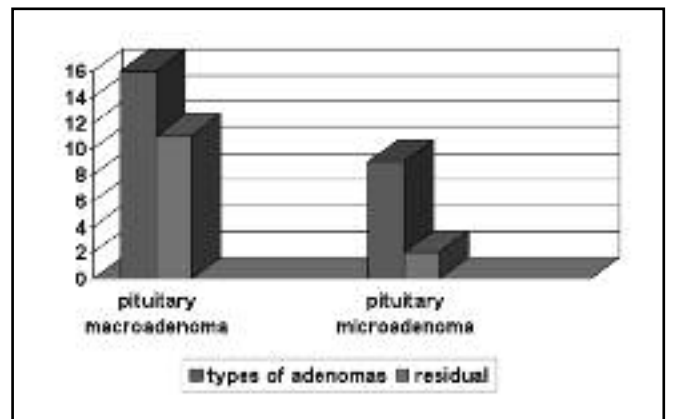
- 1: 0 to 10 mm suprasellar extension occupying the suprasellar cistern
- 2: 10 mm to 20 mm extension and elevation of the third ventricle
- 3: 20 to 30 mm extension occupying the anterior of the third ventricle
- 4: A larger than 30 mm extension, beyond the foramen of Monroe, or Grade C with lateral extension

**Table III:Appreciation of PBL in relation to e-learning resources**

Name	Prevalence (% of all tumors)	Hormone staining	Clinical manifestation
Prolactinomas (Prolactin-secreting)	40-45	prolactin	Signs of hyperprolactinemia
Somatotroph adenomas (GH-secreting)	20	GH ±prolactin	Acromegaly
Corticotroph adenomas (ACTH-secreting)	10-12	ACTH ±others	Hypocortisolism
Gonadotroph adenomas	15	FSH, LH, aSU, bSU	Mechanical symptoms, hypopituitarism
Null-cell adenomas	5-10	None	Mechanical symptoms, hypopituitarism
Thyrotroph adenomas (TSH-secreting)	1-2	TSH, aSU± GH	Mild hyperthyroidism, hypopituitarism



**Fig. 1:** Presenting symptoms of pituitary adenoma.



**Fig. 2:** Type of pituitary adenomas and their incidence of residual tumour.

internal carotid artery. Twenty eight percent of pituitary macroadenomas can extend into the cavernous sinus as reported in the literature<sup>2</sup>. Complete removal in macroadenoma may be difficult without adequate decompression. Out of 13 cases of residual tumours, majority of them had extension either to suprasellar, cavernous sinus or engulfing the carotids.

Use of the endoscope for pituitary tumour resection represents significant advancement in pituitary surgery. Endoscope provide a wide-angled panoramic view with zooming capability compared to conventional microscopic

techniques which only provides a magnified view of sella through a narrow corridor. Wide-angled panoramic view is useful for pituitary tumour surgery because it allows excellent anatomic visualization at the posterior wall of the sphenoidal sinus<sup>15</sup>. While, angled-lens views such as 30, 45 and 70 degree endoscopes allow direct visualization at the suprasellar region or various anatomic corners<sup>15</sup>. Endoscopic techniques have greater advantages for removal of pituitary macroadenoma extending to the suprasellar region or invading into the cavernous sinus or engulfing the carotids, thus reducing the incidence of residual tumour.

Studies have shown that pure endoscopic endonasal transsphenoidal hypophysectomy is preferred and useful in overcoming the complications encountered by the transseptal approach<sup>13</sup>. However, only 7 patients had direct endoscopic endonasal transsphenoidal hypophysectomy compared to transseptal approach at our referral teaching hospital. It took some time to convince our neurosurgical colleagues on the advantages of endoscope compared to the microscope in pituitary surgery.

There is also a greater risk of an intraoperative complications such as CSF leak with pituitary macroadenomas, especially if there is significant extrasellar extension<sup>16,17</sup>. CSF fistula repair can be performed by sandwich technique, namely duragen as underlay fascial graft and nasoseptal flap as onlay graft. However in our series there was only one case of pituitary microadenoma (4%) that developed CSF leak following pure transnasal transsphenoidal surgery. Post operatively a lumbar drain was inserted.

### CONCLUSION

In conclusion, this study showed that patient with pituitary macroadenomas had higher rates of residual tumour compared to pituitary microadenomas. This is most likely due to difficulties encountered in complete tumour removal more so with suprasellar extension involving optic chiasm and lateral extension engulfing the carotid artery and carvenous sinus. Pure endonasal endoscopic assisted transsphenoidal hypopysectomy provides an excellent and rapid access to the sphenoid sinus and sella turcica, and is becoming the procedure of choice at UKMMC of late.

### REFERENCES

1. Ezzat S, Asa SL, Couldwell WT, Barr CE, Dodge WE, Vance ML *et al.*. The prevalence of pituitary adenomas: a systematic review. *Cancer* 2004; 101(3): 613-9.
2. Gsponer J, De Tribolet N, Déruaz JP *et al.* Diagnosis, treatment, and outcome of pituitary tumors and other abnormal intrasellar masses. Retrospective analysis of 353 patients. *Medicine (Baltimore)* 1999; 78(4): 236-69.
3. Sudhakar N, Ray A, Vafidis JA. Complications after trans-sphenoidal surgery: Our experience and a review of literature. *British Journal of Neurosurgery* 2004; 18: 507-12.
4. Collins WF. Hypophysectomy: Historical and personal perspective. *Clin Neurosurg* 1973; 34: 582-92.
5. Hardy J. Transsphenoidal hypophysectomy. *J neuro* 1971; 34: 582-92.
6. Gendeh BS, Sakina MS, Selladurai BM, Jegan T, Misiran K. The transcolumellar transsphenoidal approach to pituitary tumours: Advantages and Limitations. *Med J. Malaysia* 2006; 61(3): 349-54.
7. Sharma K, Tyagi I, Banarjee D. Rhinological complications of sublabial transseptal transsphenoidal surgery for sellar and suprasellar lesions: Prevention and management. *Neurosurgery Review* 1996; 19: 163-7.
8. Mallina S, Harvinder S, Rosalind S, Philip R, Gurdeep S. Endoscopic assisted transseptal transphenoidal hypophysectomy. *Med J Malaysia* 2006; 61(3): 320-2.
9. Wilson WR, Khan A, Laws ER. Transseptal approaches for pituitary surgery. *Laryngoscope* 1990; 100: 817-9.
10. Gendeh BS, Selladurai BM, Selvapragasam T, Kalid KA, Said H. The Transseptal Approaches to Pituitary Tumours: Technique, Rhinologic Functions and complications. *Asian Journal of Surgery* 1998; 219(4): 259-265.
11. Kim SH, Yoon JH, Choi JU, Chung SS, Lee KC. Transcolumellar approach in transsphenoidal pituitary surgery for patients with small nostril. *Otolaryngology-head and neck surgery* 2001; 125(6): 609-12.
12. McCurdy JA, VanSant TE, Yim DWS. Transseptal transphenoidal hypophysectomy via external rhinoplasty approach. *Journal of otolaryngology* 1978; 7: 29-31.
13. Gendeh BS, Doi M, Selladurai BM, Khalid BAK, Jegan T and Misiran K. The role of endoscopic endonasal approach to pituitary tumour: HUKM experience. *Med. J Malaysia* 2006; 61(3): 343-84.
14. Ali NK, Ian T, Velauthan R, Alberto A, Anita J, Saravanan M *et al.* Pituitary adenoma. Overview, imaging, follow up and multimedia. *E-medicine* 2005
15. Hae-Dong, David H. Use of Endoscopic Techniques for Pituitary Adenoma Resection. *The endocrinologist* 2004; 14(2): 76-86.
16. Gendeh BS, Mazita A, Selladurai BM, Jegan T, Jeevanan J and Misiran K. Endoscopic repair of anterior skull base fistula: The Kuala Lumpur Experience. *J. Laryngol Otol* 2005; 119: 866-74 .
17. Gendeh BS, Wormald PJ, Forer M, Goh BS, Misiran K. Endoscopic repair of spontaneous cerebro-spinal fluid rhinorrhoea: A review of 3 cases. *Med J. Malaysia* 2002; 57(4): 503-8.