

# Diffuse Peritoneal Lymphomatosis Simulating Peritoneal Carcinomatosis

M I A Sharifah, MMED (Radiology)\*, N A Z Zamzami, MMED (Radiology)\*, T Nor Rafeah, MMED (Medical)\*\*

\*Department of Radiology, Faculty of Medicine. Unversiti Kebangsaan Malaysia Medical Centre, Kuala Lumpur, \*\*Hematology Unit, Department of Medicine. Faculty of Medicine. Universiti Kebangsaan Malaysia Medical Centre, Kuala Lumpur

### SUMMARY

Burkitt's lymphoma is a form of Non-Hodgkin's B-cell lymphoma. We report a case of Burkitt's lymphoma mimicking peritoneal carcinomatosis. We will discuss the imaging and clinical findings that differentiate between peritoneal carcinomatosis and Burkitt's lymphoma. A 26-year-old man presented with nonspecific abdominal pain, vomiting and diarrhea associated with significant amount of loss of weight. Computed tomography images showed extensive peritoneal and mesenteric mass associated generalized lymphadenopathy. Core biopsy of the mass confirmed Burkitt's lymphoma. CT scan features are helpful indicator to differentiate Burkitt's lymphoma and peritoneal carcinomatosis. Focal or diffuse nodular thickening of the bowel wall with extensive lymphadenopathy are likely to be lymphomatosis over carcinomatosis. However, final and confirmatory diagnosis is histopathology examination.

### KEY WORDS:

*Burkitt's lymphoma, Peritoneal carcinomatosis, Non-Hodgkin lymphoma.*

### INTRODUCTION

Burkitt's lymphoma (BL) was first described by Denis Burkitt in 1958<sup>1</sup>. It is a highly aggressive non-Hodgkin lymphoma with a doubling time of 24 hours. Adult patients with sporadic Burkitt's lymphoma often present with extranodal disease, and the abdomen is the most frequent site of involvement<sup>1</sup>.

### CASE REPORT

A 26-year-old man who was previously healthy presented with three weeks history of generalized abdominal pain, associated with post prandial vomiting. He also had diarrhea for the past three months. His symptoms continued to progress and he had lost 15 kg in three weeks. There was no family history of malignancy.

On examination, his vital sign was stable. The abdomen was mildly distended and tender, however there was no guarding. Respiratory examination revealed there was reduce breath sound on the right side of the lung. The rest of the physical examinations were unremarkable.

Chest radiograph showed right pleural effusion. No obvious mass seen. Abdominal ultrasound revealed extra-vesical

irregular mass indenting onto the urinary bladder and thickened bowel wall predominantly at the right iliac fossa. Colonoscopy demonstrated external compression anterior to the caecum with smooth and regular mucosal surface (Figure 1).

Contrast enhanced computed tomography of the abdomen revealed extensive peritoneal and mesenteric mass with involvement of the small and large bowel. These enhancing peritoneal mass was seen continuous with the mass located postero-superior to the bladder and prostate (Figure 2 & 3).

There was associated lymphadenopathy of para-aortic, retrocava, inguinal, paratracheal, anterior mediastinal, posterior cervical, left supraclavicular and right axillary lymph nodes. There was also presence of moderate amount of ascites and right pleural effusion.

Lactate Dehydrogenase (LDH) and uric acid were markedly raised. LDH was 3409 U/L (211-423) and Uric acid was 510 umol/L (149-450). Tumour markers were moderately raised. Ca 19.9 was 260 (normal value 46 U/ml) and CEA was 269 (normal value 0.9 n/ml). Eipstein Barr virus (EBV) status was positive. However retroviral screening was negative. Differential diagnoses were peritoneal carcinomatosis, lymphoma and peritoneal tuberculosis.

Core biopsy of the lymph nodes, caecal mass and bladder tissue confirmed Burkitt's lymphoma. He was started on CD 20 monoclonal antibody (Rituximab) and chemotherapy. Unfortunately, his condition got worse. He developed sepsis and acute tumor lysis syndrome causing acute renal failure. Patient succumbed to his illness due to sepsis and respiratory failure.

### DISCUSSION

In the World Health Organization (WHO) Classification, three clinical variants of Burkitt's lymphoma are described: endemic, sporadic, and immunodeficiency-associated type. Epstein Barr Virus (EBV) is found in nearly all cases and our patient is positive for EBV<sup>1</sup>.

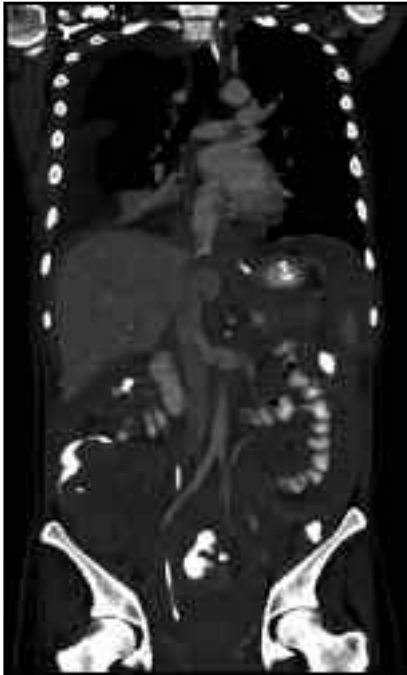
Sporadic Burkitt's lymphoma occurs worldwide. It includes those cases occurring with no specific geographic or climatic association<sup>1</sup>. It accounts for 1–2% of lymphoma in adults and up to 40% of lymphoma in children<sup>2</sup>. The abdomen, especially the ileocecal area, is the most common site of

This article was accepted: 27 July 2011

Corresponding Author: Sharifah Majedah Idrus Alhabshi, UKM Medical Centre, Radiology, Jalan Ya'akob Latif, Bandar Tun Razak, Cheras, 56000 Kuala Lumpur, Malaysia Email: shmajedah@yahoo.com



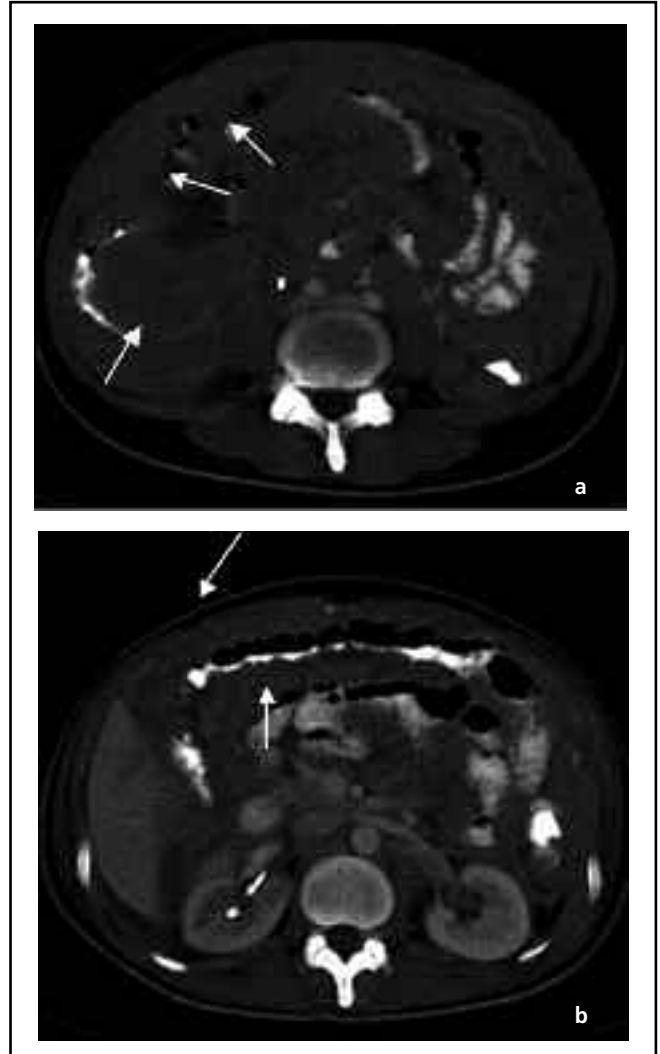
**Fig. 1:** Colonoscopy image shows external compression onto caecum with regular and smooth mucosa of the caecum (black arrow).



**Fig. 3:** Coronal images of the computed tomography of the abdomen demonstrate extensive peritoneal mass and bowel wall thickening involving both small and large bowel with right pleural effusion.

involvement. The ovaries, kidneys, omentum, Waldeyer's ring and other sites may also be involved. Lymph node involvement is more common among adults than among children<sup>2</sup>. Patients may also have malignant pleural effusion or ascites<sup>2</sup>.

Undifferentiated Non Hodgkin Lymphoma (NHL) is usually derived from B cells and is divided into non-Burkitt and Burkitt lymphoma. The primary site of undifferentiated NHL



**Fig. 2a & b:** Contrast enhanced Computed Tomography of abdomen with oral and rectal contrast shows extensive and diffusely infiltrating peritoneal mass with thickened peritoneum lining encasing the small and large bowel. This lining folds of the mesentery causing extensive bowel wall thickening predominantly caecum (white arrow).

is the abdomen. Clinically, these patients often present with abdominal pain, mass, vomiting or symptoms suggestive of intussusception or appendicitis. Other common intraabdominal sites include the ovaries; retroperitoneum; and mesenteric, inguinal, or iliac lymph nodes<sup>3</sup>.

At diagnosis, our patient had bulky mass and elevated uric acid and lactate dehydrogenase due to rapid growth of the tumor. These manifested significant metabolic derangement and subsequent renal function impairment<sup>4</sup>.

Differential diagnoses in this patient include peritoneal carcinomatosis, lymphoma, and mesenteric panniculitis. Peritoneal carcinomatosis was considered as the first differential diagnosis because it is the most common peritoneal solid mass resulting from gastrointestinal

malignancy which usually associated with omental caking and ascites which were present in this patient. Lymphoma was also considered as second differential diagnosis because there was mesenteric as well as peritoneal mass associated with generalized lymphadenopathy.

Extensive infiltration of the peritoneum secondary to lymphomas is rare occurrences. The diagnosis of this presentation may be a challenging condition for radiologists since many other primary and secondary peritoneal malignancies have similar imaging findings. Smooth or nodular peritoneal involvement, enhancing mass with no symptoms of bowel obstruction, presence of non-loculated and non-septated ascites, conglomerate lymphadenopathies and solid organ involvement particularly in the splenic and hepatic parenchyma are features to suggest lymphomas<sup>5</sup>.

Peritoneal lymphomatosis is characterized by diffusely thickened peritoneal surfaces with multifocal nodules and masses that mimic peritoneal carcinomatosis. Other CT features of peritoneal carcinomatosis include ascites, peritoneal enhancement and thickening, omental caking and infiltration of the small bowel mesentery. The presence of extensive lymph adenopathy in lymph node chains typically involved with lymphoma, exclusively those in the retrocrural region and small bowel mesentery. These may suggest lymphomatosis over carcinomatosis<sup>5</sup>. Although lymph node enlargement and nodular peritoneal thickening may occur, ascites is the most predominant manifestation of end-stage disease of lymphoma<sup>5</sup>.

Other common CT scan findings of Burkitt's lymphoma include a thickened bowel wall, which is sometimes nodular and either diffuse or focal, with discrete mesenteric lymph node masses. It is often possible to see a thickened but otherwise preserved pattern of valvulae conniventes at one or the other margin of the infiltrated segment. Unlike primary adenocarcinoma and metastatic disease, extensive lymphomatous encasement of the bowel may occur without significant narrowing<sup>1</sup>.

Omental involvement in the course of lymphomas in comparison to carcinomatosis although can occur but uncommon. This is because the omentum does not contain lymphoid tissue and therefore, the route of this dissemination is not clear. In case of intestinal lymphomas the presumed way of dissemination is believed to be, like the omental metastasis secondary to gastrointestinal carcinomas, via the pathways like gastrocolic ligament, transverse mesocolon and visceral peritoneal surfaces.

Due to the high growth rate of Burkitt's lymphoma, standard treatment employs short-duration, intensive, combination chemotherapy. In adult, complete response rates of 65%-100% and overall survival rates of 50%-70% have been reported Although the most important prognostic features with adverse outcome in adults and children include older age, advanced stage, poor performance status, bulky disease, high LDH, and CNS or marrow involvement<sup>2</sup>.

A good response and a favorable outcome have been associated with localized disease in cases of sporadic Burkitt's lymphoma, however due to advance stage of disease with underlying sepsis and respiratory failure; our patient succumbed to his illness.

**REFERENCES**

1. T Shital, SM Anand, J Punam. Case report: Pediatric duodenum Burkitt's Lymphoma. Indian J Radio Imaging 2007; 17: 4.
2. MM Khaled, TT Ali & IS Ali I .Burkitt's lymphoma of the colon and bronchi: three case reports. Cases Journal 2008; 1: 15.
3. HT Jennifer, IP Cynthia, IB Bernard, AR Stuart, V Rathi. Imaging of Childhood Non-Hodgkin Lymphoma Assessment by Histologic Subtype. Radiographics 1994; 14: 11-28.
4. M McMaster, J Greer, A Greco, D Johnson, S Wolff, J Hainsworth. Effective treatment of small-non-cleaved-cell lymphoma with high-intensity, brief-duration chemotherapy. J Clin Oncol 1991; 9: 941-6.
5. DL Angela, CS Janet, HS McLeslie .Secondary Tumors and Tumor like Lesions of the Peritoneal Cavity: Imaging Features with Pathologic Correlation. RadioGraphics 2009; 29: 347-73.