

An Unusual Presentation of Lymphoma of The Head and Neck Region

C S L L Teh, MORL-HNS (UM), S Y C Chong, MORL-HNS (UM)

Dept of ORL, Hospital Sungai Buloh, Jalan Hospital, 47000 Sungai Buloh, Selangor

SUMMARY

A 33-year-old Malay lady presented to us with 1-month history of globus sensation in the throat. Clinically, she had a 3cmx2cmx1cm sessile soft mass arising from the right tongue base and was treated as hypertrophied lingual tonsil. Biopsy of the mass was done when the patient developed bleeding and was reported as diffuse non-Hodgkin's B-cell lymphoma. Globus sensation is a common complaint in the ORL clinic. It is important to be able to decide if further investigation is warranted to differentiate a malignant from a benign lesion as at times, a malignant lesion can masquerade as a harmless lesion.

KEY WORDS:

Base of tongue; lymphoma

INTRODUCTION

Lymphomas are usually tumours of the lymph nodes but 24 to 84% of Non-Hodgkin's lymphomas (NHL) are extranodal¹. While extranodal lymphoma is most commonly seen in the gastrointestinal tract, it is followed by the head and neck region with an incidence of about 10%^{2,3}.

HISTORY

We present a 33 year-old Malay lady who was seen in our Otorhinolaryngology Clinic with a swelling at the right base of tongue for a period of one month. She had felt it upon swallowing. The attending doctor had examined her and found a 1cmx1cm soft mass with smooth healthy-looking mucosa arising from the base of tongue and reassured her that it was most likely hypertrophied lingual tonsil. She was given a follow-up appointment to monitor her condition.

The patient then returned in a week to the ORL outpatient clinic and this time she complained of bleeding from the mass. She had felt that the mass had increased in size and admitted to palpating the mass.

On further questioning, she did not experience any pain, fever, night sweats, other bleeding tendencies, easy bruising or any recent infections. She did however lose 5 kg in the previous three months.

The patient had no known medical illnesses or allergies. She did not smoke, chew betel quid nor consume alcohol. She had no family history of malignancies.

On examination, a sessile mass measuring 3cmx2cmx1cm arising from the right base of tongue was seen with mouth opening but made more prominent upon protrusion of the tongue (Figure 1). There was a shallow ulcer measuring 0.5cm x 0.5cm with a sloughed base. There was no obvious bleeding at the point of examination. Tongue mobility was also not compromised.

The oral cavity appeared normal with bilateral grade 3 healthy looking tonsils. A flexible nasopharyngolaryngoscopy revealed a normal nasopharynx and oropharynx. Examination of the larynx showed the right base of tongue mass which had a well-defined margin and appeared free from the epiglottis but was abutting onto it due to the size of the mass. The larynx was otherwise normal.

Examination of the ear, nose, neck and other systems were normal and she did not have any enlarged lymph nodes or hepatosplenomegaly.

A biopsy of the mass was taken and sent for histopathology. A tissue diagnosis of diffuse high-grade, large-cell type B-cell NHL, was made. (Figure 2) The patient was referred to the Hematology team.

Bone marrow aspiration and bone marrow trephine examination were normal. Blood investigations were also normal and serology testing revealed that the patient was not immunocompromised.

Computed tomography (CT) scan of the brain, neck, thorax, abdomen and pelvis was carried out to stage the disease. Bilateral small cervical lymph nodes were seen. The largest on the right side measured 0.6cmx0.5cm and on the left side measured 1.7cmx0.5cm. There was a soft tissue mass at the tongue base which had pushed the epiglottis posteriorly but visible tongue muscles enhanced normally. The lung, liver, spleen, pancreas and both kidneys and adrenal appeared normal. There was no mediastinal, abdominal or pelvic lymphadenopathy.

The patient with a staging of IIE NHL, was treated with R-CHOP (rituximab, cyclophosphamide, hydroxydaunorubicin (Adriamycin), Oncovin (vincristine), and prednisolone). She is currently in remission.

This article was accepted: 20 July 2011

Corresponding Author: Carren Teh, Dept of ORL, Hospital Sungai Buloh, Jalan Hospital, 47000 Sungai Buloh, Selangor

Email: carren_teh@hotmail.com

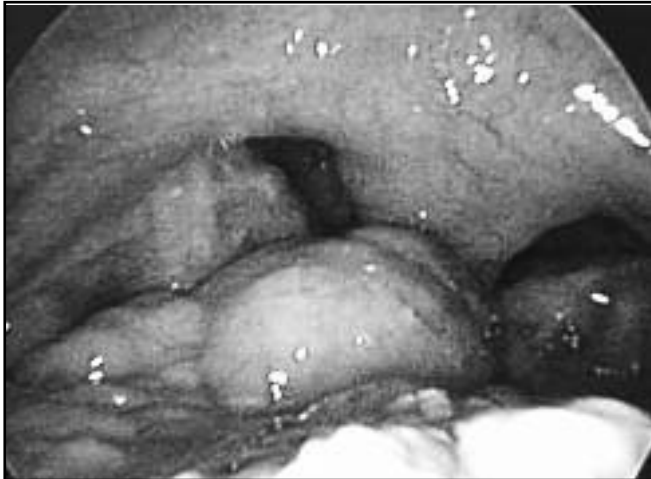

Fig. 1: The sessile mass seen on protrusion of the tongue, flanked by the grade 3 tonsils.

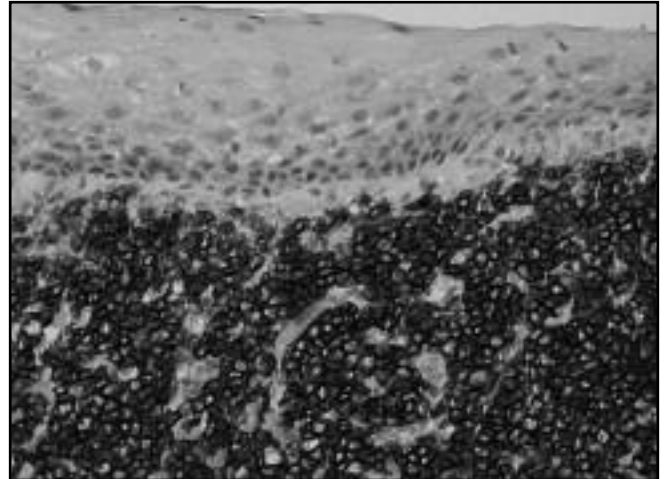


Fig. 2: Non Hodgkin lymphoma, diffuse, large cell, B cell type. (Final magnification = 100x) Photographs taken: H& E stain and CD 20 stained. Surface stratified squamous epithelium of base of tongue seen with clear subepithelial area. Underlying tissue has diffuse infiltrate of large round noncohesive cells. The cells have pleomorphic vesicular nucleus and scanty cytoplasm. These cells are CD 20 positive.

DISCUSSION

Head and neck lymphomas differ from other lymphomas with its higher incidence of extranodal presentation and better prognosis¹. Waldeyer's ring, paranasal sinuses, nasal cavity, larynx, oral cavity, salivary glands, thyroid, and orbit are among the common sites for head and neck lymphomas³. Waldeyer's ring involvement as the primary site of NHL is approximately 5% to 10% of all lymphoma patients. Of all Waldeyer's ring NHLs, the tonsil is the most frequent site, followed by the nasopharynx³.

The tongue base itself is an extremely unusual localization for isolated primary NHL, and only sporadic cases have been published so far with an incidence of 5.2% to 7% of all head and neck lymphomas^{1,3}. Based on our own database dating back to 1998, out of 35 cases of Waldeyer ring lymphomas, this is the second case involving the base of tongue. This demonstrates its rarity. Unfortunately, the 5-year site-specific survival for these patients has been estimated to be 47% but it improves with early diagnosis².

However, early diagnosis is deterred by its harmless appearance which makes it easily mistaken for a hypertrophied lingual tonsil. Other benign neoplasms such as

fibroma, peripheral nerve sheath tumour, benign salivary gland tumour, leiomyoma, and rhabdomyoma and infective processes, such as histoplasmosis, tuberculosis, and syphilis could have been possible differentials³. Its deceptive appearance can only be unmasked with a simple biopsy. However, we do not recommend subjecting all patients with a base of tongue mass to the trauma of a biopsy but instead to be aware of the possibility of NHL.

CONCLUSION

A localized NHL of the tongue base with only the presenting symptom of globus sensation should be considered in the differential diagnosis of benign-looking base tongue lesions.

REFERENCES

1. Lee STS, Raman R, Jayalakshmi P. Non-Hodgkin's lymphoma of lingual tonsil—Case report. Singapore Med J 1987; 28(4): 363-5.
2. GK Maheswari, HA Baboo, NM Shah, MH Patel, R Shah. Primary non-Hodgkin's lymphoma of the oral tongue. Turkish Journal of Cancer 2001;31(3): 121-4.
3. HC Lin, TA Chang, KL Lin. Non-Hodgkin's Lymphoma Presented as a Tongue Base Tumor: A Case Report. Changhua J Med 2003; 8: 190-3.