

Perforation of Duodeno-jejunal Junction in an 8-month-old Infant: A Management Challenge to a General Surgeon

L Limi, MD*, A A Dayang Anita, BMedSc(UKM)**, MD(UKM), FRCS(Edinburgh UK), Fellow in Paediatric Laparoscopy (Adelaide Australia), N C Liew, FRCS*, M Safian N, FRCS***

*Department of Surgery, Faculty of Medicine and Health Sciences, University of Putra Malaysia, Level 10B, Grand Seasons Avenue, 72, Jalan Pahang, 53000 Kuala Lumpur, Malaysia, **UKM Medical Centre, Jalan Ya'acob Latif, Bandar Tun Razak, 56000 Cheras Kuala Lumpur, Malaysia, ***Department of Surgery, Hospital Melaka, Jalan Mufti Haji Khalil, 75400 Melaka

SUMMARY

We report a case of perforation over duodeno-jejunal junction (DJ) in a healthy 8-month-old baby. The difficulty in diagnosis, management dilemma and probable etiology is discussed.

KEY WORDS:

DJ perforation, Baby

INTRODUCTION

Duodenal, especially duodeno-jejunal junction (DJ) perforation in an infant is rare. Commonly, gastrointestinal perforation is seen as a result of trauma, infection, volvulus, adhesions, intussusception or strangulated hernia. The most common site of gastrointestinal perforation is the ileum followed by colon, stomach and oesophagus. Diagnosis of duodenal perforation in children poses a challenge particularly to general surgeons, as its presentation is subtle, especially in those without trauma. Delay in diagnosis and intervention increases the morbidity and mortality. We encountered an infant with DJ junction perforation, whom we had difficulty in diagnosis and management.

CASE REPORT

An eight-month-old male infant presented to a general hospital with one-day history of severe non-bilious vomiting and poor oral intake. There was no history of abdominal distension or fever. No history of trauma was reported. Pre-morbidly, he was an active infant, born full-term with no other significant medical or surgical conditions.

At presentation, he was lethargic, tachycardic and severely dehydrated. There were no signs of bruises or deformities on his body. His abdomen was mildly distended with vague signs of peritonitis. Abdominal plain radiograph revealed signs of pneumoperitoneum. Ultrasonography of abdomen showed an abscess collection at the right iliac fossa. Based on the imaging finding, a diagnosis of perforated viscus, likely perforated appendix was made. Subsequently, he underwent emergency exploratory laparotomy.

Intra-operatively, an anterior duodeno-jejunal (DJ) junction perforation measuring 2cm X 2cm, covered with a layer of slough was found. There was approximately 500ml of pus

with interloop slough (Figure 1). The appendix and the rest of the bowel were normal. In view of the severe contamination with inflamed proximal and distal part of the perforation, no attempt at primary repair was made. The perforated DJ junction was transected and the duodenal stump was closed, as it was too short to be brought out as a stoma. An 8F Foley catheter was inserted into the duodenal stump and brought out as a controlled fistula. The jejunum was exteriorized as a mucous fistula (Figure 2). Post-operatively, enteral feeding was withheld. Total parenteral nutrition (TPN) was started while the Foley catheter was on free flow.

Two days later, he was transferred to a paediatric surgery centre of a tertiary hospital. TPN was continued for a week and later substituted with enteral feeding via a tube into the mucous fistula. The output from the controlled fistula was also re-fed into the mucous fistula (mucous fistula refeeding), hence avoiding major electrolyte imbalances. Eight weeks after the initial surgery, he underwent relaparotomy. Adhesiolysis, trimming of the two transected parts of the gut and an end-to-end anastomosis between the distal duodenum and proximal jejunum were performed. The trimmed edges were sent for histopathological examination (HPE) which did not show any evidence of malignancy or infection. The tissue showed some foreign body granuloma, which could be secondary to the sutures used to close the duodenal stump. A possibility of other foreign bodies like tiny fish-bones etc causing perforation could not be discounted. The foreign bodies could have admixed with the pus and sucked out during the operation.

Subsequent post-operative recovery was uneventful, except wound infection which healed with daily dressing. Normal oral feeding was established within a week and the child had been followed up for one year. He had remained well and active with normal growth.

DISCUSSION

Duodenal perforation is rare in children, especially DJ junction perforation. First and second parts of duodenum are the common sites of perforation from ulcers. DJ perforation usually follows a history of blunt trauma to the upper abdomen. In a retrospective review by Gaines *et al*¹, 0.3% of children admitted for trauma had injuries to the duodenum and all children of duodenal injury younger than 4 years of

This article was accepted: 18 April 2011

Corresponding Author: Limi Lee, Department of Surgery, Faculty of Medicine and Health Sciences, University of Putra Malaysia, Level 10B, Grand Seasons Avenue, 72, Jalan Pahang, 53000 Kuala Lumpur, Malaysia Email: leelimi@yahoo.com

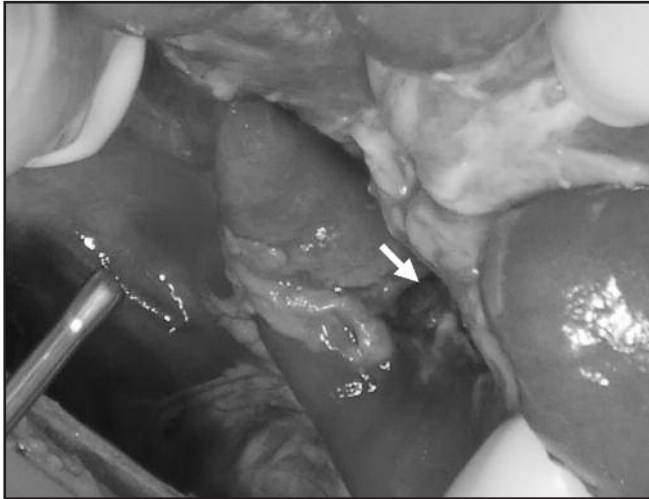


Fig. 1: Anterior DJ junction perforation covered with slough (Arrow shows Ligament of Treitz).

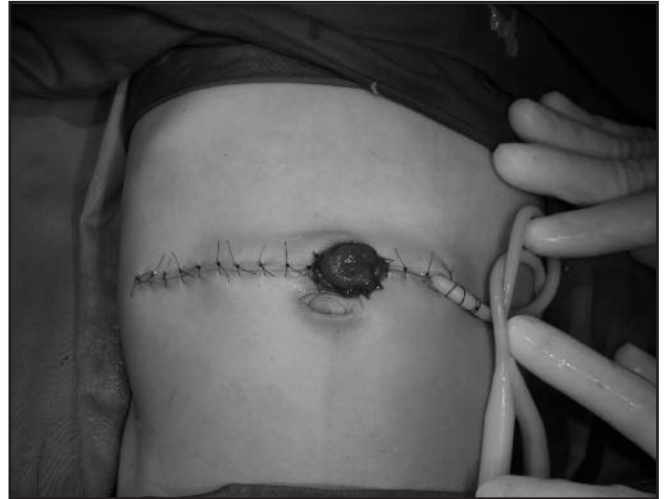

Fig. 2: The duodenal controlled fistula and distal mucous fistula.

age were victims of non-accidental trauma. Thus, non-accidental injuries should be suspected, especially when there were other signs of abuse, when an infant is diagnosed with duodenal perforation.

Diagnosis of duodenal perforation in infants is often delayed due to its vague clinical presentation². Most of them present with fever, vomiting, diarrhoea, poor oral intake and severe dehydration mimicking gastroenteritis.

Ultrasonography of the abdomen may show free fluid or collection in the peritoneal cavity but examination is hindered when there is gross bowel distension. Contrast enhanced Computed Tomography (CT) scan of the abdomen is the investigation of choice for diagnosing gastrointestinal perforation. However, it only has 100% positive predictive value for bowel perforation if extra-luminal air, free fluid, wall thickening, bowel wall enhancement and bowel dilatation are all present³.

Simple closure with or without omental patch were done for perforation at the first and second part of duodenum regardless of its cause in most of the case reports. A study by Clandenon et al on traumatic duodenal injuries in children recommended primary repairs in limited to moderately severe duodenal perforation and duodenal resection plus reconstruction for more severe irreparable injuries².

In this case of DJ junction perforation with severe intra-abdominal contamination due to late presentation, primary repair or resection and reconstruction was not feasible. Instead, an initial damage-control surgery with control of

sepsis and bowel content diversion followed by later bowel reconstruction had resulted in a good outcome. The method of re-establishing enteral feeds via mucous fistula re-feeding avoided adverse outcomes associated with a high output fistula like fluid and electrolyte imbalances.

Our initial suspicion of child abuse associated with DJ perforation was not supported by associated injuries to other parts of the body. There was no retroperitoneal haematoma or pancreatic haematoma to suggest the use of a blunt force. Ingestion of sharp foreign body, such as fishbone, causing perforation could not be discounted as this infant had a focal perforation without evidence of other bowel pathology. Unfortunately, no definite foreign body was isolated to confirm the diagnosis, as suggested by the HPE report of foreign body granuloma. Gastrointestinal infection, such as salmonella infection was unlikely the etiology of bowel perforation in this child as there were no preceding symptoms such as fever and diarrhoea, and the rest of the gut was unaffected. Thus, the cause of the DJ junction perforation in this patient has remained a mystery.

REFERENCES

1. Gaines B, Shultz B, Morrison K, Ford HR: Duodenal injuries in children: beware of child abuse. *Journal of Pediatric Surgery*, April 2004; 39(4): 600-2
2. Clandenon JN, Meyers RL, Nance ML, Scaife ER: Management of Duodenal Injuries in Children. *Journal of Pediatric Surgery*, 2004; 39: 964-8.
3. Abbas SM, Upadhyay V: Hollow viscus injury in children: Starship Hospital experience. *World Journal of Emergency Surgery* 2007; 2: 14.