

Tracheal Agenesis: A Rare Cause of Unsuccessful Tracheal Intubation During Resuscitation

M Iszuari, A Mazita, GC Tan*, AR Hayati*, I Shareena **, FC Cheah **

Departments of ORL, Pathology* and Paediatrics**, Faculty of Medicine, Universiti Kebangsaan Malaysia Medical Centre, Bandar Tun Razak, 56000 Kuala Lumpur

SUMMARY

Tracheal agenesis is a rare congenital airway anomaly that usually results in a fatal outcome. The diagnosis is usually made through post-mortem examination. In the current literature, there has been no reported long-term survival although a few reports claimed prolongation of life of several hours to days. This condition is commonly associated with premature birth, polyhydramnios and a male predominance. In 90% of the cases, it is associated with multiple cardiovascular, gastrointestinal and genitourinary tract anomalies which are incompatible with life. We report a case of a premature newborn with severe respiratory distress, absent cry and cyanosis soon after birth. Attempts at endotracheal intubation failed as it was not possible to negotiate the tube beyond the vocal cords. Needle cricothyrotomy and attempted tracheostomy also failed to secure the airway. The diagnosis was confirmed at post-mortem examination.

CASE REPORT

A 36-year old Chinese lady went into premature labour at 32 weeks gestation. Apart from polyhydramnios, detected at 29 weeks gestation, she had no other medical conditions such as hypertension or diabetes mellitus. A screening abdominal ultrasound performed when admitted in labour revealed a grossly normal foetus. An emergency Caesarean section was performed because the patient had 2 previous operative deliveries. The Apgar score at 1 minute was 3 and the baby was noted to be gasping and cyanosed. Positive pressure ventilation via bag-and-mask did not improve the colour and no chest inflation was noted. Endotracheal intubation was attempted several times but the tube could not be advanced due to resistance below the vocal cords. An urgent referral was made to the otorhinolaryngology team in view of an emergency tracheostomy. While waiting, a cricothyrotomy was performed using a size 16G cannula. Intermittent positive pressure ventilation was delivered through an adapter resulting in an increase in oxygen saturation to 75% and heart rate to about 110 bpm transiently. Direct laryngoscopy by the otorhinolaryngology team confirmed normal vocal cords but intubation with a size 2.5 mm endotracheal tube still failed. At emergency tracheostomy, a normal tracheal structure could not be identified. There was a rudimentary membranous lumen which was incised but tracheostomy tube insertion to establish an airway was unsuccessful. Despite an hour of resuscitation, the baby could not be saved.

A post-mortem examination revealed normal epiglottis, arytenoids and vocal cords. There was a blind sac below the

subglottis. There was no trachea identifiable (Figure 1) and the two bronchi were seen arising from the oesophagus (Figure 2) (Floyd type III). Further examination revealed a male newborn weighing 1.75 kg, with imperforate anus and truncus arteriosus with ventricular septal defect.

DISCUSSION

Tracheal agenesis (TA) is a rare and severe congenital airway anomaly, characterized by a newborn infant presenting with respiratory distress shortly after birth and difficulty in securing the airway. It should be suspected in any newborn with an absent cry, severe respiratory distress, cyanosis soon after birth and failure of tracheal intubation. This condition has a male predominance and is often associated with prematurity and polyhydramnios^{1,2}. The aetiology remains unknown, although several developmental theories have been proposed. One theory suggests ventral displacement of the tracheo-oesophageal septum resulting in a partial or total TA. In the majority of infants, the diagnosis is only made at post-mortem examination.

The diagnosis may be suspected antenatally with ultrasonographic findings of CHAOS (congenital high airway obstruction syndrome), represented by large echogenic lungs, a flattened or inverted diaphragm, dilated airways distal to the obstruction, polyhydramnios, foetal ascites or hydrops, and vigorous, large amplitude foetal breathing movements^{2,3}. Colour and spectral Doppler ultrasonographic findings include absence of flow at the laryngeal level. Similarly, our case was a 32-week premature male infant whose mother had polyhydramnios. An antenatal ultrasound scan however, failed to identify any foetal abnormality. The suspicion of TA arose when no normal trachea was identified during attempted tracheostomy. A post-mortem examination confirmed Floyd type III TA with truncus arteriosus, ventricular septal defect and imperforate anus.

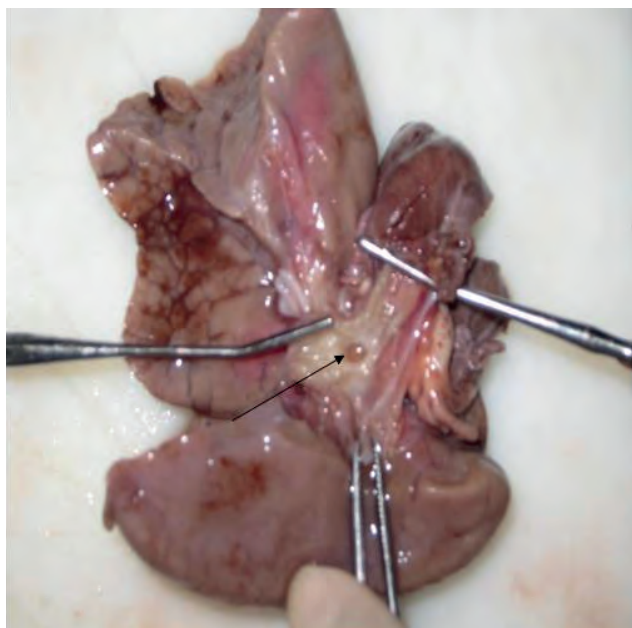
Since the first case reported by Payne in 1900, there has been 116 cases reported worldwide; this being the second case reported in Malaysia^{4,5}. Floyd et al (1962) characterized TA into three types². In type I, there is a short segment of distal trachea arising from the oesophagus. A tracheo-oesophageal fistula connects the distal trachea to the oesophagus. In type II, there is complete TA but both main bronchi join in the midline at the carina. In type III, the trachea is absent and both main bronchi communicate directly with the oesophagus. Type II remains the commonest (61%), with type III and type

This article was accepted: 13 February 2011

Corresponding Author: Mazita Ami, MBChB BaO (UK), MS ORL-HNS (UKMalaysia), Senior Lecturer & ORL Surgeon, Universiti Kebangsaan Malaysia, Otorhinolaryngology-Head & Neck Surgery, Jalan Yaakob Latif, Bandar Tun Razak, Cheras, 56000 Kuala Lumpur, Malaysia. Email: mazitaami@yahoo.com

I accounting for 23% and 13% respectively. The remaining 3% belongs to the indeterminate type. The majority of TA (90%) is associated with multiple congenital anomalies involving the cardiovascular, gastrointestinal and genitourinary systems, making this condition usually un-correctable and incompatible with life. TA has previously been reported as part of VATER (vertebral defects, anal atresia, trachea-oesophageal fistula and/or oesophageal atresia, radial dysplasia, renal defects), VACTERL (VATER plus cardiovascular and limb defects) and TACRD (tracheal/laryngeal agenesis/atresia, complex congenital heart anomalies, radial ray defects, and duodenal atresia) patterns of malformation^{1,2}. However, these patterns of anomalies are not uniformly present in TA. Therefore, it is not surprising that some TA patients share characteristics with VATER, VACTERL, and TACRD associations.

Management of this invariably lethal condition is controversial. A rational approach is to keep the infant alive until a full assessment is completed. It is imperative that an oro-gastric tube is first inserted to decompress the stomach during subsequent resuscitative measures^{1,2}. Bag-mask ventilation via oesophageal intubation will sometimes provide adequate ventilation until a definitive diagnosis is made and complete evaluation for possible surgical intervention is completed. Antenatal diagnosis of the condition provides an early warning and greater preparedness to handle the situation. However, our case was not antenatally diagnosed and the infant's condition deteriorated rapidly despite possibly oesophageal intubation with bag-mask ventilation. There is, hitherto, no effective surgical method to correct this severe congenital airway anomaly. Most infants die during the first day of life due to severe airway compromise and associated anomalies. However, there are several reported cases of survivors who lead a rather diverse but generally poor quality of life. Most authorities concur that supportive care, until demise, is probably the best management, particularly in infants with other major anomalies^{4,5}. There are possible surgical options that are evolving, such as tracheal reconstruction with allografts, autologous tissue, prosthetic material or a combination of these. However, none have been able to yield satisfactory results with respect to clearance of airway secretions, pressure changes during respiration and the growth of the trachea.



CONCLUSION

TA is a rare congenital airway anomaly where diagnosis is often confirmed only at post-mortem. Increased awareness could raise a higher index of suspicion for newborns presenting with respiratory distress shortly after birth, cyanosis, absent cry and failure of intubation through a normal looking larynx. Management is expectant although evolving sophisticated surgical intervention could in the future improve survival of infants diagnosed antenatally with the characteristic ultrasonographic findings of CHAOS.

ACKNOWLEDGEMENT

We would like to thank Associate Professor Dr Asma Abdullah as Head of Department of Otorhinolaryngology UKMMC for allowing publication of this manuscript. We would also like to thank Dr Jeevanan Jahendran for his participation in dealing with this case.

REFERENCES

1. Hirakawa H, Ueno S, Yokoyama S et al. Tracheal agenesis: A Case Report. Tokai J Exp Clin Med 2002; 27: 1-7.
2. Floyd J, Campbell DC Jr, Dominy DE. Agenesis of the trachea. Am Rev Respir Dis 1962;86:557-60.
3. Vaikunth SS, Morris LM, Polzin W et al. Congenital high airway obstruction syndrome due to complete tracheal agenesis: an accident of nature with clues for tracheal development and lessons in management. Fetal Diagn Ther 2009; 26: 93-97.
4. Dijkman KP, Andriessen P, van Lijnschoten G et al.. Failed resuscitation of a newborn due to congenital tracheal agenesis: a case report. Cases J 2009; 17: 7212.
5. Ahmad R, Abdullah K, Mokhtar L et al. Tracheal agenesis as a rare cause of difficult intubation in a newborn with respiratory distress: a case report. J Med Case Reports 2009; 4: 105.

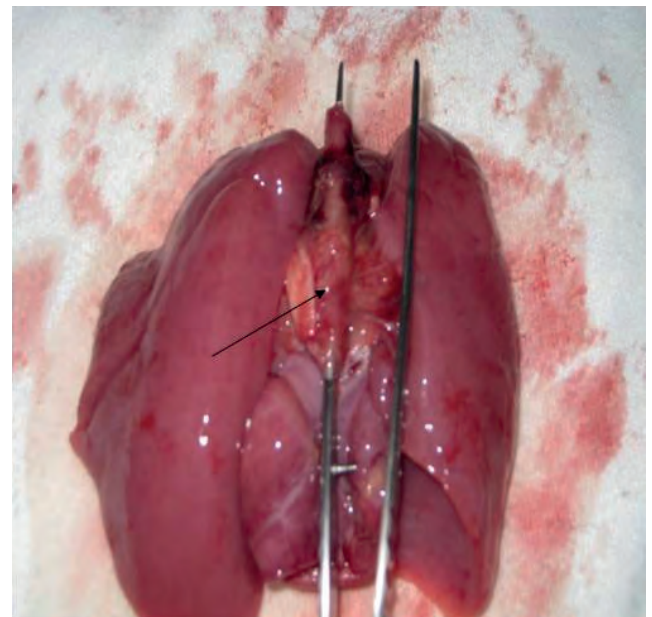


Figure 1: A single lumen connecting the right and left main bronchi, which continues towards the stomach. There was no trachea identified (arrow points to the oesophagus)

Figure 2: An opening (arrow) is seen connecting the oesophagus with the right and left main bronchi