

A Rare Case of Incarcerated Bochdalek Diaphragmatic Hernia in a Pregnant Lady

MAR Islah, MS*, D Jiffre, MS**

*Department of Surgery, Kulliyah of Medicine, International Islamic University Malaysia (IIUM), Jalan Hospital Campus, 25150 Kuantan, Pahang Darul Makmur, Malaysia, **Department of Surgery, Hospital Tengku Ampuan Afzan, Kuantan, Pahang, Malaysia

SUMMARY

The occurrence of congenital diaphragmatic hernia in a pregnant adult is rare. In contrast to neonatal diaphragmatic hernias, most of the adult patients present with vague gastrointestinal symptoms mimicking other diseases hence the importance of high index of suspicion. We report a case of a young pregnant lady with congenital diaphragmatic hernia presenting with symptoms and clinical signs suggestive of acute pancreatitis. The patient had a laparotomy performed to reduce the hernial content and the diaphragmatic defect was successfully repaired.

KEY WORDS:

Bochdalek Hernia, Pregnancy, Pancreatitis, Perforation of Stomach

INTRODUCTION

Adult diaphragmatic hernia in pregnancy is an uncommon disease which either remains asymptomatic or presents with symptoms mimicking other more common pathologies. Diagnosis usually become apparent once complications set in, which are either gastrointestinal, respiratory or cardiovascular. We present a case of adult diaphragmatic hernia in pregnancy, presenting with epigastric pain and localized peritonitis.

CASE REPORT

A 30-year-old lady, Gravida 2 Para 1 at 30 gestational weeks was admitted to the surgical ward with one month history of dull aching epigastric pain. She did not seek any medical advice as the pain was not severe. However, a day prior to the admission the pain became severe and radiated to the back. It was associated with nausea and recurrent non-bilious vomiting. Her previous pregnancy was uneventful.

On arrival to the emergency department, the patient was in severe pain but not tachypneic. Abdominal examination revealed a mildly tender epigastric mass and a gravid uterus. Abdominal sonography revealed a cystic lesion at the epigastric area suggestive of a pancreatic pseudocyst. Serum amylase was mildly elevated (323iu/L). In view of the clinical presentation, the elevated serum amylase levels and the ultrasound findings, a diagnosis of acute pancreatitis in pregnancy was made.

However, a day later the patient suddenly became tachypneic and the epigastric pain worsened. An erect chest x-ray was

done to rule out perforated gastric ulcer and to investigate the cause of sudden respiratory distress. The chest x-ray revealed a radiolucent structure occupying the left hemithorax pushing the heart and the mediastinum to the right. A definitive diagnosis could not be made on the x-ray findings. Therefore, CT scan of the thorax and abdomen was requested. While waiting for the CT scan the patient's condition deteriorated and she became hypotensive. She was immediately intubated, ventilated and started on inotropic support. The CT scan revealed bowel loops in the left hemithorax and a pneumoperitoneum (Figure 1).

An emergency laparotomy was carried out in view of the diagnosis of peritonitis with septicaemia secondary to bowel perforation causes by an obstructed left diaphragmatic hernia. Intraoperatively, there was gush of air during the initial opening of the peritoneum. The peritoneal cavity was contaminated with bowel contents. The distal part of the stomach, the whole large bowel, small bowel and appendix were found inside the left hemithorax. The spleen was at the medial side of the abdomen. There was a 6x4 cm defect at the posterolateral aspect of the left hemidiaphragm (Figure 2). The greater curvature of the stomach was ischaemic with a 2 X 3 cm perforation. The contents of the diaphragmatic hernia were reduced back manually into the abdomen. The ischaemic part of the stomach was excised (sleeve gastrectomy). As the diaphragmatic defect is large, it was closed by non-absorbable suture and a mesh despite the risk of infection. Abdominal drains and a chest tube were inserted. The baby was delivered via caesarian section. The ventilation was greatly improved after the reduction of the contents.

Post-operatively, the patient was ventilated in the Intensive Care Unit for five days before being transferred to the general ward. The patient progressed well and was discharged from the hospital a week later and is still under our surgical outpatient clinic follow up.

DISCUSSION

Congenital diaphragmatic hernias are divided into eventration of the diaphragm, posterolateral hernia of Bochdalek, Parasternal hernia of Morgagni-Larrey, and peritoneo-pericardial hernia. Posterolateral hernia of Bochdalek, the most common type of diaphragmatic hernia, rarely presents beyond the neonatal period. The incidence of reported incidental Bochdalek hernia is 0.17%¹. The

This article was accepted: 2 February 2010

Corresponding Author: Islah Munjih Bin Ab. Rashid, Department of Surgery, Kulliyah of Medicine, International Islamic University Malaysia (IIUM), Jalan Hospital Campus, 25150 Kuantan, Pahang Darul Makmur, Malaysia Email: islah75@hotmail.com

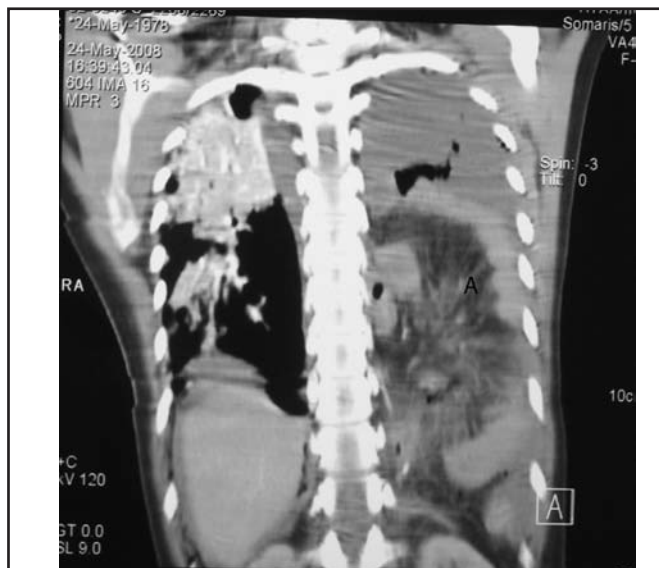

Fig. 1: Reconstructed CT scan thorax of the patient showing the small bowels and their mesenteries in the left hemithorax. A: Small bowels with mesenteries.

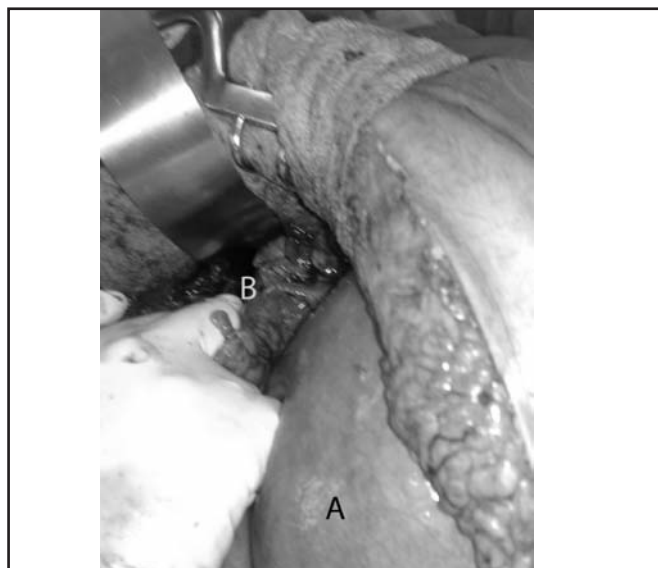


Fig. 2: Intra-operative picture showing the gravid uterus and the diaphragmatic defect. A: Gravid uterus; B: The diaphragmatic defect.

incidence of Bochdalek hernia in pregnancy is even rarer. So far there are only 34 cases reported since 1928².

Bochdalek hernia commonly occurs on the left side of diaphragm. This is due to the earlier fusion of the right pleuroperitoneal fold. Furthermore, the presence of the liver on the right prevents the occurrence of right-sided Bochdalek hernia in most of the cases. In our patient the hernia developed on the left side.

Our patient presented with the common symptom of epigastric pain, nausea and vomiting. However, due to the rarity of the disease in adults, leave alone in pregnant ladies, the disease was not suspected. Furthermore, the raised in serum amylase and the ultrasound findings of pancreatic pseudocyst had led us to a misdiagnosis of acute pancreatitis. However, in our patient, the diagnosis was later made only after the complications developed.

The presence of a gravid uterus increases intraabdominal pressure and increases the risk of complications such as incarceration, obstruction and strangulation. Our patient had recurrent vomiting which further increased the intraabdominal pressure and subsequently increased the herniation of the abdominal contents into the thoracic cavity. This explained the occurrence of the sudden onset of respiratory distress, ischemia and perforation of the gastric wall. Furthermore, the presence of mediastinal shift to the right, in addition to possible sepsis, led to reduction in venous return and subsequently hypotension, which occurred in this patient.

Adult diaphragmatic hernias are most commonly repaired with simple suturing or mesh repair depending on the size of the defect. Mesh repair in a contaminated area is not recommended but it can be attempted provided there is coverage with a well vascularized tissue³. Thoracotomy approach has the advantage of easier repair of the defect while laparotomy allows easier dealing with incarcerated

viscera that may require resection. In our case, we repaired the defect via laparotomy, as the patient's condition did not permit a lengthy operation.

It is wise to repair a diaphragmatic hernia electively after stabilization. However, this was not possible in our patient as the ventilation could not maintain adequate perfusion and urgent reduction of the hernial content had to be done to save the patient. In pregnancy, the diaphragmatic hernias are commonly repaired post-partum after stabilization or if there was no complication. To our knowledge there were only two cases of diaphragmatic hernia in pregnancy, which were repaired antepartum⁴. In our case, the hernia was repaired antepartum because it compromised the ventilation of the patient and stabilization without reduction of the hernia had failed. Furthermore, the patient had pneumoperitoneum suggestive of perforated hollow viscus which needed an urgent operation.

In conclusion diaphragmatic hernias in adults and pregnancy are a very rare entity. Due to the rarity of the disease and the vague presentations mimicking other diseases, high index of suspicion is needed to diagnose the disease especially in pregnant ladies with sudden onset of respiratory distress. Finally, even though the risk of morbidity and mortality is high once complications arise, prompt successful repair of the diaphragmatic hernia will improve the outcomes.

REFERENCES

1. Brian K.P. Goh *et al.* Right sided Bochdalek's hernia in an adult. *Am J Surg* 2007; 194: 390-91.
2. Kaloo PD, Studd R, Child A. Post partum diagnosis of maternal diaphragmatic hernia. *Aust NZL Obstet Gynaecol* 1988; 71: 869-71.
3. Bulic K, Dzepina I, Mijatovic D, Unusic J. Prosthetic Mesh for Infected Abdominal Wall Defects? Report of A Patient with A Large Full Thickness Abdominal Wall Defect and Colostomy due to A Gunshot Wound. *Plast, Reconst Aesthet Surgery* 2008; 61: 455-58.
4. Mehmet RG, Thomas EC, Stephen JF, Errol N. Maternal Congenital Diaphragmatic Hernia Complicating Pregnancy. *Obstet Gynecol* 2003; 102: 1194-6.