

# A Rare X-Linked Inherited Mucocutaneous Syndrome in Two Siblings

L A Chong, MRCPCH, H Ariffin, PhD

Department of Paediatrics, Faculty of Medicine, Universiti of Malaya, 50603 Kuala Lumpur

## SUMMARY

We report on an 11 year-old boy with dyskeratosis congenita who presented with dystrophic nails, dysphagia, hyperpigmentation and oral leukoplakia. He had a brother who died 14 years earlier with similar presenting symptoms and aplastic anaemia. Genetic studies of our patient demonstrated the presence of a *DKC1* mutation and confirmed our diagnosis. Further genetic screening revealed that his mother and one of his four sisters are heterozygous for the same mutation.

## KEY WORDS:

*Dyskeratosis congenita, Oral leukoplakia, Aplastic anaemia, Genetics*

## INTRODUCTION

Dyskeratosis congenita (DKC) is a genetic disorder exhibiting clinical and genetic heterogeneity. It is a rare condition and there has only been one case reported in Malaysia<sup>1</sup>. It is often characterized by a clinical triad of reticulated skin pigmentation, oral leukoplakia and nail dystrophy. Patients with DKC have an increased risk of malignancy. Bone marrow failure is present in 60-70% of patients and is the main cause of mortality<sup>2</sup>.

There are X-linked recessive, autosomal recessive and autosomal dominant subtypes and they are all thought to be related to defective telomere maintenance<sup>3</sup>. The most common subtype, recognized in about 40% of patients with DKC, is X-linked recessive with mutations in the dyskeratosis congenita gene 1 (*DKC1*) on Xq28<sup>2,3</sup>. Autosomal dominant DKC have been reported to be due to mutations in *TERC* and *TERT* genes<sup>3</sup>. We report on DKC in two siblings and the mutation found in this family.

## CASE REPORT

An 11 year-old boy of Indian descent (KP) presented with 3 years of dystrophic nails, 2 years of intermittent dysphagia and six months of oral leukoplakia. He is the only surviving son of a non-consanguineous couple and he has four sisters (Figure 1). He had a brother (JP) who died 14 years earlier at the age of 12 years from bone marrow and liver failure. KP had normal development and academic performance. Family history did not reveal any other male relatives with similar clinical manifestations, malignancies or incidence of bone marrow failure.

On examination, KP was not pale or jaundiced. His weight and height were both between 25-50th percentile. He had dystrophic nails (Figure 2), reticulated skin pigmentation, oral leukoplakia and ulcerations. KP was prepubertal with testicular volume of 1ml bilaterally and he had phimosis. The rest of his examination was unremarkable.

Laboratory investigations revealed haemoglobin 126g/L, total white cell count  $5.7 \times 10^9/L$  (neutrophils 32% lymphocytes 54%), platelet count  $200 \times 10^9/L$ . His renal and liver profiles were within normal limits. Bone marrow aspiration showed mildly depressed granulopoiesis with adequate erythropoiesis and megakaryocytes. Upper gastrointestinal endoscopy and barium swallow were normal.

KP fitted the clinical criteria of DKC and with the history of a similarly affected male sibling, mutation analysis of the *DKC1* gene was performed. After counselling and informed consent, genomic DNA was extracted from peripheral blood leukocytes from KP and members of his immediate family. The entire coding sequence and 5' flanking sequence of the *DKC1* gene was screened for point mutations by denaturing high-performance liquid chromatography (HPLC) analysis on a WAVE DNA fragment analysis system (Transgenomic, Glasgow, UK). Exons 1 to 15 of the *DKC1* gene were amplified using primers and protocols as previously described. Direct DNA sequencing of a fragment showing an abnormal pattern of elution was performed on a second independent PCR product from KP's DNA. Confirmation of the presence of the mutation and its segregation within the family were demonstrated using a mutation specific forward primer (5'CTATTGCATTAATGACCACCG3') that includes a deliberate mismatch (underlined) causing a *SacII* restriction enzyme site to be lost from the PCR product when the mutation is present (Figure 3). KP's mother and a sister were found to be heterozygous for this mutation.

His brother (JP) was referred to UMMC 14 years ago with pancytopenia at the age of 12 years with a 3-year history of brittle nails, leukoplakia, truncal hyperpigmentation and progressive dysphagia for which he had received multiple oesophageal dilatation procedures. Bone marrow examination revealed hypoplasia. From the clinical symptoms, he was diagnosed to have dyskeratosis congenita and genetic studies were not available then. Haematopoietic stem cell transplant was planned for him but his parents refused further care. A few months after discharge, he presented with severe jaundice and subsequently died at a district hospital.

This article was accepted: 1 November 2009

Corresponding Author: Chong Lee Ai, Department of Paediatrics, Faculty of Medicine, Universiti of Malaya, 50603 Kuala Lumpur, Malaysia  
Email: leeai@um.edu.my

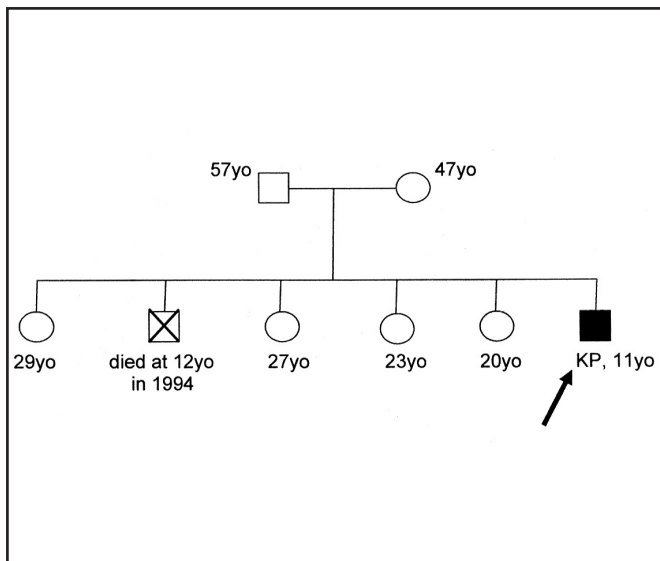


Fig. 1: Family tree of KP

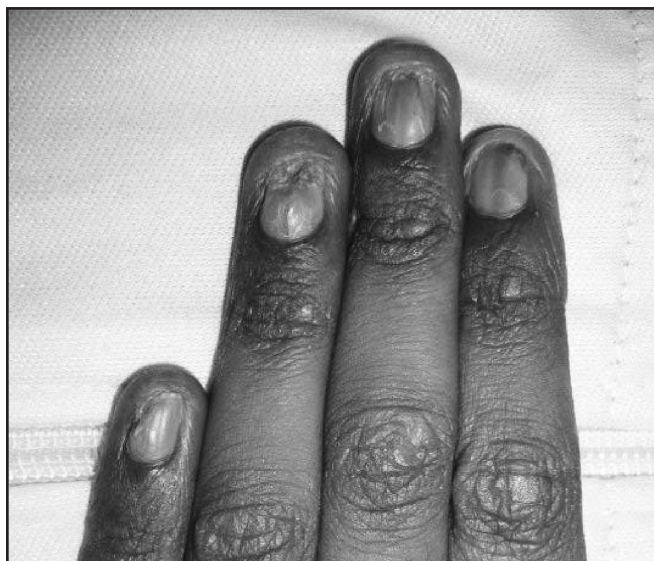


Fig. 2: Dystrophic nails of patient KP

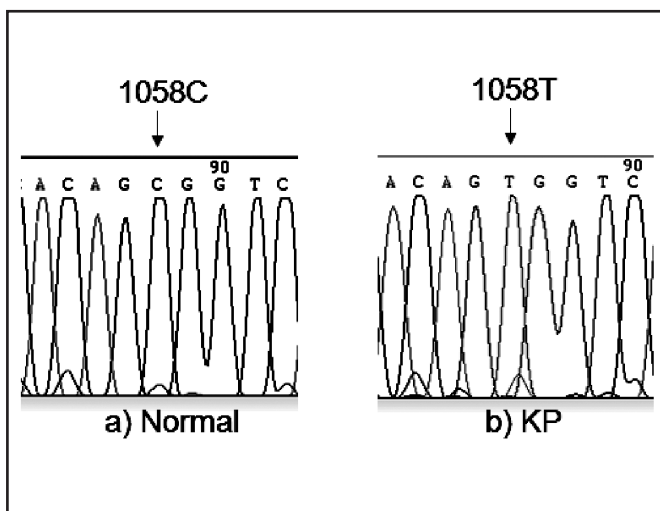


Fig. 3: Sequence of PCR products showing a C to T substitution at nucleotide 1058 in a) normal control and b) patient KP

**DISCUSSION**

The majority of patients presenting with pancytopenia have an unknown or idiopathic aetiology. There are, however, several rare inherited bone marrow failure syndromes that should be considered. Some of the rare bone marrow failure syndromes are Fanconi’s anaemia, Shwachman-Diamond syndrome, Pearson syndrome and dyskeratosis congenita<sup>2</sup>. A thorough family history and clinical examination will aid in differentiating these diagnoses.

In our patient KP, the diagnosis of dyskeratosis congenita was made as he presented with the characteristic triad of nail dystrophy, oral leukoplakia and reticulated hyperpigmentation. In addition, he had a male sibling with the similar clinical triad and bone marrow failure.

In dyskeratosis congenita, the skin pigmentation and nail changes typically appear first, usually by the age of 10 years and bone marrow failure usually develops below the age of 20 years. Other multisystem (dental, gastrointestinal, genitourinary, neurological, ophthalmic, pulmonary and skeletal) manifestations are not uncommon<sup>2</sup>. Our patient had dysphagia with phimosis and hypogonadism.

Further helpful investigations are chromosomal fragility testing and mutation analysis. Lymphocytes from patients with dyskeratosis congenita generally do not show chromosomal fragility as seen in Fanconi’s anaemia<sup>2</sup>. Patients with Shwachman Diamond Syndrome and Pearson Syndrome will often present with pancreatic insufficiency<sup>4,5</sup>.

*DKC1* encodes for dyskerin protein which associates with telomerase, an enzyme complex that is important in maintaining chromosomal telomere length after cell division. It is believed that this chromosome instability results in the pathology of disease in DKC<sup>3</sup>. Hence the diagnosis of DKC can be confirmed with mutations in *DKC1*. Genetic counseling and family studies can be offered to patients if the mutation can be identified.

The only curative option for bone marrow failure in DKC is an allogeneic hematopoietic stem cell transplant<sup>2</sup>. As there is an increased predisposition to malignancy in patients with DKC, close monitoring is important in patient management.

**CONCLUSION**

Dyskeratosis congenita is a rare condition but it should be considered in patients with trilineage hematopoietic defects. Presentation of dyskeratosis congenita is heterogeneous and mucocutaneous manifestations are characteristic. Diagnosis can be confirmed with mutation analysis. Genetic counseling and close monitoring for complications are important for all patients with DKC.

**ACKNOWLEDGEMENT**

We would like to thank Professor Inderjeet Dokal and Dr Tom Vulliamy from the Institute of Cell and Molecular Science, Barts and The London, Queen Mary's School of Medicine and Dentistry for the mutation analysis.

**REFERENCES**

1. Hamidah A, Rashid RA, Jamal R *et al*. X-linked dyskeratosis congenita in Malaysia. *Pediatr Blood Cancer* 2008; 50: 432.
2. Dokal I. Fanconi's anaemia and related bone marrow failure syndromes. *British Medical Bulletin* 2006; 1-17.
3. Kirwan M, Dokal I. Dyskeratosis congenita: a genetic disorder of many faces. *Clin Genet*. 2008; 73: 103-12.
4. Dror Y. Shwachman-Diamond Syndrome. *Pediatr Blood Cancer* 2005; 45: 892-901.
5. Pearson HA, Lobel JS, Kocoshis SA *et al*. A new syndrome of refractory sideroblastic anaemia with vacuolization of marrow precursors and exocrine pancreatic dysfunction. *J Pediatr* 1979; 95: 976-84.