

# A Rare Case of Alpha-Thalassaemia Intermedia in a Malay Patient Double Heterozygous for $\alpha^+$ -Thalassaemia and a Mutation in $\alpha 1$ Globin Gene CD59 (GGC→GAC)

George E\*, JAMA Tan\*\*, A S Nor Azian\*\*\*, Rahimah A\*\*\*\*, Zubaidah Z\*\*\*

\*Faculty of Medicine and Health Sciences, Universiti Putra Malaysia, \*\*Department of Pathology, Hospital Malacca, \*\*\*Unit Haematology, Institute of Medical Research, \*\*\*\*Department of Molecular Genetics, Faculty of Medicine, Universiti of Malaya, 50600 Kuala Lumpur, Malaysia

## SUMMARY

A rare case of thalassaemia-intermedia involving a non-deletion alpha thalassaemia point mutation in the  $\alpha 1$ -globin gene CD59 (GGC→GAC) and a deletion  $\alpha^+$  ( $-\alpha^{3,7}$ ) thalassaemia in which use of high performance liquid chromatography (HPLC) C-gram Hb subtype profile and DNA molecular analysis helped establish the diagnosis.

## KEY WORDS:

Alpha-thalassaemia intermedia, Non-deletion  $\alpha 1$  globin gene CD59, Deletion  $-\alpha^{3,7}$ , HPLC, Molecular analysis.

## INTRODUCTION

The  $\alpha$ -thalassemias are the most common single-gene diseases in the world. They are characterized by a reduction or complete absence of  $\alpha$ -globin gene expression. Normal individuals have two  $\alpha$  genes on each chromosome 16 ( $\alpha\alpha/\alpha\alpha$ ). The loss of one ( $-\alpha$ ) or both ( $--$ ) of the *cis*-linked genes are the most common causes for  $\alpha$ -thalassaemias. Patients with alpha-thalassaemia intermedia with only one functional  $\alpha$ -globin gene ( $--/\alpha$ ) develop chronic haemolytic anaemia of variable severity. HbH disease is the common cause alpha-thalassaemia intermedia. This condition is characterized by a strongly positive H-inclusion test. Non-deletional HbH disease has been described to be more severe than the deletional type<sup>1</sup>. The most severe form of alpha thalassaemia is Hb Barts hydrops foetalis where there are no functional  $\alpha$ -globin genes ( $--/--$ ) and results in the condition where death occurs *in utero* or within a few hours of birth. In this case report, a rare case of alpha- thalassaemia intermedia is presented where the H-inclusion test is negative.

## CASE REPORT

A 52-year old Malay male presented with pallor, generalized malaise, jaundice and hepatosplenomegaly. There was no family history of thalassaemia. The haematology work-up included a full blood picture, thalassaemia screen tests and a liver profile. Blood specimens were drawn into tubes (Becton Dickinson Vacutainer Systems) containing dipotassium ethylene diamine tetraacetic acid (EDTA) for full blood picture and thalassaemia diagnosis (quantification of Hb subtypes and DNA studies), into plain tubes for serum ferritin and liver profile studies.

Thalassaemia screen using the BHES protocol was done. The acronym BHES refers to a multi-step process for screening of thalassaemia where B is for blood counts and blood film, H for high performance liquid chromatography, E for electrophoresis and S for stability. B: Blood counts were generated on an automated blood counter (Cell-Dyn, Abott laboratories). He was noted to have severe anaemia with a haemoglobin level of 5.6 gm/dl (normal range 13-18 gm/dl), hypochromic-microcytic red cell indices, reticulocytosis and a thalassaemia peripheral blood film (anisopoikilocytosis, hypochromia, basophilic stippling, target cells, and fragments). H: a specimen collected in EDTA was analyzed on the Bio-Rad Variant high performance liquid chromatography (HPLC) Hb analyzer (Bio-Rad Laboratories) to determine the distribution of Hb subtypes with the use of the  $\beta$ -thalassaemia short program recorder pack as described in the instruction manual for the assay. The Hb subtypes noted were HbA, HbF, HbA and a pre-run peak of Hb Barts, shown Figure 1. There was no HbH seen. E: Hb electrophoresis by automated agarose gel electrophoresis (Sebia) on alkaline pH8.5 showed

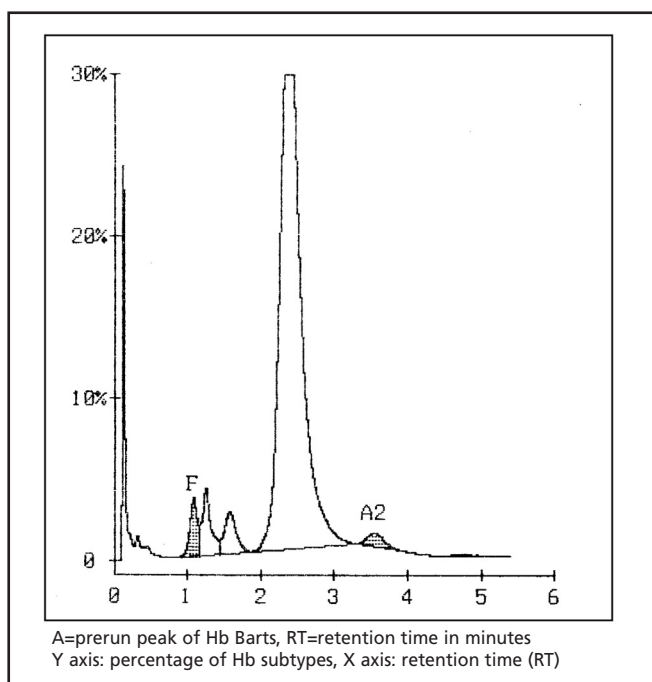


Fig. 1: HPLC C-gram of alpha thalassaemia-intermedia ( $CD59/-\alpha^{3,7}$ )

This article was accepted: 6 November 2009

Corresponding Author: Elizabeth George, Haematology Unit, Department of Pathology, Faculty of Medicine and Health Sciences, Universiti Putra Malaysia, 43400 UPM Serdang, Selangor, Malaysia Email: elzageorge@hotmail.com

similar findings of Hb subtypes seen with HPLC. S: the H-inclusion test was negative. The serum ferritin was 340µg/L (normal 150-300 µg/L). The liver enzymes were normal and the unconjugated bilirubin level was raised. The antiglobulin test (Coombs test) was negative. Genomic DNA was extracted from peripheral blood using standard methods and multiplex polymerase chain reaction (PCR)<sup>2</sup> was done to detect the following  $\alpha$ -thalassaemia mutations: single gene deletion ( $-\alpha^{3,7}$ ,  $-\alpha^{4,2}$ ), two gene deletions ( $--_{SEA}$ ,  $--_{FIL}$ ,  $--_{MED}$ ,  $--_{THAI}$ ,  $--\alpha^{20.5}$  and non-deletion  $\alpha$ -thalassaemia (initiation codon (CD) ( $\underline{ATG}\rightarrow\underline{GTG}$ ), CD30, CD35 ( $\underline{TCC}\rightarrow\underline{CCC}$ ), Hb Quong Sze or CD125 ( $\underline{CTG}\rightarrow\underline{CCG}$ ), Hb Constant Spring or CD 142 ( $\underline{TAA}\rightarrow\underline{CAA}$ ) and, CD59 ( $\underline{GGC}\rightarrow\underline{GAC}$ )<sup>3</sup>. The patient was found to be heterozygous for the single deletion ( $-\alpha^{3,7}$ ) and the non-deletion mutation CD59 ( $\underline{GGC}\rightarrow\underline{GAC}$ ).

### DISCUSSION

Patients with alpha thalassaemia-intermedia have moderate anaemia with Hb levels between 7-10gm/dl. The manifestations include thalassaemia facies, jaundice and hepatosplenogaly that range from mild to moderate. Growth and development is normal. Gallstones and iron overloading in the absence of blood transfusions have been seen. The H-inclusion test is strongly positive in these cases. In this case report, the patient had  $\alpha$ -thalassaemia intermedia phenotype with severe anaemia (Hb 5.6 gm/dl) with thalassaemia features in the peripheral blood film in the absence of a positive H-inclusion test.

Alpha-thalassaemia is caused by both deletion and non-deletion mutations in the alpha globin gene complex. In contrast to  $\beta$ -thalassaemia, deletions are more common than non-deletional defects. Commonly,  $\alpha$ -thalassaemia-intermedia presents as HbH disease from the interaction of deletion of both the  $\alpha$ -globin genes in cis ( $\alpha^0$ ) ( $\alpha$ thal 1) and  $\alpha^+$  ( $\alpha$ thal 2) phenotype. The molecular defects resulting in a single deletion of the  $\alpha$  globin gene are the rightward deletion  $-\alpha^{3,7}$  and the leftward deletion  $-\alpha^{4,2}$  with  $-\alpha^{3,7}$  being the more common mutation. The double deletion defects ( $\alpha^0$ ) of the  $\alpha$  globin genes in cis are  $--_{SEA}$ ,  $--_{FIL}$ ,  $--_{MED}$ ,  $--_{THAI}$  and  $--_{20.5}$ . The most common non-deletion single gene defect ( $\alpha^+$ ) is Hb Constant Spring. This is a termination codon defect ( $\underline{TAA}\rightarrow\underline{CAA}$ ) results in a long mRNA with 31 extra amino acids being formed. The long mRNA is unstable resulting in reduced production of  $\alpha$  globin chains and a  $\alpha^+$  phenotype. HbH-Constant Spring has a more severe clinical phenotype than deletion HbH disease. The nondeletion molecular defect in the  $\alpha$ -globin 1 gene

CD59 ( $\underline{GGC}\rightarrow\underline{GAC}$ ) results in the formation of hyperunstable  $\alpha$  Hb variant. It is a rare cause for  $\alpha$ -thalassaemia-intermedia when the mutation combines with a  $\alpha^+$  deletion defect. If the mutation occurs in the  $\alpha 2$ -globin gene it results in hydrops fetalis. mRNA formation in  $\alpha 2:\alpha 1$  is 3:1 and accounts for the condition being more severe when the  $\alpha 2$  gene is involved. The two cases first reported with  $\alpha$ -thalassaemia-intermedia were from Turkey<sup>4</sup>. The true frequency of the molecular defect in the  $\alpha$ -globin 1 gene CD59 ( $\underline{GGC}\rightarrow\underline{GAC}$ ) is unknown as the defect can only be ascertained by DNA studies. This  $\alpha$  Hb variant is hyperunstable and has no product to be visualized by routine haematology studies. Screening for thalassaemia by blood counts and Hb subtyping will miss the diagnosis in contrast to beta-thalassaemia where determination of Hb subtypes presumptively identifies the presence of thalassaemia.

This is the first report described in a Malay patient from Malaysia. The presence of  $\alpha 1$ CD59 ( $\underline{GGC}\rightarrow\underline{GAC}$ ) may be the result of migration from countries bordering the Mediterranean sea as the Malays have links with Turkey, Iran and the Middle East. The true frequency of this alpha Hb variant cannot be identified by screening methods such as the BHES protocol as it is hyper-unstable. This case report highlights the need to consider a hypersunstable  $\alpha$  Hb variant [ $\alpha 1$ CD59 ( $\underline{GGC}\rightarrow\underline{GAC}$ )] in a patient with alpha thalassaemia-intermedia in the absence of a strongly positive H-inclusion test with normal Hb subtypes and presence of Hb Barts. Confirmation is required by DNA analysis as shown in this case.

### ACKNOWLEDGEMENT

The study was supported by an e-Science grant 02-01-04-SF0876, Ministry of Science Technology and Innovation Malaysia (MOSTI).

### REFERENCES

1. George E, Ferguson V, Yakas J *et al.* A molecular marker associated with mild hemoglobin H disease. *Pathology* 1989; 21: 27-30.
2. Chong SC, Boehm CD, Higgs DR *et al.* Single-tube multiplex-PCR screen for common deletional determinants for  $\alpha$ -thalassaemia. *Blood* 2000; 95: 360-2.
3. Eng B, Patterson M, Walker L *et al.* Detection of severe nondeletional  $\alpha$ -thalassaemia mutations using a single-tube multiplex ARMS assay. *Genetic testing* 2001; 5: 327-9.
4. Douna V, Passotiriou I, Garoufi A *et al.* A rare thalassaemia syndrome caused by interaction of Hb Adana [ $\alpha$ 59(E)Gly $\rightarrow$ Asp] with  $\alpha$ -deletion thalassaemia: clinical aspects in two cases. *Hemoglobin* 2008; 32: 361-9.