

# Long Term Results of Endoscopic Resection of Nasopharyngeal Tumours

H N Tay, MMed(ORL), J L Leong, FRCS, D S Sethi, FRCS

Department of Otolaryngology, Singapore General Hospital, Outram Road, Singapore 169608

## SUMMARY

Traditional open approaches to the nasopharynx either provide limited access and risk significant morbidity. Here we describe our experience with endoscopic resection of nasopharyngeal tumours. Retrospective chart review was performed for all patients who underwent endoscopic nasopharyngeal resection from September 1993 to January 2007 at a tertiary rhinology centre. Six patients underwent endoscopic nasopharyngectomy for tumours arising from or involving the nasopharynx. The mean age was 49.8 years (range 23 – 70). The sex distribution was five males and one female. Four tumours were malignant and two were benign. The mean disease-free and overall survival for malignant tumors was 90.75 months (range 66 - 120 months). None of the benign tumors recurred. The endoscopic nasopharyngectomy technique may be successfully used for resection of tumors arising from or involving the nasopharynx with good efficacy and a decrease in morbidity when compared to open approaches.

## KEY WORDS:

*Endoscopic surgery, Nasopharyngectomy, Nasopharyngeal Carcinoma, Tumors, Recurrent*

## INTRODUCTION

Over the last decade, minimally invasive endoscopic resection of paranasal and skull base tumors has been increasingly utilized with good surgical outcome comparable to the traditional external approaches<sup>1,2</sup>. The extended transnasal endoscopic approach has been well described for lesions involving areas like the lateral sphenoid recess<sup>3</sup>, orbit<sup>4</sup>, skull base, clivus and posterior fossa<sup>5</sup>.

Lesions primarily involving the nasopharynx are rare and surgical access to this site was often thought to be unsafe. However, over the years several procedures have been described for resection of lesions in the nasopharynx,<sup>6</sup> inferiorly via the trans-palatal route<sup>7</sup>, laterally via a trans-temporal or infratemporal route<sup>8</sup> and anteriorly via the maxillary swing approach<sup>9</sup>. Unfortunately all these approaches may have limited exposure and/or considerable post-operative morbidity. This is due to the extensive and often complex mobilization that is needed in these procedures.

As a natural extension of our endoscopic surgical expertise we have utilized the extended endoscopic approach for lesions involving the nasopharynx. Here we describe our experience with endoscopic nasopharyngectomy.

## MATERIALS AND METHODS

Retrospective chart review was performed for all patients that underwent endoscopic nasopharyngectomy from September 1993 to January 2007 at a tertiary rhinology centre. All cases were performed by the senior surgeon, DSS. Patient demographics, tumor histology, disease-free period and overall survival outcomes were assessed. The techniques for endoscopic nasopharyngectomy were evaluated, including the need for carotid artery control via neck incision.

## RESULTS

Six patients underwent endoscopic nasopharyngectomy for tumors arising from or involving the nasopharynx. The mean age was 49.8 years (range 23– 70 years). The sex distribution was five males and one female. The indications for resection included 4 malignant and 2 benign neoplasms. One patient received adjuvant radiation post-operatively. The 2 benign lesions did not recur during the entire follow-up period. For the malignant tumours, the mean disease-free survival was 90.75 months (range 66-120 months). Overall survival is taken to be the same as both patients with recurrences defaulted further follow-up. The recurrences in NPC patients occurred more than five years after nasopharyngectomy. No significant postoperative complications were noted. Mean follow-up was 63.2 months (range 7 – 120). (Table I)

### *Surgical Technique*

Here we describe the surgical technique that was utilized in our first two cases:

### *Case Study 1*

A 45-year old Chinese male had a T2 N2 M0 undifferentiated nasopharyngeal carcinoma diagnosed in February 1993. His initial presentation was a 6-cm diameter left cervical lymphadenopathy. The primary site and neck were irradiated with 6613cGy and 7000cGy respectively. Seven months later, a local recurrence was noted in the left side of the nasopharyngeal roof. He underwent irradiation with a combination of external and intra-cavitary brachytherapy to a dose of 6500cGy. He remained well till January 1997 when the tumor recurred. This was staged as rT1 N0 M0. Histology of the second recurrence was that of a moderately differentiated squamous cell carcinoma. CT scan showed an enhancing tumor effacing the left lateral recess of the post-nasal space. (Fig. 1)

*This article was accepted: 15 March 2009*

*Corresponding Author: Tay Hin Ngan, Department of Otolaryngology, Singapore General Hospital, Outram Road, Singapore 169608*

*Email: tay.hin.ngan@gmail.com*

*Technique*

The operation was performed under general anesthesia with the patient supine. A tracheostomy was performed to secure the airway. A careful inspection of the nasopharynx with the rigid endoscope was first performed. The nasal cavity was decongested with topical 4% cocaine. One percent lidocaine and 1:80,000 epinephrine was used to infiltrate the mucoperichondrium of the nasal septum and operative field of the nasopharynx. Next the left internal and external carotid arteries were isolated through a skin crease upper neck incision and proximal control obtained with vessel loops. The internal carotid artery was dissected superiorly to the skull base and protected medially and anteriorly with a malleable retractor.

The rest of the surgery was then performed entirely via the transnasal endoscopic route. A posterior septectomy was performed to allow a panoramic view of the nasopharynx and access by instruments via each nares. Septal mucosa was harvested prior to septectomy as a free graft. The boundaries of the graft were: anteriorly, along the bony-cartilaginous junction, posteriorly over the sphenoid rostrum, inferiorly along the palate and superiorly over the cephalic edge of the bony septum. The septal cartilage and anterior nasal septum was preserved to maintain the bridge of the nose. In recent cases, we now use the Hydad flap or vascularised nasoseptal flap for reconstruction rather than a free graft.

Dissection of the nasopharynx followed. Bilateral sphenoid ostia were first identified, widened medially and connected in the midline. The rest of the sphenoid face and rostrum was subsequently removed. Mucosa was then elevated from the face of sphenoid from a superior to inferior direction. The floor of the sphenoid sinus was then removed using a combination of Kerrison punches and cutting burr. The right lateral margin of the tumor was first defined with diathermy along the posterior edge of the right Eustachian tube. The mucosa was incised down to bone and then elevated medially. The inferior cut was then made at the level of the soft palate to reach the left lateral wall of the nasopharynx. The left lateral margin included excising the left Eustachian tube as laterally as possible. With a combination of scissors and diathermy dissection the lateral limit of resection was defined with adequate margins around the tumour. The entire specimen was removed en-bloc with no carotid exposure. A cutting burr was then used to drill the surface of the clivus and vertebral body to obtain additional surgical margin. Frozen sections were obtained to ensure clear margins. Hemostasis was achieved with cautery. The septal mucosa graft was then placed onto the raw nasopharynx and held in place with a nasal pack.

The total operation time was 6.0 hours and the total blood loss was 250cc. The patient was fed orally on the second post-operative day. The nasal pack was removed on the 5th day and the nasal cavity inspected. The patient was discharged on the seventh post-operative day. No significant complication was noted. CT scan done post-operatively at three months showed no recurrence (Fig. 2) and the patient was well till the last follow-up in February 2007 when he was found to have a local recurrence in the nasopharynx.

*Case Study 2*

A 65 year old female presented with intermittent blood stained nasal discharge of one month duration in August 1997. Her only comorbidity was hypertension. Nasoendoscopy revealed an infiltrative tumor arising from the right side of the nasopharynx with its antero-lateral edge involving the right fossa of Rosenmüller and the entire right torus tubarius. Biopsy revealed tumor of glandular or minor salivary gland origin. CT scan showed a large soft tissue mass in the right posterior wall and roof of the nasopharynx with extension to the right retropharyngeal space. No bony skull base erosion superiorly or retropharyngeal lymphadenopathy was noted. MRI confirmed the CT findings of a right nasopharyngeal mass measuring 2.5x2.9x2.7cm. (Fig. 3) Some infiltration into the prevertebral muscle planes and displacement of the carotid sheath posteriorly was noted. Decision was made at the Tumor Board for wide excision and possible radiotherapy as adjuvant treatment.

*Technique*

Endoscopic nasopharyngectomy was carried out on October 1997. Similar to the previous case, the preparatory work for general anaesthesia was done but no tracheostomy was performed. The internal and external carotid arteries were again accessed through a neck incision for control.

A posterior septectomy was first performed to increase the space for instrumentation and visualization. This was done with a combination of backbiters, Kerrison's punches and strong through-cutting forceps to remove the bony septum from a posterior to anterior direction. No mucosa graft was harvested. Once exposure was sufficient, attention was then turned to the resection of the tumor. The superior margin was defined by the removal of the sphenoid face and floor as previously described. The lateral margin consisted of the entire torus tubarius and inferiorly the soft palate. The entire specimen was removed en bloc down to the bony nasopharyngeal roof and posterior wall. The specimen included the underlying muscle (superior pharyngeal constrictor and fascia) and a right truncated torus tubarius. The internal carotid artery was not exposed in the nasopharynx. After achieving adequate hemostasis, the nasopharynx was then packed with a quarter-inch roller gauze and an inflated Foley's catheter balloon. A bismuth iodoform pack was further placed in the right nasal cavity.

The total operative time was 4.5 hours. The patient was fed orally on the second post-operative day. The nasal pack was removed on the 3rd post operative day and the nasal cavity inspected. Moderate amount of oozing was seen from the surgical site. The Foley's catheter balloon was reinserted and merocel packs placed in both nasal cavities. Post-operatively, patient was noted to have a decreased hemoglobin level of 8.9 g/dL from a pre-operative level of 12.7g/dL and was transfused with two units of packed red blood cells. Two days' later, the packs were removed with no further bleeding and the patient was discharged on the 6th post-operative day.

Paraffin section confirmed the diagnosis as invasive adenocarcinoma with involvement of the anterolateral margins. The rest of the margins, including the depth were clear. The patient subsequently was given 70cGy irradiation therapy. The patient is disease free at 101 months post surgery.

Table I: Patient biodata and tumor characteristics

Age (Years)	Sex	Diagnosis	Disease free period (Month)	Adjuvant therapy	Status
65	F	Adenocarcinoma	101	RT	NED
46	M	Inverted Papilloma	12	Nil	NED
70	M	Adenocarcinoma (low grade)	76	Nil	NED
23	M	JNA	7	Nil	NED
45	M	Recurrent NPC	120	Nil	R
44	M	Recurrent NPC	66	Nil	R

+NED – No evidence of disease

#R- Recurrence

\*RT- Radiotherapy

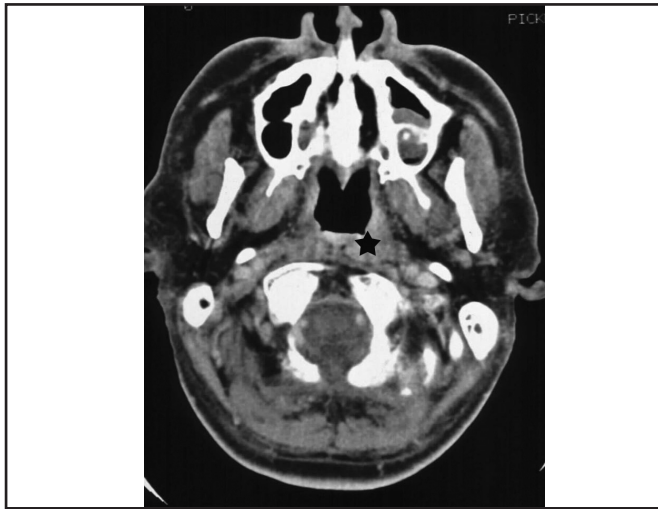

Fig. 1: CT scan showing recurrent nasopharyngeal tumor (rT1 N0 M0) in the left nasopharynx of Case study 1.

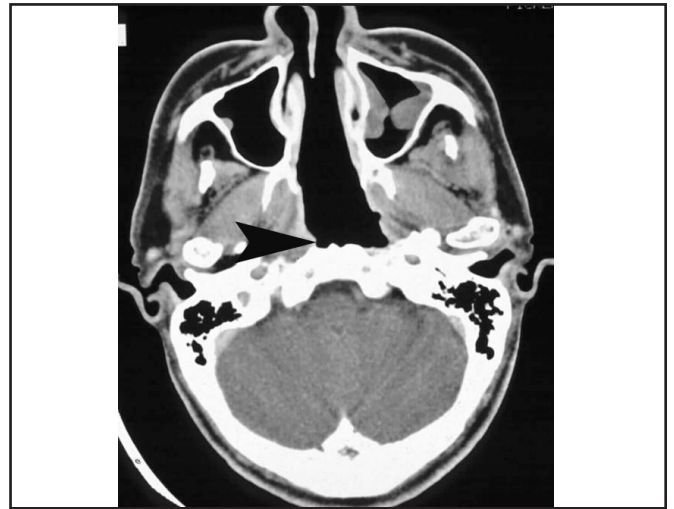

Fig. 2: Post-operative CT scan of Case study 1. The posterior wall (arrow) has been resected down to bone and the left Eustachian tube has been transected at the torus tubarius.

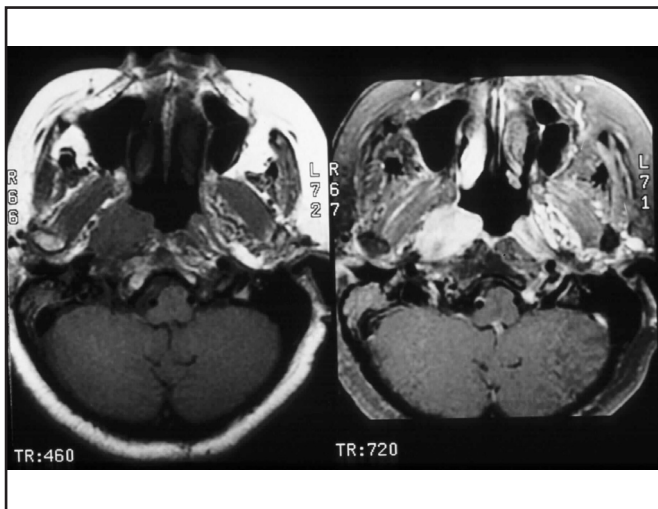


Fig. 3: Pre-operative MRI scans showing invasive adenocarcinoma in the right nasopharynx of Case study 2. Note the infiltration into the prevertebral muscle planes and right retropharyngeal space with displacement of the carotid sheath posteriorly.

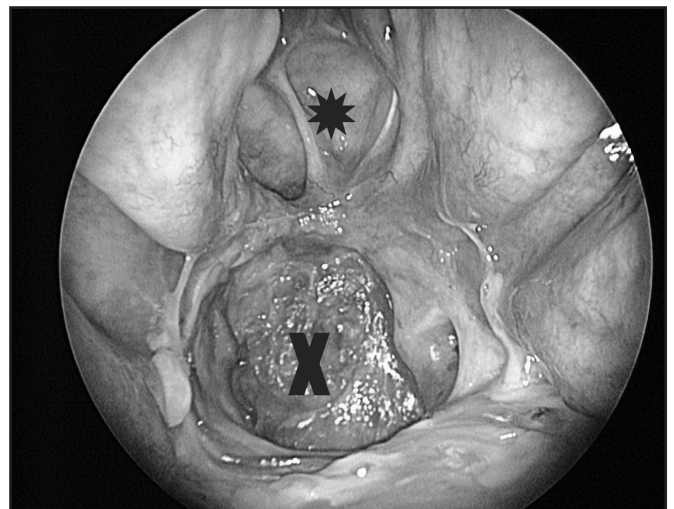


Fig. 4: Endoscopic view of the nasopharynx after nasopharyngectomy. The asterisk (\*) marks the opened sphenoid sinuses and X marks the nasopharynx. The sphenoid sinus floor or nasopharynx roof has been removed and is almost flush with the clivus and posterior nasopharyngeal wall.

## DISCUSSION

Primary tumors of the nasopharynx are rare. Vascular tumors accounted for about half of the cases in a 35-year review of benign nonepithelial pathologies of the nasopharynx<sup>10</sup>. The most common primary benign neoplasm of the nasopharynx is juvenile nasopharyngeal angiofibroma (JNA) and less commonly salivary gland tumors<sup>11</sup>. Among primary malignant neoplasm of the nasopharynx, nasopharyngeal carcinoma (NPC) is by far the commonest<sup>12</sup>.

Management of primary nasopharyngeal tumors (except for NPC) consists of complete surgical extirpation. The prognosis largely depends on the histologic type, grade and stage of disease. Local control rate of such disease may be significantly improved by the addition of postoperative radiotherapy<sup>13</sup>. Role of surgery for NPC at the primary site is limited to salvage surgery for recurrence or residual disease post radiation or chemoradiation. Traditionally, open approaches have been advocated for NPC<sup>6</sup> and JNAs<sup>14,15</sup>. However, these approaches either offer limited access to the nasopharynx or entail significant risk of morbidity eg. oronasal fistula, trismus, cosmetic deformity.

With the advancement of endoscopic techniques, more complex intranasal pathology, including CSF leaks<sup>16</sup> and optic nerve decompression<sup>17</sup> can now be managed strictly endoscopically. These advances have also been successfully utilized in both benign and malignant sinonasal neoplasms with acceptable morbidity and mortality<sup>7, 18, 19</sup>.

Transnasal endoscopic resection of lesions involving or arising from the nasopharynx obviates the need for extensive soft tissue and bony mobilization. This approach is increasingly advocated for both JNAs<sup>20,21</sup> and in recurrent NPC salvage surgery<sup>22,23,24</sup>. In our experience, endoscopic resection is suitable for a variety of pathologies. The endoscope provides excellent visualization in terms of magnification and illumination. This is in contrast to open surgery where the view is likened to a cone, with limited visualization and illumination of the surgical field. The ability of angled endoscopes to look 'around' corners offers unparalleled visualization and definition of tumor margins and surrounding anatomy.

It has been stated that the anatomical limits of this approach is invasion into the clivus superoposteriorly, the pharyngobasilar fascia laterally and paranasal sinuses anteriorly<sup>22</sup>. Even with involvement of these areas, complete tumour resection is possible with the aid of new instrumentation, for instance, high speed drills for clival resection or the transpterygoid approach. These patients would require adjuvant treatment for malignant disease.

The greatest risk in endoscopic nasopharyngectomy is to the internal carotid artery (ICA). In our two early cases described above, proximal control was obtained through the neck and the ICAs were traced to the skull base for protection with malleable retractors. In subsequent cases, with image guidance, we did not perform the neck incision for ICA control. The advent of advanced navigation software like CTMR fusion and three dimensional CT angiogram has increased our level of confidence in image guidance to avoid the ICA intra-operatively<sup>25,26</sup>.

## CONCLUSION

In our small series of long term follow up for endoscopic nasopharyngectomy patients, the results have been comparable to open surgery but with none of the morbidity. This approach is a viable alternative to the traditional techniques and offers better visualization, cosmesis and safety with image guidance.

## REFERENCES

- Goffart Y, Jorissen M, Daele J, *et al.* Minimally invasive endoscopic management of malignant sinonasal tumours. *Acta Otorhinolaryngol Belg* 2000; 54: 221-32.
- Lund V, Howard DJ, Wei WI. Endoscopic resection of malignant tumors of the nose and sinuses. *Am J Rhinol* 2007; 21: 89-94.
- Bolger WE. Endoscopic transpterygoid approach to the lateral sphenoid recess: surgical approach and clinical experience. *Otolaryngol Head Neck Surg* 2005; 133: 20-6.
- Batra PS, Lanza DC. Endoscopic power-assisted orbital exenteration. *Am J Rhinol* 2005; 19: 297-301. Chen MK, Lai JC, Chang CC, Liu MT. Minimally invasive endoscopic nasopharyngectomy in the treatment of recurrent T1-2a nasopharyngeal carcinoma. *Laryngoscope* 2007; 117: 894-6.
- Pirris SM, Pollack IF, Snyderman CH, *et al.* Corridor surgery: the current paradigm for skull base surgery. *Childs Nerv Syst* 2007; 23: 377-84.
- Wei WI, Chiu MH, Lam KHea. Surgical Resection for Nasopharynx Cancer. *Head Neck* 1993; 3: 465-78.
- Fee WE Jr, Gilmer PA, Goffinet DR. Surgical management of recurrent nasopharyngeal carcinoma after radiation failure at the primary site. *Laryngoscope* 1988; 98: 1220-6.
- Fisch U. The infratemporal fossa approach for nasopharyngeal tumors. *Laryngoscope* 1983; 93: 36-44.
- Wei WI, Ho CM, Yuen PW, Fung CF, Sham JS, Lam KH. Maxillary swing approach for resection of tumors in and around the nasopharynx. *Arch Otolaryngol Head Neck Surg* 1995; 121: 638-42.
- Fu YS, Perzin KH. Non-epithelial tumors of the nasal cavity, paranasal sinuses, and nasopharynx: A clinicopathologic study I. General features and vascular tumors. *Cancer* 1974; 33: 1275-88.
- Gnepp DR. Diagnostic surgical pathology of the head and neck. In: *Anomymous Philadelphia: WB Saunders*, 2001; 96.
- Shanmugaratnam K, Chan SH, de-The G, *et al.* Histopathology of nasopharyngeal carcinoma: correlations with epidemiology, survival rates and other biological characteristics. *Cancer* 1979; 44: 1029-44.
- Miller RH, Calcaterra TC. Adenoid cystic carcinoma of the nose, paranasal sinuses, and palate. *Arch Otolaryngol* 1980; 106: 424-6.
- Radkowski D, McGill T, Healy GB, *et al.* Angiofibroma. Changes in staging and treatment. *Arch Otolaryngol Head Neck Surg* 1996; 122: 122-9.
- Tandon DA, Bahadur S, Kacker SK, *et al.* Nasopharyngeal angiofibroma: (a nine-year experience). *J Laryngol Otol* 1988; 102: 805-9.
- Lanza DC, O'Brien DA, Kennedy DW. Endoscopic repair of cerebrospinal fluid fistulae and encephaloceles. *Laryngoscope* 1996; 106: 1119-25.
- Nishizawa S, Yokota N, Yokoyama T, *et al.* Prevention of postoperative complications in skull base surgery for nasal or paranasal sinus carcinoma invading the skull base. *J Clin Neurosci* 2001; 8 Suppl 1: 67-70.
- Dulguerov P, Jacobsen MS, Allal AS, *et al.* Nasal and paranasal sinus carcinoma: are we making progress? A series of 220 patients and a systematic review. *Cancer* 2001; 92: 3012-29.
- Yuen AP, Fung CF, Hung KN. Endoscopic cranionasal resection of anterior skull base tumor. *Am J Otolaryngol* 1997; 18: 431-3.
- Carrau RL, Snyderman CH, Kassam AB, *et al.* Endoscopic and endoscopic-assisted surgery for juvenile angiofibroma. *Laryngoscope* 2001; 111: 483-7.
- Kamel RH. Transnasal endoscopic surgery in juvenile nasopharyngeal angiofibroma. *J Laryngol Otol* 1996; 110: 962-8.
- Yoshizaki T, Wakisaka N, Muroho S, *et al.* Endoscopic nasopharyngectomy for patients with recurrent nasopharyngeal carcinoma at the primary site. *Laryngoscope* 2005; 115: 1517-9.
- Chen MK, Lai JC, Chang CC, *et al.* Minimally invasive endoscopic nasopharyngectomy in the treatment of recurrent T1-2a nasopharyngeal carcinoma. *Laryngoscope* 2007; 117(5): 894-6.
- Roh JL, Park CI. Transseptal laser resection of recurrent carcinoma confined to the nasopharynx. *Laryngoscope* 2006; 116: 839-41.
- Leong JL, Batra PS, Citardi MJ. CT-MR image fusion for the management of skull base lesions. *Otolaryngol Head Neck Surg* 2006; 134: 868-76.
- Leong JL, Batra PS, Citardi MJ. Three-dimensional computed tomography angiography of the internal carotid artery for preoperative evaluation of sinonasal lesions and intraoperative surgical navigation. *Laryngoscope* 2005; 115: 1618-23.