

Triple Primary Cancers of the Larynx, Lung and Thyroid Presenting in One Patient

F R W Iqbal, MRCS*, A Sani, FRCS*, B S Gendeh, MS ORL-HNS**, I Aireen, MBChB*

*Departments of Otorhinolaryngology, **Histopathology, Faculty of Medicine, Universiti Kebangsaan Malaysia, Jalan Yaacob Latiff, 56000 Kuala Lumpur, Malaysia

SUMMARY

Patients with multiple malignant primary tumours are often described, based on their chronology of presentation, as *simultaneous, synchronous or metachronous* tumours. Lung malignancies presenting in association with head and neck tumours are well documented while there have been small series of thyroid synchronous cancers presenting with laryngeal lesions in literature. No cases, to our knowledge, have been reported in literature of a single patient with all three laryngeal, lung and thyroid malignancies. We report one such case of a 71 year-old Chinese man who had undergone a total laryngectomy for a recurrent cancer of the larynx only to be found to have tumours of the lung and thyroid in the post-operative period and he eventually died of post-operative complications. We also discuss screening for lung and thyroid malignancies in patients with head and neck squamous cell carcinoma (SCC).

KEY WORDS:

Synchronous tumours, Lung screening, Multiple tumours

INTRODUCTION

Patients with multiple malignant primary tumours are often described, based on their chronology of presentation, as *simultaneous, synchronous or metachronous* tumours. It is well known that *synchronous* tumours are defined as malignancies presenting within six months of the diagnosis of the index tumour, and *metachronous* tumours are those presenting more than six months after the diagnosis of the index tumour. Tumours presenting at the same time in the initial examination are classified as *simultaneous* tumours and this term has been more recently introduced¹. Lung malignancies presenting in association with head and neck tumours are well documented while there have been small series of thyroid synchronous cancers presenting with laryngeal lesions in literature. However, patients presenting with all three laryngeal, lung and thyroid malignancies are perhaps without precedence in literature.

CASE REPORT

A 71 year-old Chinese man presented to the ENT clinic in October, 2006 with a one-month history of hoarseness and shortness of breath on exertion. He had previously been diagnosed in 2004 to have a moderately differentiated T_{1b} N₀ M_x glottic squamous cell carcinoma (SCC) and had been treated in June of the same year with 50 fractions of

radiotherapy. At that time, the tumour involved the anterior third of both vocal cords and the anterior commissures. He was an ex-smoker of 20 years with a known history of hypertension, chronic renal failure and previous TB of the prostate. On examination under anaesthesia, there were adhesions involving the anterior commissures with no evidence of tumour. A laser adhesiolysis and "Key Hole" excision was made on the vocal cords and the patient's symptoms improved. However, on follow-up in clinic three months later, there was evidence of recurrence of the tumour on the right vocal cord anteriorly and biopsy showed recurrent moderately differentiated SCC. Both vocal cords were mobile. He then had laser ablation of the tumour a month later.

On follow-up, the patient returned with worsening hoarseness and dysphagia and the right vocal cord tumour had again recurred but this time the vocal cords were fixed. A CT scan of the neck showed an enhancing tumour involving both vocal cords and eroding the thyroid cartilage. There was no evidence of neck node metastases. He was admitted in March 2007 for a total laryngectomy. A pre-operative chest X-ray (CXR) showed mildly inflated lungs with no evidence of tumour or metastases. Intraoperatively, the left thyroid lobe was found to be abnormally firm hence a left hemithyroidectomy was performed together with the total laryngectomy. Histology later confirmed the laryngeal tumour to be a well-differentiated SCC but interestingly the left thyroid contained a focus of occult sclerosing papillary carcinoma. During the post-operative period, he developed nosocomial pneumonia which did not respond well to antibiotics as well as a non-ST elevation Myocardial Infarction (NSTEMI) and worsening renal function. In view of the persistent chest infection, a bronchoscopy was performed and a lesion in the left bronchus was found obstructing the left upper lobe. A biopsy of this lesion proved to be a non-small cell carcinoma suggestive of an adenocarcinoma of the bronchus. The patient then deteriorated into multi-organ failure and passed away on post-operative day 32.

DISCUSSION

Thus far, based on our literature search, there has been no reported case of a patient with triple primary malignancies consisting a combination of pulmonary, laryngeal and thyroid lesions either simultaneously or in sequence. Based on the criteria described earlier, given that the initial

This article was accepted: 10 November 2008

Corresponding Author: Iqbal Farim Bin Rizal Wong, Department of Otorhinolaryngology, Faculty of Medicine, University Kebangsaan Malaysia, Jalan Yaacob Latiff, 56000 Kuala Lumpur Email: iqbal_rizal@yahoo.co.uk

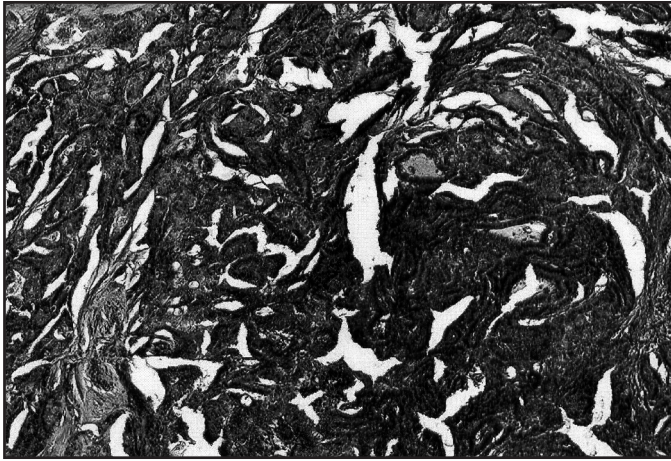


Fig. 1: (H&E x4): Section the thyroid shows a focus of occult sclerosing papillary carcinoma displaying papillary projections lined by thyroid follicular epithelioid cells with clear nuclei and occasional grooving

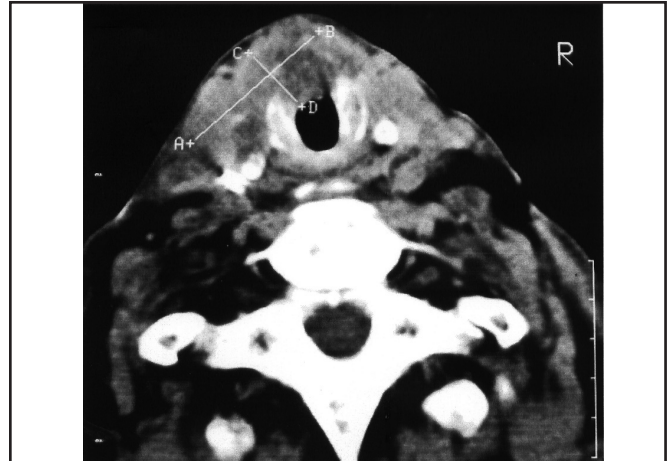


Fig. 2: Pre-operative CT scan of the neck illustrating the laryngeal mass involving both vocal cords and eroding the thyroid cartilage

diagnosis of laryngeal cancer in the reported case was made in 2004 and that the other two malignancies, the lung and thyroid, was diagnosed in 2007 when the laryngeal lesion had recurred, the latter two cancers should be described as metachronous tumours. The thyroid and pulmonary lesions, in relation to one other, would be simultaneous tumours.

Second malignancies are fairly common for patients with laryngeal cancer and the high propensity for these patients to develop second malignancies has been long recognised¹. The majority of these second tumours develop in the upper aerodigestive tract with lung cancer consistently the most frequently diagnosed. This is not surprising as these tumours have common predisposing factors such as cigarette smoking¹. Second thyroid primary tumours are less common but have previously been reported. Resta *et al* reported eight cases of synchronous head and neck squamous cell carcinoma (SCC) and occult thyroid carcinoma, and in 6 of them the SCC was in the larynx². Pitman *et al* reported seven cases, and in four of them the SCC was in the larynx³. It has also been reported that autopsy studies have found that occult thyroid carcinoma has a 6% to 35% general prevalence rate. Despite the incidences reported of lung and thyroid cancers individually presenting associated with laryngeal lesions, to our knowledge, there has not been a documented case in which all three cancers presented in the same patient, metachronously or synchronously.

There are hypotheses offered regarding the propensity of the upper aerodigestive tract to develop second cancers. Slaughter has proposed the concept of 'condemned mucosa' developing after chronic carcinogen exposure leading to 'field cancerization' of the aerodigestive tract⁴. Carey has countered that 'field cancerization' may be 'monoclonal' with second tumours developing from micrometastatic tumour deposits breaking off from the original primary and growing in other subsites of the aerodigestive tract⁵.

The other point of discussion in the reported case is pre-operative screening for lung and thyroid lesions. In our

centre, we would routinely order a chest X-ray for all head and neck cancer patients about to undergo surgery and if there is any suggestion of malignancy, primary or secondary, a CT scan of the thorax would be done with a CT-guided biopsy if needed. A finding of malignancy in the lung would, of course, change our management in this case but the plain chest radiograph was clear. From literature, the general conclusion is that for early malignancy of the head and neck, that is T1 or T2 tumours, a plain Chest X-ray would be sufficient as a screening tool for lung metastases. For more advanced tumours (T3 or T4 and/or N positive neck), a CT scan of the thorax is recommended.

Second primary cancers in patients with head and neck malignancies are relatively common especially second pulmonary primaries. However, a triple presentation of laryngeal, lung and thyroid malignancies in the same patient is very rare and possibly unique. Routine screening methods to detect these second tumours are still a matter of debate. Although in the reported case the chest X-ray missed the lung lesion, from our experience at our centre, this is an isolated case and we would continue to screen for lung lesions with plain chest radiographs especially in T1 or T2 laryngeal tumours. All our head and neck cancer patients have a CT scan of the neck and a thyroid lesion, if present, is likely to be detected. Again, the reported case is exceptional.

REFERENCES

1. Kuriakose MA, Loree TR, Rubinfeld A, *et al*. Simultaneously presenting head and neck and lung cancer: A diagnostic and treatment dilemma. *Laryngoscope* Jan 2002; 112(1): 120-23.
2. Resta L, Piscitelli D, Fiore M, *et al*. Incidental metastases of well-differentiated thyroid carcinoma in lymph nodes of patients with squamous cell head and neck cancer: eight cases with a review of the literature. *Eur Arch Otorhinolaryngol*. 2004; 261: 473-78.
3. Pitman KT, Johnson J, Myers E. Papillary thyroid carcinoma associated with squamous cell carcinoma of the head and neck: significance and treatment. *Am J Otolaryngol*. 1996; 17: 190-96.
4. Slaughter DP, Southwick HW, Smejkal W. Field cancerization in oral stratified squamous epithelium. *Cancer* 1953; 6: 963-8.
5. Carey T. Field cancerization: are multiple primaries monoclonal or polyclonal? *Ann Med* 1996; 28: 183-8.