

# Angiokeratoma Corporis Diffusum

F B B Yap, MRCP, M Pubalan, MRCP

Department of Dermatology, Sarawak General Hospital, Jalan Hospital, 93586 Kuching, Sarawak

## SUMMARY

Angiokeratoma is a dark violaceous keratotic papule which can be solitary or multiple. Generalised systemic angiokeratoma constitute angiokeratoma corporis diffusum, a rare X-linked recessive inborn error of glycosphingolipid metabolism due to deficiency of alpha galactosidase A. Patients with this disease have premature death due to the vascular complications. A case of possible Fabry's disease is presented.

## KEY WORDS:

*Fabry's disease, Angiokeratoma, Glycosphingolipid, Alpha galactosidase A*

## INTRODUCTION

Angiokeratoma corporis diffusum of Fabry's disease is a rare X-linked recessive lysosomal storage disease. A case of possible Fabry's disease in a 24 year old Iban man is presented.

## CASE REPORT

A 24 year old Iban man was referred for multiple papular lesions on the scrotum, penis, buttock and both thighs and legs since childhood. He also had gum bleeding, occasional episodic acral paraesthesia and bilateral pedal oedema for the past few months. There was no history of anhidrosis, angina, visual impairment, abdominal pain, bone pain, fever or reduced effort tolerance. He is mentally challenged and currently unemployed. He is independent on his activities of

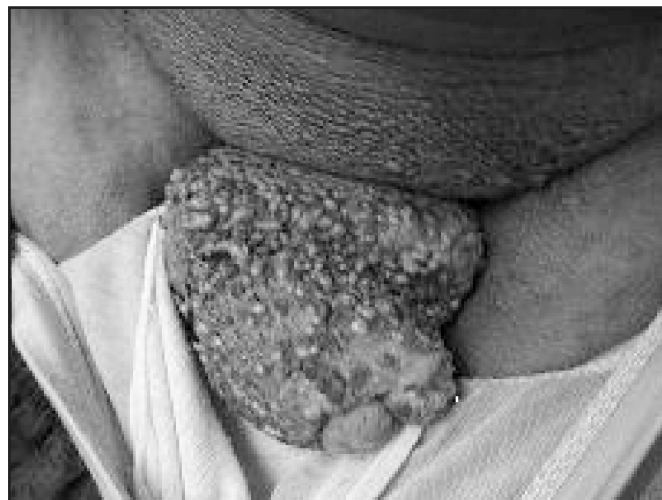

Fig. 1: Multiple angiokeratomas seen on the scrotum and penis.

daily living. He is the only child of a non-consanguineous parent. There was no family history of similar skin lesions. Examination revealed a hyperpigmented healthy man, significantly shorter than his parent. He has bilateral ptosis, gum hypertrophy and bad dentition. Multiple reddish, violaceous and blackish hyperkeratotic papules were noted on the scrotum, penis, buttock, thighs and legs (Figure 1). Bilateral chronic lymphostasis of the lower limbs was noted.

Skin biopsy of the papular lesion showed cavernous channels in the papillary dermis with associated irregular epidermal acanthosis and elongated rete ridges enclosing the vascular channels. This was consistent with angiokeratoma (Figure 2).

All his blood investigations were normal. His chest radiograph showed normal heart shadow and clear lung fields. He had no proteinuria. Unfortunately, alpha galactosidase level was not measured due to lack of this investigation in our laboratory. The investigation was not performed elsewhere due to the patient's financial constraint.

Based on the clinical features and histopathological findings, he was diagnosed to have angiokeratoma corporis diffusum or Fabry's disease.

Combination of superpotent topical corticosteroid (Clobetasol) ointment under occlusion and leg elevation improved the lower limb lymphostasis. No intervention was done for the angiokeratomas.

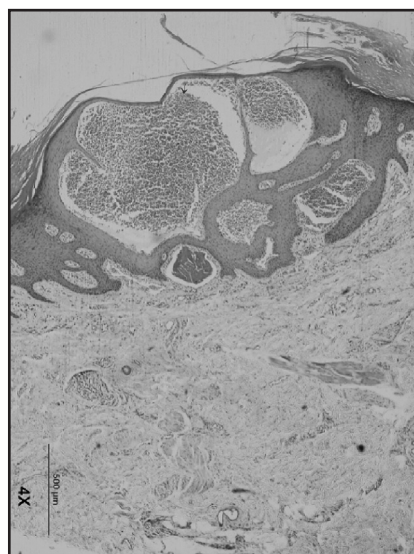


Fig. 2: Cavernous channels in the papillary dermis enclosed by irregular epidermal acanthosis and elongated rete ridges.

This article was accepted: 4 August 2008

Corresponding Author: Felix Yap Boon Bin, Department of Dermatology, Sarawak General Hospital, Jalan Hospital, 93586 Kuching, Sarawak  
Email: woodzlamp@yahoo.com

## DISCUSSION

Angiokeratoma is a dark violaceous to black, often keratotic papule that is hard upon palpation and cannot be compressed by diascopy<sup>1</sup>. Angiokeratoma can appear as solitary or multiple lesions. Localised scrotal angiokeratomas is termed angiokeratoma of Fordyce while localised bilateral angiokeratoma on the elbow, knees and hands is termed angiokeratoma of Mibelli. Generalised systemic angiokeratomas constitute angiokeratoma corporis diffusum or Fabry's disease.

Fabry's disease is an X-linked recessive inborn error of glycosphingolipid metabolism due to deficiency of the lysosomal enzyme alpha galactosidase A<sup>1,2</sup>. More than 200 mutations were identified in the long arm of chromosome X (Xq22.1)<sup>3</sup>. Missense mutation predicting a leucine to proline substitution in the alpha galactosidase gene was detected in a Chinese family<sup>4</sup>. It is a rare disease in Orientals<sup>4</sup>.

The deposition of glycosphingolipids ceramide trihexoside occurs in the endothelium, fibroblasts, pericytes, heart, kidneys and autonomic nervous system giving rise to the symptoms and signs of Fabry's disease<sup>2</sup>. Galanos *et al* showed that episodic acroparaesthesia, corneal verticillata, anhidrosis, angiokeratoma, renal disease, cataract, ischaemic heart disease, mitral valve disease and premature cerebrovascular disease were seen in Australian patients in that order of frequency<sup>5</sup>. This patient presented with acroparaesthesia, mental subnormality, lymphostasis and angiokeratoma.

The angiokeratomas in Fabry's disease are noted in 93% of homozygotes and 13% of heterozygotes<sup>5</sup>. They are caused by glycosphingolipid deposits in the cutaneous endothelium that causes swelling and localised increase in pressure<sup>3</sup>. They are commonly seen in the lower half of the body namely lower abdomen, genitalia, buttock and lower limbs. It can also be seen in the lips. Histologically, there are dilated capillaries in the papillary dermis resulting in endothelium lined lacunae filled with blood and surrounded by acanthotic hyperkeratotic epidermis<sup>2</sup>. Electron microscopy reveals characteristic electron dense 'Zebra' bodies in the endothelial cells, fibroblasts and pericytes<sup>2</sup>. This patient presented with typical angiokeratoma confirmed histologically.

Diagnosis is confirmed by finding low levels of alpha galactosidase A in the leukocytes, serum, tears and skin fibroblasts. It was unfortunate that enzyme level was not done in this case. However, based on the classical signs and symptoms, he was diagnosed to have Fabry's disease.

Patients with Fabry's disease have high incidence of thrombosis. They present with premature myocardial infarction and cerebrovascular accidents. Deaths are usually due to renal, cardiac and cerebrovascular complications of vascular disease. As these complications usually occur during the fourth and fifth decades of life, we will be vigilant in looking for these complications in this patient.

Treatment is usually symptomatic. Carbamazepine is used for neuropathic pain, laser therapy for angiokeratomas, antiplatelets for cerebrovascular accidents, antihypertensive for renal disease and renal replacement therapy for end stage renal failure<sup>3</sup>. Enzyme replacement therapy is now available, mainly in research centres. It is safe and effective but the long term outcome is uncertain. This patient had symptomatic treatment for his lymphoedema. No enzyme replacement was given because it was not available in our institution.

In conclusion, Fabry's disease is a rare condition. A high index of suspicion is needed when one encounters angiokeratoma. Patients with Fabry's disease have premature death due to the vascular complications. Treatment is usually symptomatic. Institution of enzyme replacement might alter the progression of this disease.

## REFERENCES

1. Wolff K, Johnson RA, Suurmond D. Angiokeratoma. In: Fitzpatrick's color atlas & synopsis of clinical dermatology. Fifth edition. McGraw Hill, 2005; 194-5.
2. James WD, Berger TG, Elston DM. Angiokeratoma corporis diffusum (Fabry's disease). In: Andrews' diseases of the skin. Clinical dermatology. Tenth edition. Saunders Elsevier, 2006; 538.
3. Martinez NA, Hernandez FJB, Consuegra JC. Fabry's disease: long term study of a family. *Eur J Int Med*; 2004; 15: 210-5.
4. Tse KC, Chan KW, Tin VP. Clinical features and genetic analysis of a Chinese kindred with Fabry's disease. *Nephrol Dial Transplant* 2003; 18: 182-6.
5. Galanos J, Nicholls K, Grigg L, Kiers L, Crawford A, Becker G. Clinical features of Fabry's disease in Australian patients. *Intern Med J* 2002; 32: 575-84.