

Fracture Synthetic Tracheostomy Tube: An ENT Emergency

S Shashinder, MS (ORL)*, I P Tang, MD*, S Kuljit, MS(ORL)*, K Muthu, FRCS**, K G Gopala, FRCS*, M A Jalaludin, FRCS*

*Department ORL, Faculty of Medicine, University of Malaya, 50630 Kuala Lumpur, **Consultant Otorhinolaryngologist, Arunamary Medical Centre, Klang, Malaysia

SUMMARY

A synthetic tracheostomy tube [non-metallic type] fracturing within three days of insertion is very rare but it could lead to serious complications such as acute asphyxia or sudden death. We report three such cases at our centre. Recommendations are made to closely observe patients on tracheostomy tube in the first seven days post-insertion of the tube.

KEY WORDS:

Synthetic tracheostomy tube, Fracture, Tracheostomy, Foreign body from tracheostomy

INTRODUCTION

Tracheostomy tubes are airway adjuncts to maintain airway, which communicates from the trachea to the atmosphere and are used following an emergency or elective tracheostomy. There are two types of tubes: nonsynthetic types ex. Metallic: silver, zinc and copper and synthetic type ex. portex. Synthetic tubes have two common variants: cuffed and uncuffed. Complications of tracheostomy tubes are many but the occurrence of the tracheostomy tube fracture causing respiratory obstruction or leading to a foreign body in the lungs are relatively rare¹.

We report three cases of tracheostomy tube fracture all of which occurred in the same month. All three cases fractured at day three post insertion.

CASE REPORTS

We report three cases of synthetic tracheostomy tubes fracturing from their neck plates and shall present them as one case report as the details of the events were almost similar in all three. These patients needed prolong ventilation because of poor respiratory effort secondary to injury to the spine and thus had elective tracheostomies.

The tracheostomies were done under general anesthesia with skin incision made horizontally two fingers above the suprasternal notch and trachea was opened at the second and third tracheal ring. The intra-operative procedure was uneventful. The cuffs of the tracheostomy tubes were tested preoperatively and they were all intact and functioning well.

Post operatively the patients were on artificial assisted respiration and in all three cases the first and second post-operative day was reported as uneventful.

However, on the third post operative day there was a sudden trigger of the alarm on the ventilator indicating a hypoxic event. On close examination, the tracheostomy tube had completely disconnected or fractured from the neck plate of the tube thus causing an air-leak and subsequently a hypoxic event. The nursing staff informed the otolaryngology and intensive care unit doctor on call and the tube was replaced promptly. All the three patients were saved from a hypoxic event as early detection and replacement of the tube was carried out. However in all the three cases there was no inhalation of foreign body into the tracheo-bronchial tree as the lower part of the tube was anchored to the cuff (Figure 1). This allowed removal of the detached part of the tube that was left in the trachea by continuous slow traction of the part that was attached to cuff. The hospital management on advice of the otolaryngology department further investigated the matter and found that all tubes used had not passed their expiry date. All tracheostomies tubes of the same batch were recall and the manufacturer were called in for further investigation of these tubes.

DISCUSSION

Tracheostomy tubes fracture is common in the non synthetic tubes or metal tubes as they have poor corrosive resistance particularly when exposed to tracheobronchial secretions for a prolong period. However in synthetic tubes this problem seems to be less when compared to the non synthetic ones.

We found that there were reported cases in the literature that documented synthetic tracheostomy tube fracture at the junction of the tube and neck plates². In all these cases the duration of wear was between six months to seven years². However in our three patients, the duration was just three days and most probable cause could be due to defects in manufacture process.

Fracture defects are commonly seen in synthetic tubes particularly when the joints of the tube and neck plate are articulated but in recent times the joints have been replaced with direct adhesion of tube to the neck plates³. We believe that the adhesion with glue could be a cause of this defect in our three cases. The author further postulate that this phenomena is due to the heat and humidity of our tropical climate which cause the adhesive material used in this tracheostomy tube to give way.

Alvi A *et al*³ reported in their series of case reports that the patients had duration of tube wear between six months to

This article was accepted: 22 May 2008

*Corresponding Author: Tang Ing Ping, Otorhinolaryngology Department, Faculty of Medicine, University of Malaya, 50603 Kuala Lumpur, Malaysia
Email: ingptang@yahoo.com*

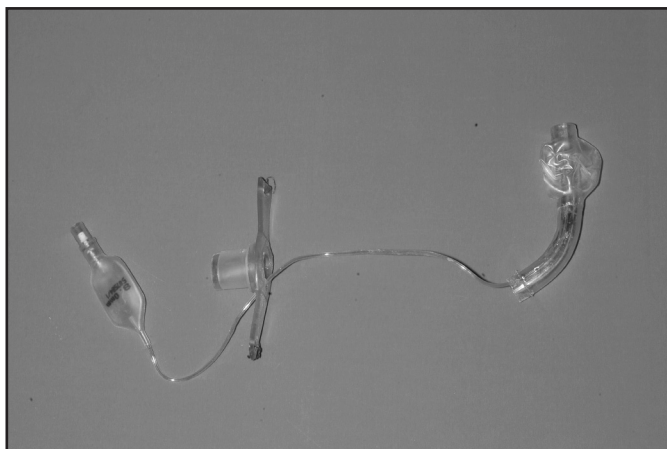


Fig. 1: Tracheostomy tube disconnected from the neck with the lower part being attached to the cuff.

seven years and none of them had a fracture less than one week. In all the cases the most probably cause was documented as unknown and four cases as mechanical defect. However, the tubes with a mechanical defect fractured only after six months of wear. The commonest site of fracture was the neck plate but there have been reports of a synthetic tracheostomy tube being fractured at the fenestration site.

CONCLUSION

Synthetic tracheostomy tubes are prone to fracture at the neck plates if there is a manufacture defect and this condition is very rare. In view of this the tracheostomies tubes should be examined by the surgeon-concerned and/or intensive care provider, pre operatively for the first one week or at least up to the time the tube is replaced with a non-cuff tube. Faulty tracheostomy tubes should be replaced by a new consignment and the manufacturer should be immediately informed for remedial action. We believe this event could be due to poor adhesive glue at the tube and neck plate. The cause of the fracture is not related to prolong wear as these three cases occurred within three days. Hence the surgeon and intensive care provider should be aware of this occurrence in a patient with a synthetic tracheostomy tube during first week of tube insertion.

REFERENCES

1. Gana PN, Takwoingi YM. Fractured tracheostomy tubes in the tracheobronchial tree of a child. *Int J Pediatr Otorhinolaryngol* 2000; 53(1): 45-8.
2. Krempl GA, Otto RA. Fracture of synthetic tracheostomy tube resulting in a tracheobronchial airway foreign body. *South Med J* 1999; 92(5): 526-8.
3. Alvi A, Zahtz GD. Fracture of a synthetic fenestrated tracheostomy tube: case report and review of literature. *Am J Otolaryngol* 1994; 15(1): 63-7.