

# Endoscopic Orbital Decompression for Graves' Ophthalmopathy

I P Tang, MD\*, N Prepageran, FRCSEdin(ORL), S Shashinder, MS

Otorhinolaryngology Department, Faculty of Medicine, University of Malaya, 50630 Kuala Lumpur

## SUMMARY

We report a male patient of Graves' Disease with bilateral exophthalmos who had undergone bilateral transnasal endoscopic orbital decompression with subsequent improvement of 3mm in orbital proptosis bilaterally without any complications. Transnasal endoscopic orbital decompression is recommended as an alternative to traditional decompression techniques especially for purely cosmetic reasons.

## KEY WORDS:

*Graves' Ophthalmopathy, Endoscopic orbital decompression*

## INTRODUCTION

Ocular involvement is present in 10 to 20 percent of patients with Graves' disease and contributes significantly to ophthalmologic morbidity in 2% to 5% of patients. It is an autoimmune process resulting from the deposit of antithyroglobulin immune complexes at extraocular muscles and fat which produces edema and fibrosis. This increase in the retro-orbital pressure causes proptosis<sup>1</sup>. The sequelae are both functional and cosmetic and relate to the volumetric constraints placed on the ocular contents by the bony framework of orbits. The progressive nature of this disease ultimately manifests itself in several ophthalmologic consequences including lid lag and proptosis, ectropion, exposure keratitis, strabismus, diplopia, compressive optic neuropathy, alterations in visual acuity and potentially blindness<sup>2</sup>. High dose corticosteroids are administered to treat ophthalmopathy or as the first line management. However, if this fails then surgical intervention is indicated. The benefit of radiation therapy for the control of ophthalmopathy has not been supported in any randomized controlled trial.

We report a case of Graves' Disease with bilateral exophthalmos who had undergone bilateral transnasal endoscopic orbital decompression with subsequent improvement of 3mm in orbital proptosis bilaterally without any complications.

## CASE REPORT

A 31-year-old Indian gentleman was diagnosed to have Graves' disease in early June 2002. He had diffuse goitre with hyperthyroidism. His thyrotoxicosis was treated medically initially but failed and then proceeded with total

thyroidectomy. He also noted the onset of mild proptosis that progressed over the years which resulting in blurring of vision bilaterally. However, he didn't complain of diplopia or other eye symptoms. Eye examination revealed visual acuity 6/9 in right eye and 6/6 in left eye. Colour vision was intact. Visual field examination revealed early paracentral loss in the right eye and normal in the left eye. Extraocular movements were full in both eyes. Hertel exophthalmometer measurements revealed 26mm of proptosis in right eye and 25mm of proptosis in left eye. A computed tomographic scan of the orbits demonstrated bilateral proptosis more in the right eye than left eye with thickening of superior, inferior and medial recti muscles. The optic nerves appeared intact bilaterally (Figure 1).

He requested for surgical intervention to reduce the proptosis. Bilateral transnasal endoscopic orbital decompressions were performed under general anaesthesia. An uncinectomy preceded the generous middle meatal antrostomy. The ethmoid air cells were removed from the agar nasi cells to the face of the sphenoid. The air cells adjacent to the frontal recess were preserved. The lamina papyracea was fractured then removed and leaving an anterior bony orbital strut. The medial orbital floor was then fractured inferiorly and removed preserving the infraorbital nerve. The periorbita was incised from posterior to anterior. Pressure was applied to the globe to enhance repositioning of fat and enlarged muscles. Septations in fat were incised superior and inferior to the medial rectus. The middle turbinate was preserved. Adequate nasal packing was done postoperatively.

He recovered uneventful without any complications postoperatively. He was discharged the next day. Post-operatively, his hertel measurements reduced 3mm in both eyes and both visual fields were full (Figure 2). Currently, he is still being followed up in Eye and ENT clinic.

## DISCUSSION

Surgical orbital decompression is a mainstay treatment for Graves' ophthalmopathy after failed with medical treatment. The primary goal of orbital decompression is increase the orbit space to tolerate the increased volume of orbital tissue generated by the autoimmune activation of orbital fibroblast. Prolapse of orbital tissue into the expanded volume results in reduction of proptosis, decreased optic nerve compression or stretch and resolution of most symptoms because of orbital congestion and increased soft tissue volume.<sup>3</sup>

*This article was accepted: 8 January 2008*

*Corresponding Author: Tang Ing Ping, Otorhinolaryngology Department, Faculty of Medicine, University of Malaya, 50630 Kuala Lumpur*

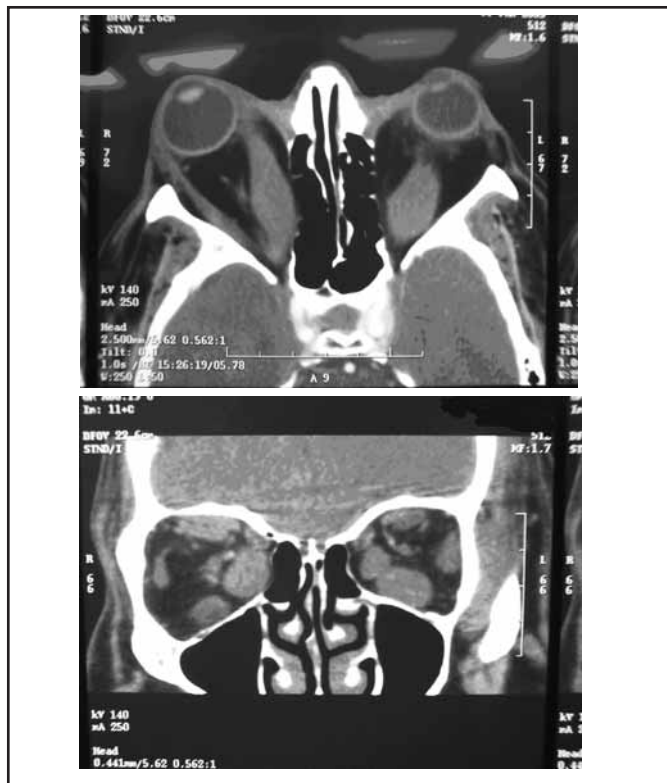

Fig. 1: A computed tomographic scan of the orbits demonstrated bilateral proptosis more in the right eye than left eye with thickening of superior, inferior and medial recti muscles. Axial (up) and coronal (down) views.

Surgical orbital decompression for Graves’ ophthalmopathy has traditionally been performed via transantral approach (The Walsh-Ogura decompression). However, this technique provides poor access to the posterior lamina papyracea and this may be inadequately removed. In addition the fovea ethmoidalis is also approached obliquely making it vulnerable to injury and generous Caldwell-Luc antrostomy results many complications too<sup>1</sup>. The advent of intranasal endoscope has significantly improved anatomic visualization of the nose and paranasal sinuses. This has allowed for a transnasal decompression of the medial and inferior orbital walls that compared well with traditional methods. Endoscopes also permit a maximal posterior orbital decompression at the orbital apex, an area often not fully accessible via transantral routes. This provides optimal decompression of the optic nerve in cases of optic neuropathy. Endoscopic visualization of the medial orbital wall is superior to either the transantral or external ethmoid approaches, thus permitting a more complete medial orbital decompression. The anterior portion of the orbital floor is inaccessible through the maxillary ostium. Thus, a significant anterior buttress of orbital floor remains that supports the globe and it is unusual to see any significant inferior orbital displacement<sup>1</sup>.

Endoscopic orbital decompression was first reported in 1990 with axial proptosis being reduced by a mean of 5.7mm when combined with lateral orbitotomy and 4.7mm when

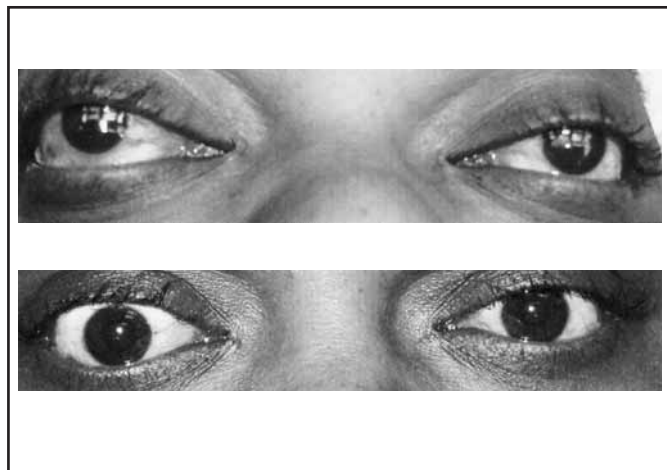


Fig. 2: Pre and Postoperative eyes appearance. Preoperative(up) and Postoperative(down)eyes.  
(Note: Author had obtained consent for this publication.)

decompressed by an endoscopic approach alone. Other series reported mean reductions in proptosis range from 3.0 to 4.7mm<sup>1</sup>. The reduction not much different from the traditional transantral approach. However, endoscopic orbital decompression has significantly reduced postoperative complications compare with transantral approach.

Despite having many advantages, a purely endoscopic approach does have some limitations. It is difficult to remove bone lateral to the inferior orbital nerve or anterior to the middle meatal antrostomy. Decompression of the medial wall and floor only may result in significant medial orbital prolapse. This imbalance may cause diplopia and patients should be counselled about the risk. There may be rare occasions where the severity of the disease is such that the inferior orbital wall and lateral orbital wall need to be completely resected and in such cases, it is well recognized that a combination of an endoscopic and transconjunctival approach may be necessary<sup>1</sup>.

**CONCLUSION**

In conclusion, as techniques for orbital decompression have advanced, the minimal morbidity from surgery has meant that an increased number of patients are now requesting intervention for purely cosmetic reasons<sup>1</sup>. Endoscopic decompression of the medial orbital wall and floor gives reasonable proptosis reduction with minimal morbidity and therefore should be considered as a treatment option.

**REFERENCES**

1. Wee DTH, Carney AS, Thorpe M, Wormald PJ. Endoscopic orbital decompression for Graves’ ophthalmopathy. *J Laryngol Otol* 2002; 116: 6-9.
2. Silver RD, Harrison AR, Goding GS. Combined endoscopic medial and external lateral orbital decompression for progressive thyroid eye disease. *Otolaryngol Head Neck Surg* 2006; 134: 260-66.
3. Kasperbauer JL, Hinkley L. Endoscopic orbital decompression for Graves’ ophthalmopathy. *Am J Rhinology* 2005; 19: 603-6.