

Irreversible Visual Loss and Optic Nerve Dysfunction Associated with Central Retinal Vein Occlusion in Waldenstrom Macroglobulinemia

S A W Fadilah, PhD^{*,**}, M Muhaya, PhD^{***}, I Azlin, BAO^{****}

*Department of Medicine, Faculty of Medicine, Universiti Kebangsaan Malaysia, **Cell Therapy Center, Hospital Universiti Kebangsaan Malaysia, ***Department of Ophthalmology, ****Department of Pathology, Faculty of Medicine, Universiti Kebangsaan Malaysia, Kuala Lumpur, Malaysia

SUMMARY

Irreversible optic nerve dysfunction associated with central retinal vein occlusion (CRVO) is an unusual but important complication of Waldenstrom Macroglobulinemia (WM). Acute visual loss in CRVO is mainly due the severe macular oedema. However, ischaemic optic neuropathy needs to be considered in patients with CRVO when, (i) there is a relative afferent papillary defect and central scotoma, (ii) the visual acuity is not consistent with the retinal pathology, and (iii) the visual defects persisted despite resolution of macular oedema following treatment of the hyperviscosity state. The ischaemic type of CRVO is associated with a poor visual prognosis and the presenting visual acuity has a prognostic role. We report the first description of irreversible unilateral optic nerve damage associated with CRVO in a patient with WM.

KEY WORDS:

Visual loss, Optic nerve, Central retinal vein occlusion, Hyperviscosity, Waldenstrom's macroglobulinaemia

INTRODUCTION

WM is an uncommon B-cell lymphoproliferative disorder characterized by clonal proliferation of lymphocytes that secrete monoclonal IgM¹. IgM proteins are large molecules that are 80% intravascular and can increase serum viscosity significantly. Symptoms usually develop when the serum viscosity is greater than 4 centipoise (NR: 1.4-1.8 cp) and occur at diagnosis in 10-30% of patients¹. Ocular manifestations of WM caused by hyperviscosity usually involve the conjunctiva, cornea and retina². Optic nerve is rarely affected apart from the occurrence of transient optic disc oedema caused by hyperviscosity-related CRVO. To our knowledge, irreversible unilateral optic neuropathy resulting in permanent visual loss has never been associated with WM.

CASE REPORT

A 30-year-old man presented with a two-week history of blurring of vision of his right eye. There was no history of pain, tearing and redness of the eyes. Physical examination revealed pallor, cervical lymphadenopathy and hepatosplenomegaly. Examination of the right eye revealed

visual acuity of perception to light, central scotoma and relative afferent pupillary defect. Visual acuity in the left eye was 6/12. The right eye fundus (Figure 1a) showed diffuse flame shaped retinal haemorrhages, grossly dilated and tortuous veins and pale swollen optic disc. Left eye fundus (Figure 1b) showed dilated tortuous retinal veins and blot haemorrhages in the retinal periphery. Optical coherence tomography of both eyes showed serous detachment of the macular which was more severe in the right eye (Figure 2a,b). These ophthalmic appearances are consistent with right CRVO and left venous stasis retinopathy.

Laboratory investigations at presentation showed haemoglobin of 74 g/L, white cell count $52.9 \times 10^9/L$ (80% atypical lymphocytes), platelet count $130 \times 10^9/L$, IgM-kappa paraprotein of 54.6 g/L in the serum and free kappa light chain (Bence-Jones protein) of 19.8 mg/L in the urine. Bone marrow aspirate showed 70% lymphoplasmacytoid cells that expressed CD19, CD20, CD22 and IgM kappa light chain antigens. These findings are consistent with WM.

The patient was initially managed with two sessions of plasmapheresis to remove the circulating paraprotein and subsequently, he received chemotherapy consisted of fludarabine, cyclophosphamide and rituximab to prevent the paraprotein from re-accumulating. Three weeks later there was almost complete resolution of the retinal haemorrhages and venous engorgement in both eyes. Following two cycles of chemotherapy, there was (i) complete reversal of the retinal and macular abnormalities in both eyes (Figure 2c,d) but (ii) persistent relative afferent pupillary defect, central scotoma and pale optic disc in the right eye (Figure 1c). The visual acuity in the left eye improved to 6/6 as the macular oedema subsided but the right eye vision remained poor. After three cycles of chemotherapy, clinical and laboratory abnormalities had reversed almost completely, however the ophthalmic abnormalities in the right eye persisted.

DISCUSSION

The ocular manifestations of hyperviscosity include congestion of the conjunctival vessels, dilation, segmentation and tortuosity of retinal vessels, retinal haemorrhages and serous retinal detachment². CRVO as the initial presenting

This article was accepted: 29 August 2007

Corresponding Author: Fadilah S Abdul Wahid, Department of Medicine, Faculty of Medicine, Hospital Universiti Kebangsaan Malaysia, Jalan Yaacob Latif, Bandar Tun Razak, 56000 Kuala Lumpur Email: sfadilah@mail.hukm.ukm.my

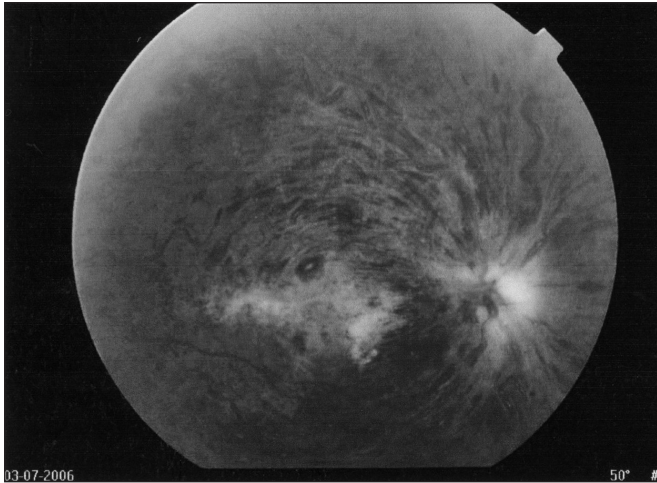


Fig. 1: a) Right fundus at presentation

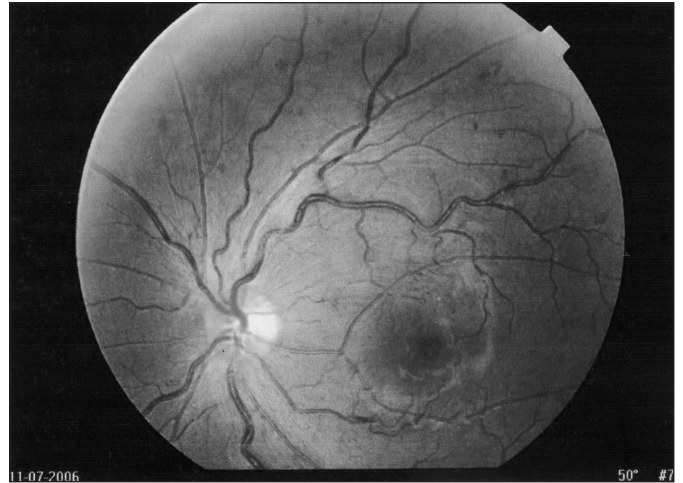

Fig. 1: (b) Left fundus at presentation

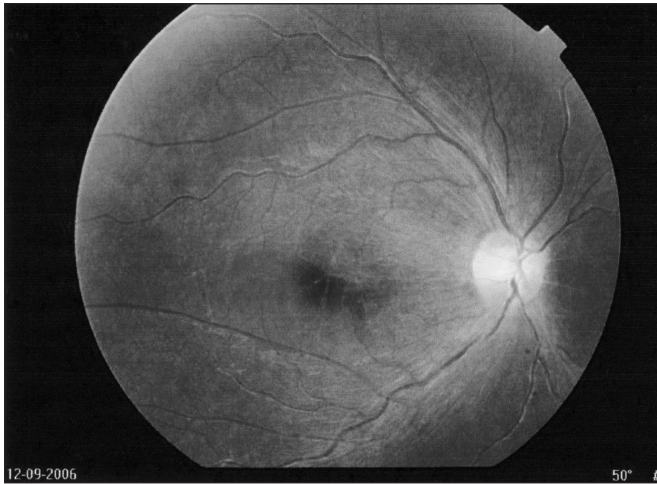

Fig. 1: (c) Right fundus 2 months later
Fundus photograph of the (a) right eye at presentation showing diffuse flame shaped retinal haemorrhages, grossly dilated and tortuous veins and pale and swollen optic disc, (b) left eye at presentation showing dilated tortuous retinal veins and blot haemorrhages in the retinal periphery; and (c) right eye two months later (after plasmapheresis and 2 cycles of chemotherapy) showing resolution of the retinal haemorrhages and venous tortuosity and a pale optic disc

OCT Image

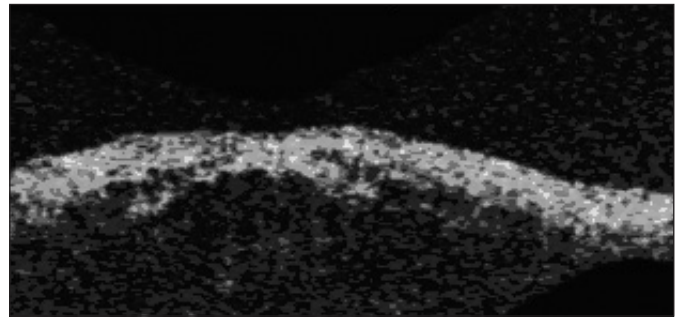


Fig. 2: (a) Right macula at presentation

OCT Image

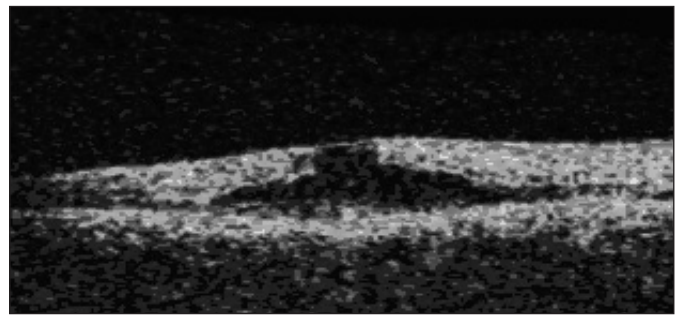


Fig. 2: (b) Left macula at presentation

OCT Image




Fig. 2: (c) Right macula 2 months later

OCT Image

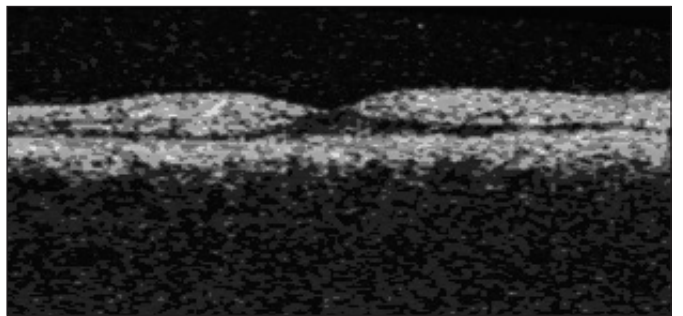


Fig. 2: (d) Left macula 2 months later

Fig. 2: Optical coherence tomography of the macular of the (a) right eye and (b) left eye at presentation showing severe macular oedema; and the (c) right eye and (d) left eye after plasmapheresis and 2 cycles of chemotherapy showing complete resolution of macular oedema.

sign of WM is rare². Acute visual loss in CRVO is mainly due to the severe macular oedema³. Early plasmapheresis to reduce serum viscosity lead to resolution of the macular oedema and restoration of vision in most cases². In our patient, the irreversible visual loss in the right eye is likely due to ischaemic optic neuropathy as the visual acuity of his right eye did not improve despite resolution of the CRVO and macular oedema. This is possibly due to the optic nerve dysfunction, which occurs because of the ischaemic optic neuropathy affecting the optic nerve head circulation as a result of severe hyperviscosity, which may result in stagnant hypoxia to the optic nerve tissue.

The hyperviscosity status in this patient may have contributed to the concomitant occlusion of posterior ciliary arteries and central retinal vein. Additionally, abnormal platelet aggregation and adhesiveness as a result of non-specific coating of by IgM paraprotein could result in formation of bulky clots, promoting the formation of venous thrombosis, including CRVO.

WM remains an incurable disease¹. Therefore, therapy is directed toward prevention and/or palliation of the associated

clinical sequelae of the paraprotein, e.g. hyperviscosity with ocular or neurological disturbances, symptomatic cryoglobulinaemia, myelosuppression or progression to high grade lymphoma. There are no randomised trials to determine the best treatment option; therapy is totally decided based on the age and the aggressiveness of the presentation. Daily plasma exchanges of 3 to 4 L with albumin, rather than plasma, are particularly effective in reducing serum IgM level and serum viscosity¹. Combination chemotherapy may be a reasonable option for young patients with WM presenting with aggressive disease¹.

REFERENCES

1. Rajkumar SV, Dispenzieri A, Kyle RA. Monoclonal gammopathy of undetermined significance, Waldenstrom's macroglobulinaemia, AL amyloidosis, and related plasma cell disorders: diagnosis and treatment. *Mayo Clin Proc* 2006; 81: 693-703.
2. Casares PZ, Gillet DS, Verity DH, Rowson NR. Bilateral simultaneous central retinal vein occlusion (CRVO) caused by Waldenstrom's macroglobulinaemia with acquired Von Willebrand's disease. *Br J Haematol* 2002; 118: 344-47.
3. Abu el-Asrar AM, al Rahaad SA, Abdel Gader AG. Anterior ischaemic optic neuropathy associated with central retinal vein occlusion. *Eye* 2000; 14: 560-62.