

# Chromosome 13q Deletion with Cornelia de Lange Syndrome Phenotype

C T Ngo, BM BS\*, M Alhady, MD\*, A K Tan, MD\*, I Siti Norlasiah\*\*, G B Ong, BMBS\*\*\*, C N Chua, FRCOphth\*

\*The Ophthalmology Unit, Universiti Malaysia Sarawak, (UNIMAS), Lot 77, Seksyen 22, Kuching Town Land District, Jalan Tun Ahmad Zaidi Aduce, 93150 Kuching, Sarawak, \*\*Genetic Laboratory, National Population and Family Development Board, LPPKN Building, Jalan Raja Laut, 50350 Kuala Lumpur, \*\*\*Pediatric Department, Sarawak General Hospital, Kuching, Sarawak

## SUMMARY

A 3-year-old girl with facial dysmorphic features suggestive of Cornelia de Lange syndrome was seen in the ophthalmology unit for a right leukocoria. The leukocoria was found to be caused by a large retinoblastoma and the right eye was enucleated. Chromosomal analysis revealed partial chromosome 13q deletion involving band 14 which is associated with a high risk of retinoblastoma. This case shows that patient with chromosome 13q deletion syndrome cannot be diagnosed based on dysmorphic features only. Chromosomal analysis is warranted in all infants with facial dysmorphism suggestive of Cornelia de Lange syndrome so that those with chromosome 13q deletion can be referred early for early detection of retinoblastoma.

## KEY WORDS:

*Cornelia de Lange syndrome, Chromosome 13q deletion syndrome, Retinoblastoma*

## INTRODUCTION

Dysmorphic features are useful in the clinical diagnosis of certain syndromes. However, some syndromes may have certain identical dysmorphic features which may cause misdiagnosis with serious consequences. We describe a case of chromosome 13q deletion syndrome which was misdiagnosed as Cornelia de Lange's syndrome resulting in delayed diagnosis of retinoblastoma. The case highlights the importance of chromosomal analysis in patients with clinical features of Cornelia de Lange's syndrome in order to miss chromosome 13q deletion syndrome which is associated with the development of retinoblastoma.

## CASE REPORT

A 3-year-old girl with dysmorphic features was referred to the ophthalmology unit because her mother noticed a right leukocoria which had been present for two months. There was no history of retinoblastoma in the family. She was diagnosed with Cornelia de Lange's syndrome based on her facial features: prominent eyebrows, anteverted nostrils, long philtrum, thin lips, and hirsutism (Figure 1). She was noted to have mental retardation however there was no growth problem or any skeletal anomalies seen.

CT scan showed calcification and a mass which was confined to the globe. Examination of the right eye under general

anaesthesia revealed a large white mass measuring 1.5cm in its widest diameter located in the macula. The features were consistent with a retinoblastoma. The left eye was normal. Lumbar puncture and bone marrow biopsy showed no evidence of tumour spread. Enucleation was performed. Histology showed the tumour was confined to the retina and the cut end of the optic nerve was clear. She recovered well post-operatively underwent regular orbital and brain MRI scans and remained disease free at one year review. Her chromosomal analysis revealed chromosome 13q deletion involving band 14 (Figure 2).

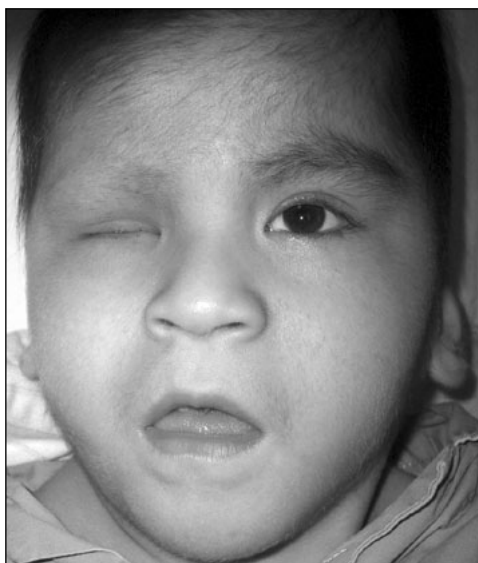## DISCUSSION

The tumour suppressor gene of retinoblastoma (RBI gene) is located on the long arm of the chromosome 13 band 14. Patients with chromosome 13q14 deletion are associated with a high risk (90 to 95%) of developing retinoblastoma<sup>1</sup>. In addition, depending on the amount of deletion of the adjacent chromosome a variety of dysmorphic features may occur ranging from mild to severe collectively known as chromosome 13q deletion syndrome. Motegi<sup>2</sup> reported facial characteristics in patients with an interstitial deletion of 13q consisting of prominent eyebrows, broad nasal bridge, bulbous tip of the nose, a thin upper lip, and long philtrum. Other workers<sup>3</sup> noted anteverted ear lobes, high broad forehead, and prominent philtrum. However, all these features are not specific to chromosome 13q deletion as they are also found in other clinical syndromes such as Cornelia de Lange's syndrome (CdLS). These overlapping of facial phenotypes explain why our patient with chromosome 13q deletion was initially misdiagnosed as a case of CdLS.

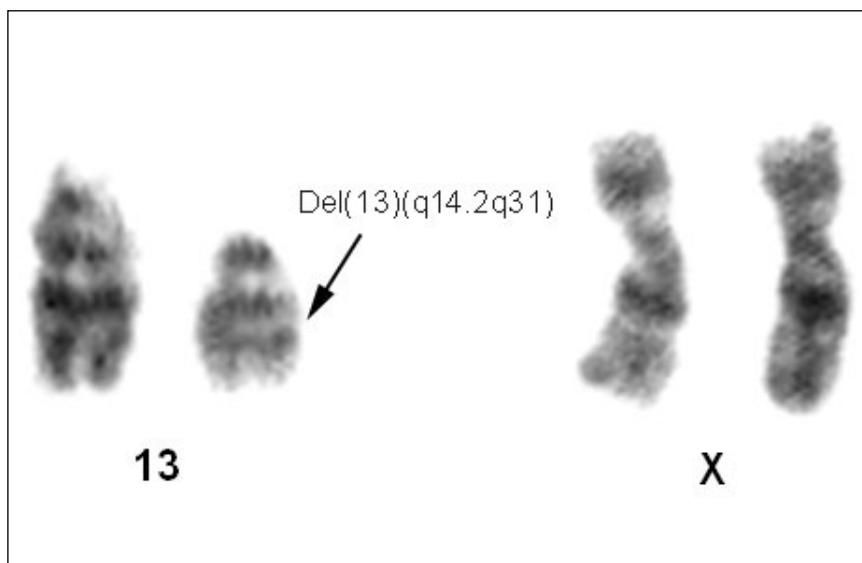
Cornelia de Lange's syndrome also known as Brachmann-de Lange Syndrome was first reported in 1916 by Brachmann on a child whom he performed an autopsy. In 1933, Cornelia de Lange described two unrelated infant girls with mental retardation and similar dysmorphic features. The dysmorphic features are characterized by bushy eyebrows, long curly eyelashes, hirsutism, long philtrum, thin upper lip and down turned angles of the mouth. Late eruption of widely spaced teeth also noted. Limb anomalies are common and consisted of micromelia, phacomelia and oligodactyly. There are growth and mental retardations. The syndrome is estimated to affect about 1:50,000 of the population. Most cases are sporadic and numerous chromosomal rearrangements have been reported in individuals with CdLS<sup>4</sup>.

*This article was accepted: 10 November 2006*

*Corresponding Author: Chua Chung Nen, Ophthalmology Unit, Universiti Malaysia Sarawak (UNIMAS) Lot.*



**Fig. 1:** Facial photograph showing bushy eyebrow, antverted nostrils, long philtrum and hirsutism.  
(Note: Consent have already been obtained from patient's parents)



**Fig. 2:** Partial karyotype showing abnormal chromosome 13 with possible breakage and reunion of bands 13q14.2 and 13q31. The segment lying between these bands has been deleted.

It is now recognized that CdLS also shows clinical variability. Van Allen<sup>5</sup> classified the syndrome into three types based on these variations:

- Type I (or classic) syndrome shows the characteristic facial and skeletal changes as mentioned above.
- Type II syndrome have facial and minor skeletal abnormalities similar to those seen in type I but with less severe psychomotor retardation and milder growth deficiency.
- Type III (phenocopies) refers to patients with phenotypic manifestations resembling Cornelia de Lange's syndrome but may be related to chromosomal aberrations or teratogenic exposures.

This classification is useful as it shows that identification of syndrome using only facial features can be misleading as chromosomal aberrations such as deletion can exhibit similar facial characters. The chromosomal abnormality in our patients shows that our patient belong to type III.

Our report suggests that chromosome 13q deletion syndrome cannot be diagnosed based on dysmorphic feature only. Chromosomal analysis is warranted in all infants with facial

dysmorphism suggestive of Cornelia de Lange syndrome so that those with chromosome 13q deletion can be identified early. Early ocular screening of such patients may reduce the mortality from retinoblastoma and allow preservation of the eye as smaller tumour may be treated with laser or cryotherapy.

#### REFERENCES

- Pakakasama S, Tomlinson GE. Genetic predisposition and screening in paediatric cancer. *Pediatr Clin N Am* 2002; 49: 1393-413.
- Motegi T, Kaga M, Kadowaki H, *et al.* A recognizable pattern of the midface of retinoblastoma patients with interstitial deletion of 13q. *Hum Genet* 1983; 64: 160-62.
- Buad O, Cormier-Daire V, Lyonnet S, Desjardins L, Turleau C, Doz F. Dysmorphic phenotype and neurological impairment in 22 retinoblastoma patients with constitutional cytogenetic 13q deletion. *Clin Genet* 1999; 55: 478-82.
- DeScipio C, Kaur M, Yaeger D, Innis JW, Spinner NB, Jackson LG, Krantz ID. Chromosome rearrangements in Cornelia de Lange syndrome (CdLS): report of a der(3)t(3;12)(p25.3;p13.3) in two half sibs with features of CdLS and review of reported CdLS cases with chromosome rearrangements. *Am J Med Genet A*. 2005; 137(3): 276-82.
- Van Allen MI, Filippi G, Siegel-Bartelt J *et. al.* Clinical variability within Brachmann-de Lange syndrome: a proposed classification system. *Am J Med Genet*. 1993; 47(7): 947-58.