

# Abdominal Subcutaneous Fat Aspiration – An Alternative Method to Diagnose Amyloidosis

S G Ong, MRCP\*, R Rajasingam, MPath\*\*

\*Department of Medicine, Hospital Selayang, Lebuhraya Kepong-Selayang, 68100 Batu Caves, Selangor, \*\*Department of Pathology, Hospital Selayang, Selangor, Malaysia

## SUMMARY

**A middle aged lady presented with clinical manifestations of primary amyloidosis which included amyloid cardiomyopathy. There was failure to confirm the diagnosis of amyloidosis with biopsies from rectal and tongue tissues. Fat tissue obtained from abdominal subcutaneous fat aspiration eventually demonstrated the presence of amyloid.**

## KEY WORDS:

*Amyloidosis, Cardiac, Abdominal, Subcutaneous fat, Aspiration*

Madam HS, a 61 year old Malay lady, presented to a government hospital in Kuala Lumpur in early 2004, with uncontrolled hypertension and congestive cardiac failure. She responded to anti-hypertensive and anti-failure treatment. She was noted to have macroglossia and was promptly investigated. Initial investigations revealed that she was hypothyroid and she received L-thyroxine 0.05mg od. A provisional diagnosis of amyloidosis was made and she underwent a rectal biopsy to confirm the diagnosis. The histopathological report however was inconclusive. As she had joint symptoms and some degree of skin induration, she was referred to the Rheumatology Unit, Hospital Selayang to exclude a connective tissue disease.

History revealed progressive stiffness and reduction in range of motion of the small joints of the hands, wrist joints, elbow joints and shoulder joints over the past couple of years. There was symmetrical joint involvement but no associated joint swelling. In addition, she had difficulty eating solid food for the past three months because of macroglossia, and had to resort to liquid diet. There was no dysphagia. She felt weak generally, had fatigue and lost 10kg in weight over the course of three months.

Clinical examination revealed a frail elderly lady. Her vital signs were within normal limits. She had prominent macroglossia (Figure 1) and there was purpura over both arms. The skin over her arms was indurated and deltoid muscles appeared 'bulky', giving rise to the 'shoulder pad' sign (Figure 2). There was limited range of motion of the shoulder joints, elbow joints, wrist joints and interphalangeal joints of the fingers. The proximal and distal interphalangeal joint swellings were bony and nontender, consistent with Heberden's and Bouchard's nodes, as in osteoarthritis. Tinel's sign was positive in both hands indicating carpal tunnel syndrome.

She had bilateral pitting pedal oedema but there were no signs of overt cardiac failure at that stage. Cardiac auscultation revealed a soft ejection systolic murmur, the lungs were clear and abdominal examination was normal. There was no neurological deficit, in particular peripheral neuropathy.

Laboratory investigations demonstrated normochromic normocytic anaemia (Hb 10.0g%, MCV 80.0fl), normal white cell count and platelet count. There was hypoalbuminaemia (albumin 24g/L). Renal profile, serum calcium and creatine kinase were normal. ESR and C-reactive protein were both elevated at 89mm/hr and 1.99 mg/dL (Normal:  $\leq 0.8$  mg/dL) respectively. Nephrotic syndrome was not present as the 24 hour urinary protein was 0.75g.

Chest X-ray revealed cardiomegaly, and prominent soft tissues around the shoulders. Echocardiography demonstrated features of cardiac amyloidosis i.e. thickened septal wall and interventricular septum, and concentrically hypertrophied left ventricle. There was no hypokinesia and ejection fraction was 50%. Electrocardiography (ECG) showed low QRS complexes and "pseudo-infarction" pattern (Figure 3).

She was screened for multiple myeloma which is known to be associated with amyloidosis. All the tests for multiple myeloma were negative.

She was referred to the oral surgeon for further management of macroglossia as well as to confirm the diagnosis of amyloidosis. Histopathological examination of tongue tissue did not show evidence of amyloidosis. In order to obtain a definitive diagnosis of amyloidosis, we proceeded to do biopsy of the subcutaneous abdominal fat. Histopathology from the fat tissue eventually confirmed the presence of amyloid on Congo red staining.

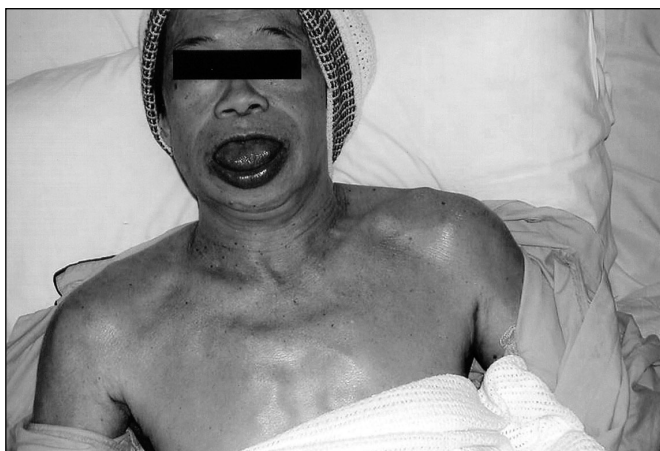As Madam HS was not keen for any further treatment i.e. referral to haematologist and gastrostomy tube for feeding, she was subsequently discharged. Later, we learned that she passed away at home three weeks after discharge.

## DISCUSSION

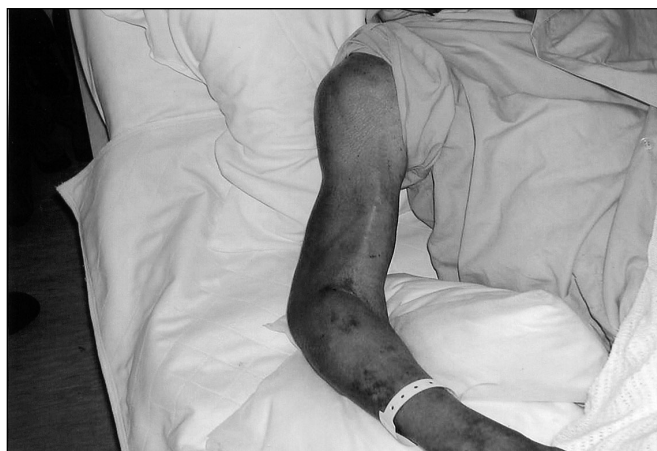Amyloidosis is a condition in which an insoluble proteinaceous material is deposited in the extracellular matrix

*This article was accepted: 17 October 2006*

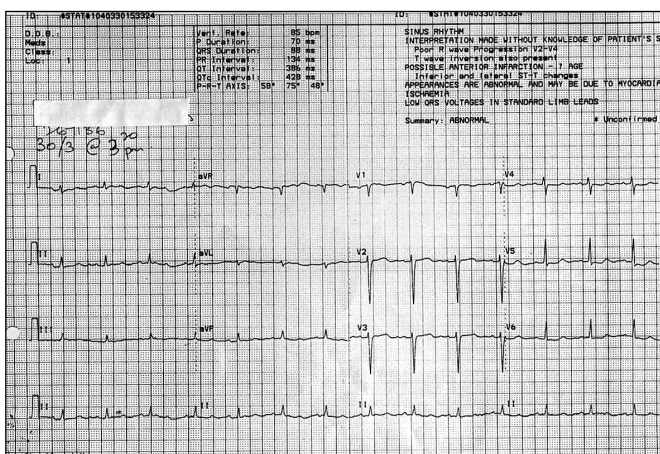
*Corresponding Author: Ong Swee Gaik, Department of Medicine, Hospital Selayang, Lebuhraya Kepong-Selayang, 68100 Batu Caves, Selangor, Malaysia*



**Fig. 1:** Macroglossia with prominent deltoid muscles giving rise to "shoulder pad sign"  
(Note: Consent was obtained from patient's relative as patient had passed away)



**Fig. 2:** "Shoulder pad sign"



**Fig. 3:** ECG showing low QRS voltage and "pseudo-infarction" pattern

of tissue. Amyloid deposition may be subclinical or may produce a diverse array of clinical manifestations. It is important to be aware of this diagnosis because it frequently mimics rheumatic diseases in its presentation. This was illustrated in our patient who was referred to the Rheumatology unit because of arthropathy.

Our patient indeed had primary (AL) amyloidosis with macroglossia, 'shoulder pad' sign, carpal tunnel syndrome, purpura and cardiac involvement. Patients with cardiac amyloidosis typically present with congestive cardiac failure which is rapid in onset and progressive. Echocardiography may reveal symmetric left ventricular wall thickening, small ventricular chambers, valvular and septal thickening, and elongated atria<sup>1,2</sup>. The echocardiographic findings of our patient demonstrated features consistent with amyloid cardiomyopathy. Amyloid can infiltrate the ventricular myocardium, conducting system, intramyocardial or epicardial coronary arteries, heart valves and pericardium. Clinical clues that should alert one to the presence of cardiac amyloid are heart failure with normal left ventricular systolic function and electrocardiographic (ECG) findings of low QRS voltage or "pseudo-infarction" pattern, similar to our patient's. Cardiac involvement has been reported to occur in up to 50% of patients with primary amyloidosis. It carries a

poor prognosis and is frequently fatal, with a median survival of approximately nine months, following the onset of heart failure.

The diagnosis of amyloidosis is established by tissue biopsy where amyloid is detected by the demonstration of characteristic apple-green birefringence of Congo red-stained tissue viewed under polarized light microscope. Rectal biopsy has traditionally been the recommended method of screening for amyloidosis. However more recently, abdominal fat pad aspiration<sup>3</sup> has superseded rectal biopsy as the simplest and most acceptable way to screen for amyloid, with sensitivity ranging between 54% and 82%. Aspiration of fat is easy to perform. It can be done at outpatient clinic and requires no technical expertise. Besides it has a high yield and only minimal side effects to the patients. Abdominal fat tissue can be aspirated with a 16-gauge needle connected to a 10ml-syringe.

The treatment of amyloidosis is directed toward the affected organ as well as the specific type of amyloidosis. In amyloid cardiomyopathy, therapy has modest effect at relieving symptoms. Congestive cardiac failure may initially respond to diuretics, but increasing doses are often required as cardiac disease progresses. Calcium channel blockers and beta-blockers are contraindicated in cardiac amyloidosis, as is digoxin, which may cause toxicity at "therapeutic" levels<sup>4,5</sup>.

Other forms of treatment for primary (AL) amyloidosis include chemotherapy with melphalan and prednisolone, and autologous-blood stem-cell support. Despite this, the overall prognosis for patients with primary amyloidosis remains grim.

#### REFERENCES

1. Borer JS, Henry WL, Epstein SE: Echocardiographic observations in patients with systemic infiltrative disease involving the heart. *Am J Cardiol* 1977; 39: 184-8.
2. Siqueira-Filho AG, Cunha CL, Tajik AJ, *et al*: M-mode and two-dimensional echocardiographic features in cardiac amyloidosis. *Circulation* 1981; 63: 188-96.
3. Falk RH, Comenzo RL, Skinner M. The systemic amyloidoses. *N Engl J Med* 1997; 337: 898-909.
4. Gertz MA, Falk RH, Skinner M *et al*. Worsening of congestive heart failure in amyloid heart disease treated by calcium channel blocking agents. *Am J Cardiol* 1985; 55: 1645-45.
5. Rubinow A, Skinner M, Cohen AS. Digoxin sensitivity in amyloid cardiomyopathy. *Circulation* 1981; 63: 1285-8.