

# Epilepsy Surgery on Dysembryoplastic Neuroepithelial Tumours

S Sayuthi, MB,BCh,BAO\*, J Tharakan DM\*, J George, M.Ch\*, M Socorro Pieter, MA.Psych\*, W M Salmah, MMed\*\*\*, M Madhavan, MDPATH\*\*, B M Biswa, DNB\*\*\*\*, J Abdullah, PhD\*

\*Department of Neurosciences, \*\*Department of Pathology, \*\*\*Department of Radiology,\*\*\*\*Department of Nuclear Medicine, Radiotherapy and Oncology, School of Medical Sciences, Universiti Sains Malaysia, 16150 Kubang Kerian, Kelantan

## Summary

Two rare cases of intractable epilepsy caused by Dysembryoplastic Neuroepithelial Tumours (DNET) are reported and their different management discussed. The first case required vagal nerve stimulation and radiosurgery while the later was operated with the help of neuronavigation. Both had good outcome according to Engel classification after a one year follow up.

**Key Words:** Radiosurgery, Vagal nerve stimulation, Epilepsy surgery, DNET

## Introduction

Dysembryoplastic Neuroepithelial Tumours (DNET) are mostly associated with intractable epilepsy with tendency to be low grade and indolent. Patients usually present with refractory temporal lobe epilepsy with a long history of complex partial seizure (CPS) with secondary generalization<sup>1</sup>. We report two cases of dominant temporal lobe DNET. In a 15- year old female and 17-year old male respectively and discuss the radiological and pathological features with focus on the subsequent neurosurgical management of these patients.

## Case Reports

### Case 1

A 15 years old left handed Malay girl was operated in 1990 in another neurosurgical center after electroencephalography (EEG) and Magnetic Resonance Imaging (MRI) localized the lesion at the right temporal lobe. Histopathological examination (HPE) later reconfirm it being DNET. This is followed

with radiotherapy of a total of 28 fractions in this hospital. She was free of seizure for only six months while still on antiepileptic drug (AED). She developed about 10-15 attacks per month despite being put on various regimens of new generation of antiepileptics.

A left vagus nerve stimulator was inserted in the year 2000. Regular adjustment of the stimulator settings and her triple AED decreased her epileptic attacks to 3-5 attacks a month of a simple partial seizure type. Annual serial MRI after twelve years revealed residual tumour that was enlarging. Planned surgical resection for removal of this residual tumour was abandon as the neuropsychological tests shown the lesion was situated at her dominant hemisphere and that another operative procedure would cause severe memory and cognitive deficits. She underwent radiosurgery for the enlargement of her tumour (Fig. 1). The patient is currently on follow up and her latest Computed Tomography (CT) scan shows no increment of her tumour. She achieved on Engel Seizure Score (ESS) of two and a Commission on Neurosurgery of the International League Against Epilepsy 1997 (CNILAE) score of two.

This article was accepted: 10 April 2006

Corresponding Author: Sani Sayuthi, Department of Neurosciences, School of Medical Sciences, Universiti Sains Malaysia, Health Campus, 16150 Kubang Kerian, Kelantan, Malaysia

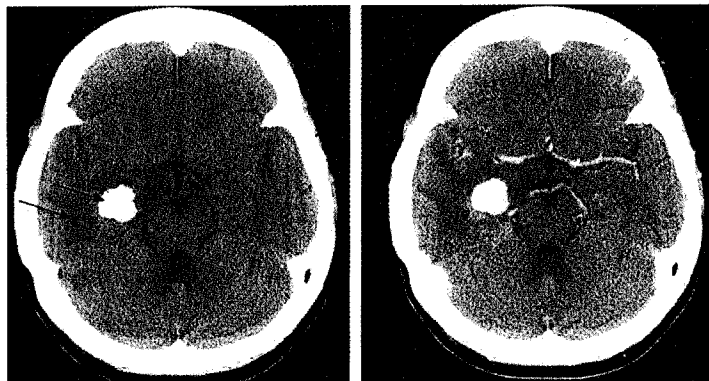
**Case 2**

The second patient was a 17-year right handed old man whom has clinico-electrico-radiological concordance with a lesion in the left temporal pole. This was establish after performing EEG, Video EEG, and epilepsy protocol MRI. The neuropsychological testing demonstrate that he has normal IQ and markedly depressed quality of life. The lesion was situated in the dominant hemisphere (Fig 2). He underwent left temporal lesionectomy with partial anterior temperolobectomy in mid 2004 with the aid of Radionics Omnisight® Image Guided Systems (IGS). Although his verbal IQ and memory has deteriorated slightly, his quality of life (QOLIE-13) score has mark improvement. Post operatively his seizure count dropped from twice daily to twice monthly in the form of CPS with no secondary generalization. His ESS

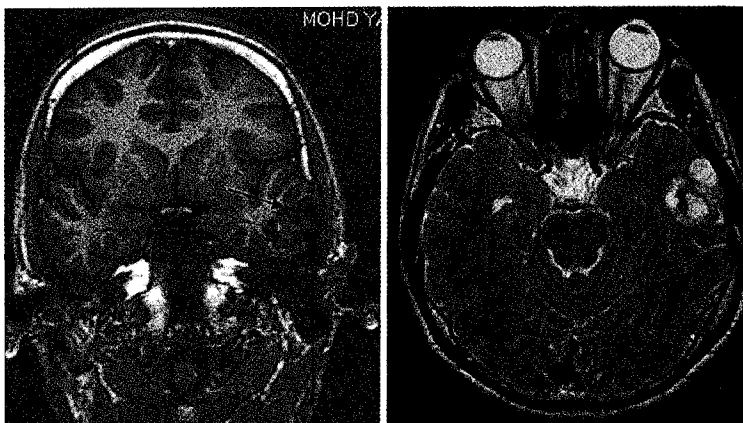
seizure score improved from 9 to 2 and he achieved a CNIAE surgery outcome score of 2.

**Discussion**

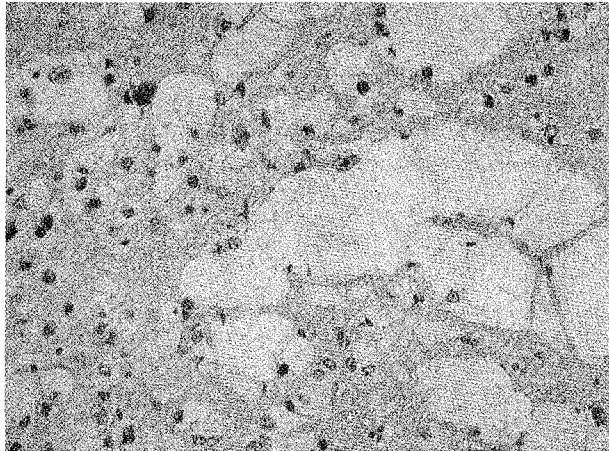
A thorough pre-operative investigation is required to ensure the success of epilepsy surgery with the aim to improve patient quality of life. The selection must be stringent ensuring patient has good social support and meet refractory criteria by looking at the compliance, optimum AED dose and duration by going through their clinical history<sup>1</sup>. The first case after being operated on in another hospital was finally managed with chronic vagus nerve stimulation via an implant (Cyberonics, Inc, Houston, TX, USA). After the tumour was detected growing in size a radiosurgical procedure was done.



**Fig 1:** Plain and contrasted CT scan (Case 1) showing area of gliosis around residual tumour after radiosurgery



**Fig 2:** Pre-operative MRI (Case 2) showing left temporal hypointense on T1WI (sagittal cut) and not suppressed on FLAIR (axial cut)



**Fig 3: Histopathology slide (Case 2) showing oligodendrocytes appear to float in mucinous matrix (on magnification).**

As DNETs are of low grade tumour, intraoperatively the border between normal brain tissues to that of tumour is almost impossible to delineate. As with mesial temporal lobe epilepsy (MTS) careful pre-operative planning need to be made if one has only MRI as guide<sup>2</sup>. In the second case IGS ensured that the whole lesion was resected, without any complications as reported by another author<sup>3</sup>.

Histologic origin of DNET was uncertain but few proposed it come from the external granular layer of the cortex. This tumour behaved similar to oligodendroglioma. Specific criteria for diagnosing it are presence of specific glioneuronal element, consisting of oligodendrocytes in mucinous matrix in which neurones appear to float. Secondly there are glial nodules associated with cortical dysplasia. DNET are positive on special stain namely neuronal and glial

markers (synaptophysin, neuronal specific enolase, GFAP, S-100) (Fig.4)<sup>4</sup>. On radiological imaging, CT of the brain would not reveal the lesion as they are isointense without surrounding oedema or mass effect. Exceptionally they can be large, cystic or calcified. The MRI images will show a mass which are heterogeneously hyperintense on T2WI, iso to hypointense on T1WI, not suppressed on FLAIR and not enhanced on gadolinium.

### Conclusion

In both these patients with complex dominant lobe DNET lesions and intractable epilepsy, additional technology such as IGS, vagus nerve stimulation and radiosurgery were used to improve the management of these epileptic patients. Both patients are now independent, the first patient is a cashier at a sundry shop and the other is doing odd jobs in his village.

### References

1. Daumas-Duport C, Scheithauer BW, Chodkiewicz JP, Laws ER JR, Vedrenne C. Dysembryoplastic neuroepithelial tumors : a surgically curable tumor of young patients with intractable partial seizures. Report of thirty-nine cases. *Neurosurgery* 1988; 23: 545-56.
2. Stanescu Cosson R, Varlet P, Beuvon F, Daumas Duport C, Devaux B, Chassoux F, Fredy D, Meder JF. Dysembryoplastic neuroepithelial tumors : CT, MR findings and imaging follow up : a study of 53 cases. *J Neuroradiol* 2001; 28(4): 230-40.
3. Karatas A, Erdem A, Savas A, Kutlu G, Yagmurlu B, Erden I, Bilir E. Identification and removal of an epileptogenic lesion using Ictal-EEG, functional-neuronavigation and electrocorticography. *J Clin Neurosci*. 2004; 11(3): 343-46.