

# Ingestion of a Voice-Master Prosthesis Followed by a Potentially Fatal Aspiration

R Philip, MMed (ORL-HNS), A G A Imran, MMed (ORL-HNS), S Dinsuhaimi, MS (HNORL), H Shahid, DLO

Department of ORL, Head and Neck Surgery, School of Medical Sciences, Universiti Sains Malaysia, 16150 Kubang Kerian, Kelantan, Malaysia

## Summary

Various complications are associated with the use of indwelling voice prostheses. We present problems faced by a patient with his Voice-Master prosthesis, the ingestion of the prosthesis followed by a potentially fatal aspiration. The Voice-Master is unique in that it can be re-inserted. The safety strap is removed after primary insertion once the prosthesis is secure. However, during re-insertions this safety mechanism is no longer present. Therefore we recommend the placement of a temporary suture or tie to minimize the risks of ingestion or aspiration of the prosthesis during re-insertions.

**Key Words:** Voice prosthesis, Voice-Master, laryngectomy, Tracheo-oesophageal speech, Aspiration

## Introduction

Tracheo-oesophageal speech (TES) with indwelling voice prosthesis is currently considered the gold standard in vocal restoration of laryngectomised patients. The first generation of voice prostheses was introduced by Blom and Singer in 1978. A variety of prostheses have been subsequently developed such as Provox, Groningen, Panje and the Voice-Master<sup>1</sup>. The Voice-Master was first used in patients in 1996. The Voice-Master prosthesis was designed for easier insertion (frontloading), indwelling fixation, low resistance to airflow and re-insertion<sup>2</sup>.

## Case Report

A 48 year old man had a total laryngectomy for a confirmed squamous cell carcinoma of the larynx. A primary tracheo-oesophageal puncture was created and a Voice-Master prosthesis was inserted 14 days post-operatively. The safety strap was removed after two weeks with the prosthesis securely in place.

He was initially unable to use the prosthesis due to excessive crusting around the prosthesis. This had resolved after cleaning and re-inserting the prosthesis. He developed stomal stenosis ten months post-laryngectomy for which refashioning of the stoma was needed. During the procedure, his prosthesis was re-inserted as it had partially dislodged.

On the first post-operative day, the patient accidentally swallowed the prosthesis. A chest and abdominal radiograph was immediately taken which confirmed the presence of the prosthesis on the left side of the gastrointestinal tract. (Fig.1) The prosthesis was recovered the following day. It was disinfected in Gigasept FF (11.0g succindialdehyde and 3.0g dimethoxytetrahydrofuran per 100g solution) for four hours and re-inserted.

A week later during follow-up at the hospital, the patient developed a bout of cough and aspirated the prosthesis. He was initially anxious and dyspnoeic but settled shortly after arriving at the clinic. The patient

This article was accepted: 22 October 2005

Corresponding Author: Philip Rajan, Pakar Klinikal, Jabatan ENT, Hospital Ipoh, Jalan Hospital, 30990 Ipoh, Perak

## CASE REPORT

was placed in a supine position and a 0° rigid Hopkin's endoscope showed the prosthesis lodged at the right bronchus, obstructing the lower division of the right primary bronchi. (Fig.2)

The patient was immediately taken to the operation theatre and the prosthesis was removed under vision with the rigid endoscope. He recovered uneventfully from the event. A new Voice-Master prosthesis was inserted a week later.

### Discussion

Vocal rehabilitation is one of the major challenges of total laryngectomy or pharyngolaryngectomy procedures. Options include electromechanical devices, oesophageal speech and tracheo-oesophageal voice with an indwelling prosthesis.

Tracheo-oesophageal speech (TES) has many advantages over the other forms of voice rehabilitation. The surgical procedure (TE puncture, either primary or secondary) is simple to perform, the prosthesis is easily inserted and no external device is needed. The resultant voice has better acoustic and temporal characteristics compared to esophageal speech. The maximum phonation time is 10.05 seconds and 1.76 seconds respectively, 23 seconds for normal laryngeal speech<sup>1</sup>. Other advantages are that the patients' dexterity and visual acuity is not a prerequisite and phonation is immediate<sup>3</sup>.

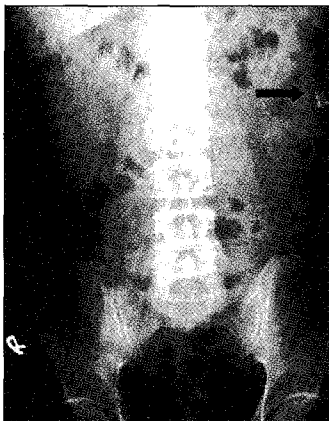
Indwelling voice prostheses are not permanent implants but require periodic replacement. Prosthesis

life-span is determined by the duration complications set in with an average 4-5 months and up to 10 months<sup>1,3</sup>. Lifespan limitation is mainly due to candidal overgrowth causing deterioration of the silicone prosthesis, resulting in leakage and increase in air-flow resistance<sup>2,3</sup>. These prostheses contain 1-way valves and are inserted into a surgically created tracheo-oesophageal fistula.

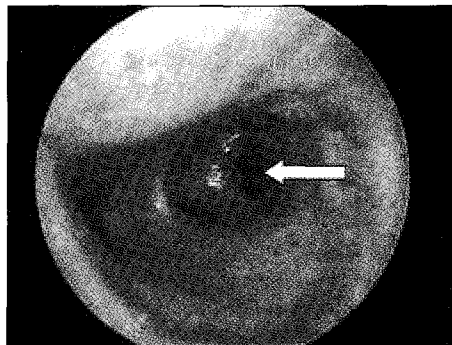
Schouwenburg *et al* reported the complications of the Voice-Master as accumulation of debris, leakage around and thru the prosthesis, snapping of the suspension springs, incidental sticking of the ball-valve, safety strap related and hindrance of the prosthesis<sup>2</sup>.

Various complications have been reported with the other prostheses commonly in use. These include increased tonicity of the pharyngo-oesophageal segment, stricture, recurrent fistula granulation, tracheo-oesophageal puncture migration, recurrent candidal infection, ingestion, mechanical ileus. Aspiration has been reported with a Blom-Singer prosthesis<sup>4</sup>. Interestingly Ward *et al* found that nine patients in his study (31%) who used tracheo-oesophageal speech following laryngectomy switched to electrolarynx or other modes of communication due to the complications<sup>5</sup>.

In order to minimize the risks of aspiration and ingestion we strongly recommend that the manufacturer's guideline of maintaining the safety strap be strictly adhered to until the prosthesis is safely secured during primary insertion. During re-insertions the prosthesis should be secured with a stitch or tie until it can be safely removed.



**Fig. 1: Voice-Master prosthesis in the stomach (Arrow)**



**Fig. 2: Voice-Master prosthesis lodged in right bronchi (Arrow)**

References

1. Hilgers FJ, Ackerstaff AH. Comprehensive rehabilitation after total laryngectomy is more than voice alone. *Folia Phoniatri Logop* 2000; 52: 65-73.
2. Schouwenburg PF, Erenstein SEJ, Grolman W. The VoiceMaster voice prosthesis for the laryngectomized patient. *Clin Otolaryngol* 1998; 23: 555-59.
3. Cornu AS, Vlantis AC, Elliot H, Gregor RT. Voice rehabilitation after laryngectomy with the Provox(R) voice prosthesis in South Africa. *J Laryngol Otol* 2003; 117: 56-61.
4. HYPERLINK "[http://www.ncbi.nlm.nih.gov/entrez/query.fcgi?cmd=Retrieve&db=pubmed&dopt=Abstract&list\\_uids=15535146](http://www.ncbi.nlm.nih.gov/entrez/query.fcgi?cmd=Retrieve&db=pubmed&dopt=Abstract&list_uids=15535146)". Ostrovsky D, Netzer A, Goldenberg D, Joachims HZ, Golz A. Delayed diagnosis of tracheoesophageal prosthesis aspiration. *Ann Otol Rhinol Laryngol*. 2004; 113: 828-9.
5. Ward EC, Koh SK, Frisby J, Hodge R. Differential modes of alaryngeal communications and long-term voice outcomes following pharyngolaryngectomy and laryngectomy. *Folia Phoniatri Logop* 2003; 55: 39-46.