

# Neuroimaging Features of Tuberculous Meningitis

M Sobri\*, J S Merican\*\*, M Nordiyana\*, S Valarmathi\*\*\*, S A Al-Edrus\*

\*Radiology Department, Universiti Putra Malaysia, UPM-HKL, Kuala Lumpur, \*\*Neurology Department, Hospital Kuala Lumpur, \*\*\*Radiology Department, Hospital Kuala Lumpur

## Summary

Tuberculous meningitis leads to a high mortality rate. However, it responds well to chemotherapy if the treatment is started early. Neuroimaging is one of the most important initial investigations. There were 42 patients diagnosed with tuberculous meningitis in Kuala Lumpur Hospital based on clinical criteria, cerebrospinal fluid analysis and response to anti-tuberculous treatment over a 7 year period. Relevant information was obtained from patients' medical case notes and neuroimaging findings were evaluated. Male to female ratio was 3:1. The three major ethnics and the immigrant groups in Malaysia were represented in this study. The majority of the cases involved the Malays followed by immigrants, Chinese and Indians. The patients' age ranged from 18 to 62 years old with the mean age of 34.4 years. There were 95.2% (n = 40) of patients who presented with various neuroimaging abnormalities and only 2 (4.8%) patients had normal neuroimaging findings. Hydrocephalus and meningeal enhancement were the two commonest neuroimaging features. Other features include infarction, enhancing lesion, tuberculoma, abscess, oedema and calcification. Contrasted CT scan is an adequate neuroimaging tool to unmask abnormal findings in tuberculous meningitis.

**Key Words:** Tuberculous meningitis, Neuroimaging

## Introduction

Tuberculosis is a worldwide problem. The largest number of case occur in the South-East Asia Region, which accounts for one-third of incident cases globally. The highest number of estimated deaths is in the South-East Asia Region<sup>1</sup>. Due to the rapid spread of Human Immunodeficiency Virus (HIV), development of drug resistance organisms and immigration from high prevalence countries, there has been an increase in the number of new cases in recent years.

Tuberculous meningitis (TMB) was first described in 1836. It is a complex response by the central nervous system when infected by *Mycobacterium tuberculosis*, and includes cerebritis, abscess, tuberculoma and meningitis. The bacilli reach the central nervous system by haematogenous spread and then form small tuberculous lesions known as Rich's foci in the

meninges, brain or spinal cord. The lesions can become localized tuberculous lesions as in tuberculoma or abscess, or may rupture and contaminate the cerebrospinal fluid.

Tuberculous meningitis may lead to a high, up to 69.9%, mortality rate<sup>2</sup>. However it responds well to chemotherapy if the treatment is started early. Neuroimaging is an important initial investigation in tuberculous meningitis.

## Materials and Methods

This study was carried out at the Diagnostic Imaging Department and Neurology Department, Kuala Lumpur Hospital. The study population included all tuberculous meningitis patients above the age of 12 diagnosed from January 1995 to December 2001 who

This article was accepted: 24 October 2005

Corresponding Author: Sobri Muda, Radiology Department, Universiti Putra Malaysia, Hospital Kuala Lumpur, Kuala Lumpur

underwent neuroimaging. All patients underwent contrasted CT scan of the brain. The diagnosis of tuberculous meningitis was based on clinical criteria, cerebrospinal fluid analysis and a response to antituberculous treatment<sup>3</sup>. Relevant information was obtained from patients' medical case notes and tabulated. Neuroimaging features were evaluated by the radiologists. The features include meningeal enhancement, hydrocephalus, infarction, enhancing lesions, presumed abscess, cerebral oedema and calcification.

## Results

This study comprised of 42 subjects of which 31 (73.8%) were male and 11 (26.2%) were female. The entire three major ethnic groups and the immigrants in Malaysia were represented in this study. As seen on Figure 1, more than half of the cases (n = 23, 54.76%) involved the Malays, followed by Indonesians (n = 7, 16.67%), Chinese (n = 6, 14.29%) and Indians (n = 2, 4.76%). The rest were categorised under 'others'. This group were each represented by a Burmese, Siamese, Bangladeshi and Nepalese. They represented 9.52% (n = 4) of the study population.

The patients' age ranged from 18 to 62 years with the mean age of 34.4 years. Separately, the mean age for the males and females were 33.87 (SD ± 11.1 years) and 35.91 (SD ± 9.63 years) respectively. The majority of the patients (42.9%) were in the age group of 30-39.9 years old and 26.2% were in the 20-29.9 age group. 11.9% were in the 40-49.9 age group and 7.1% in the 50-59.9 age group.

On admission, only 2 (4.8%) patients had normal findings on CT scan. The other 95.2% (n = 40) presented with various types of neuroimaging features. These include at least one of the following: meningeal enhancement, hydrocephalus, infarction, cerebral oedema, enhancing lesion and abscess.

Sixty-two percent (n = 26) of TBM patients in this study presented with hydrocephalus of variable type. Majority of the patients (n = 19) had obstructive hydrocephalus representing 73.1% of those who have hydrocephalus. Another 7 (26.9%) manifested with communicating hydrocephalus.

An equal number of patients (n = 21) presented with and without meningeal enhancement. From the 21 patients, 13 (61.9%) manifested with enhancement of

the basal cisterns and 42.9% had enhancement of the tentorium. None of the patients had cerebellar enhancement. Another 10 (47.6%) patients with meningeal enhancement had involvement of other sites e.g. parietal lobe, temporal lobe, occipital lobe or Sylvian fissure. A number of patients had involvement of multiple sites. Overall, basal cistern enhancement, tentorium enhancement and enhancement of other sites represented 30.95%, 21.43% and 23.81% of all the study subjects.

Infarction was seen in 28.6% (n = 12) of the patients. The size of infarction ranged from 0.5 to 4cm. Most of the patients (75%, n = 9) presented with only a single infarction. However, there are also patients who presented with multiple infarctions (2, 3 or 5 infarctions). The infarctions were identified at various regions of the brain. The region includes either one or both of the thalamus, parietal lobes, internal capsules, caudate nucleus, basal ganglia and frontal lobes. The same percentage of patients (28.6%, n = 12) manifested with cerebral oedema on admission.

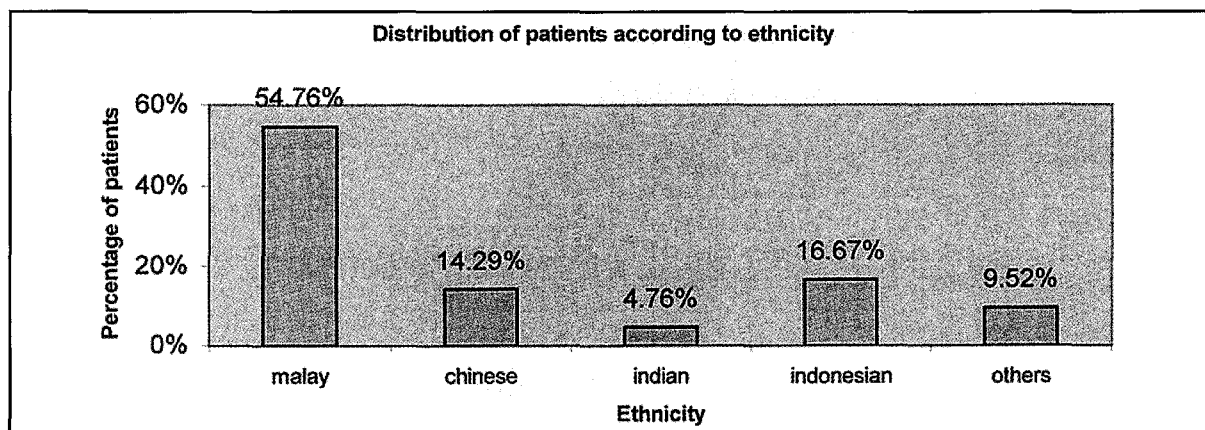
Thirteen (30.9%) patients presented with enhancing lesions. Out of the 13 patients, 38.5% (n = 5) were identified as tuberculomas. Abscess and calcification were seen in only 4.8% (n = 2) of all cases. Table II summarizes other neuroimaging features among all study subjects apart from hydrocephalus and meningeal enhancement.

Twenty-eight (66.67%) of all study subjects also had extrameningeal tuberculosis. Out of this group, most of them (82.4%) had concurrent pulmonary involvement. Two of the patients presented with spinal tuberculosis, one with lymph nodes involvement and another two with involvement of other sites.

## Discussion

This study showed a male preponderance as seen in various other series<sup>1,2</sup>. From the 42 cases studied, 54.8% had associated lung pathology on chest radiographs, which is consistent with many other series,<sup>2,5,6</sup>

The majority of patients had some form of neuroimaging abnormalities, which were picked up relatively well by contrasted CT scan. Although Magnetic Resonance Imaging (MRI), which is more sensitive, was not the main initial neuroimaging tool in this study, it has been shown to reveal more findings<sup>11,14</sup>. Thus, neuroimaging



**Fig 1: Showing the distribution of patients according to ethnicity**

**Table II: Showing other neuroimaging features seen in tuberculous meningitis patients apart from hydrocephalus and meningeal enhancement**

Neuroimaging features	Infraction	Oedema	Enhancing	Tuberculoma lesion	Abscess	Calcification	Normal
Number of patient with aramiditina	12	12	13	5	2	2	2
%	28.6	28.6	30.9	11.9	28.6	4.8	4.8

should be considered as an important initial investigation in highly suspected cases. The two most common neuroimaging findings on admission were hydrocephalus and meningeal enhancement.

In this study, hydrocephalus was the most common neuroimaging finding and this is corroborated by other studies<sup>7-11</sup>. These previously published papers documented rates ranging from 51.0 to 89.2%. Likewise, the percentage of hydrocephalus in this study was within the range and hydrocephalus was the sole neuroimaging finding in 10 (23.8%) of the subjects. According to Bonefe et al<sup>12</sup>, hydrocephalus may be the first clinical manifestation of TBM and it may precede the obliteration of basilar cisterns by several weeks. There were 2 patients who had undergone follow up MRI within 24 hours of admission, which showed multiple tuberculomas although the initial CT scan images only revealed presence of hydrocephalus. This demonstrated that there might already be changes in the neural tissue in a patient with hydrocephalus, although it was not shown by the initial CT scan. In future, these cases might benefit from further evaluation with MRI, functional imaging or PET scan.

The highest frequency of meningeal enhancement was seen in the basal cisterns. This can be explained by gelatinous exudates that fill the basal cisterns, which is typical of tuberculous meningitis. Overall, nearly one third of the patients showed evidence of basal meningeal enhancement. There is an almost similar percentage (38.3%) seen in a study of 48 adults by Verdon et al<sup>7</sup>. On the other hand, other published papers recorded a much higher percentage, up to 64.0%<sup>8,15</sup>. A study by Gupta et al documented an even higher percentage of 84.0% with basal meningeal enhancement, in a series of 26 tuberculous meningitis patients<sup>14</sup>. However, the study used MRI instead of CT scan as the first line of neuroimaging, which would explain the higher sensitivity. MRI with intravenous gadolinium is more sensitive to meningeal lesions as compared to CT scan in TBM patients. MRI also depicts relatively subtle meningeal enhancement, which may not be very prominent on CT scan<sup>11,15</sup>.

Infarction was detected in 28.6% of the cases on admission. Infarction may be solitary or multiple and the size ranged from 0.5 to 4cm. The common sites include the thalamus, parietal lobe, frontal lobe,

caudate nucleus, internal capsule and basal ganglia. This is possibly due to involvement of the branches of the middle cerebral artery with lenticulostriate arteries being the most commonly affected. Leiguarda et al<sup>10</sup> showed changes in cerebral arteriography in cases of tuberculous meningitis involving mainly the middle cerebral artery. This is due to inflammation at the basal cisterns where the middle cerebral arteries pass through.

Tuberculomas are normally seen as ring or nodular lesions in CT scan or MRI images and are sometimes indistinguishable from underlying vascular compromise and ischemic insult. When this arises, tuberculomas may become inconspicuous and thus may not be documented particularly in cases of low immune system where the reactive response is poor, for example in HIV patients. There was a higher percentage of tuberculomas noted in this study compared to other studies that reported between 11.9 to 27.7%<sup>9-10, 13</sup>. This study also revealed higher percentage of cerebral oedema compared to the one obtained by Bhargava et al<sup>9</sup>, which found cerebral oedema in only 3.33% of their subjects.

Although CT was said to be a better tool in evaluating calcification as compared to MRI, calcification was found in only a small percentage of the patients in this study. Out of 42 patients studied, only 2 patients manifested evidence of calcification. To the authors' knowledge, no papers studied the presence of cerebral calcification in tuberculous meningitis patients on admission, although there was one study that evaluated the presence of cerebral calcification following treatment<sup>16</sup>. Abscess was reported in 1.54% of the subjects in our study, which is higher than in previous series. Presumably, this difference may be attributed to differences in age groups and relatively different number of cases studied.

### Conclusion

Neuroimaging features of tuberculous meningitis include hydrocephalus, meningeal enhancement, infarction, enhancing lesion, tuberculoma, abscess, cerebral oedema and calcification. The two commonest neuroimaging features are hydrocephalus and meningeal enhancement. CT scan is an adequate neuroimaging tool to unmask abnormal findings in tuberculous meningitis. Nevertheless, the role of MRI in discovering subtle lesions cannot be ignored.

### References

1. WHO Fact Sheet N°104 (Revised March 2004). Tuberculosis. <http://www.who.int/mediacentre/factsheets/fs104/en/print.html>. (09/04/2004).
2. Karstaedt AS, Valtchanova S, Barriere R, Crewe-Brown HH. Tuberculous meningitis in South African urban adults. *QJM*. 1998; 91(11): 743.
3. Shankar P, Manjunath N, Mohan KK, Prasad K, Behari M, Shriniwas, Ahuja GK. Rapid diagnosis of tuberculous meningitis by polymerase chain reaction. *Lancet*. 1991; 337(8732): 5-7.
4. Medical Research Report: Streptomycin treatment of tuberculous meningitis. *Lancet* 1948: 582-96.
5. Misra, U.K., Kalita, J., Roy, A.K., Mandal, S.K. and Srivista, M. Role of clinical, radiological and neurophysiological changes in predicting the outcome of tuberculous meningitis: a multivariable analysis. *J Neurol Neurosurg Psychiatry* 2000; 68: 300-3.
6. Ranjan P, Kalita J, Misra UK. Serial study of clinical and CT changes in tuberculous meningitis. *Neuroradiology* 2003; 45(5): 277-82.
7. Verdon R, Chevret S, Laissy JP, Wolff M. Tuberculous meningitis in adults: review of 48 cases. *Clin Infect Dis*. 1996; 22(6): 982-8.
8. Bullock MMR and Welchman JM. Diagnostic and prognostic features of tuberculous meningitis on CT Scanning. *J. Neurol Neurosurg Psychiatry* 1982; 45: 1098-101.

## ORIGINAL ARTICLE

9. Bhargava, S., Gupta, A.K. and Tandon, P.N. Tuberculous meningitis. A CT study. *British Journal of Radiology* 1982; 55: 189-92.
10. Leiguarda R, Berthier M, Starkstein S, Nogues M, Lylyk P. Ischemic infarction in 25 children with tuberculous meningitis. *Stroke*. 1988; 19(2): 200-4.
11. Villoria MF, Torre J, Fortea F, Munoz L, Hernandez T, and Alarcon, J.J. MR imaging and CT of Central Nervous System: Tuberculosis in patient with AIDS. *Radiologic Clinics of North America* 1992; 33: 4.
12. Bonafe A, Manelfe C, Gomez MC, Tager M, Massip P, Auvergnat JC, Carriere JP. Tuberculous meningitis: Contribution of computerized tomography to its diagnosis and prognosis. *J Neuroradiol*. 1985; 12(4): 302-16.
13. Kingsley DP, Hendrickse WA, Kendall BE, Swash M, Singh V. Tuberculous meningitis: Role of CT in management and prognosis. *J Neurol Neurosurg Psychiatry* 1987; 50(1): 30-306.
14. Gupta RK, Gupta S, Singh D, Sharma B, Kohli A and Gujral RB. MR imaging and angiography in tuberculous meningitis. *Neuroradiology* 1994; 36: 87-92.
15. Villoria MF, Fortea F, Moreno S, Munoz L, Manero M and Benito C. MR Imaging and CT of central nervous system tuberculosis in the patients with AIDS. *Radiologic Clinics of North America* 1995; 33(4): 805-20.
16. Jinjins JR. Computed Tomography of intracranial tuberculosis. *Neuroradiology* 1991; 33(2): 126-35.