

# Migration of a Foreign Body in the Maxillary Sinus Illustrating Natural Mucociliary Action

K P Pang, FRCSEd\*, J K Siow, FRCSEd\*, H M Tan, FRCR\*\*

Department of Otorhinolaryngology, Tan Tock Seng Hospital, 11 Jalan Tan Tock Seng, Singapore, \*\*Department of Diagnostic Radiology, Singapore General Hospital, Singapore

## Summary

We present a case of a foreign body which migrated to the maxillary ostia by mucociliary action from its initial location on the floor of the maxillary sinus where it was traumatically introduced. This report illustrates that a powerful mechanism of mucociliary action can cause relatively heavy objects within the maxillary sinus to migrate naturally to the sinus ostia against gravitational force.

**Key Words:** Mucociliary action, Maxillary sinus

## Case Report

A 38 year old Bangladeshi worker was first seen at the Emergency department after having sustained a small laceration on the right cheek. He was hammering a nail when a chip of metal flew into his right cheek. Examination revealed a small sub-centimetre laceration of the right nasolabial area. No other injuries were noted. A plain radiograph of the face was taken, and this revealed a foreign body located in the floor of the maxillary antrum (Fig 1). The patient had an exploration and debridement of the cheek wound. Intra-operatively, no foreign body was found. The patient was discharged and given a follow up appointment.

A week later, the patient presented again at the Emergency department, complaining of severe right sided facial pain and facial congestion. He was then referred to the Otorhinolaryngology department. Endoscopy showed congestion of the right ostiomeatal complex, with mucopus arising from the middle meatus, no foreign body or metallic object was seen. The left nasal cavity, post-nasal space and the larynx

were essentially normal. A plain radiograph showed the foreign body at the level of the maxillary sinus ostia, on the lateral nasal wall (Fig 2). A computed tomogram (CT) of the paranasal sinuses revealed the foreign body located at the right maxillary sinus ostia. The patient underwent endoscopic removal of the foreign body. Intra-operatively, an uncinectomy and reduction of the right concha bullosa was performed for exposure, with evidence of the foreign body which was subsequently removed.

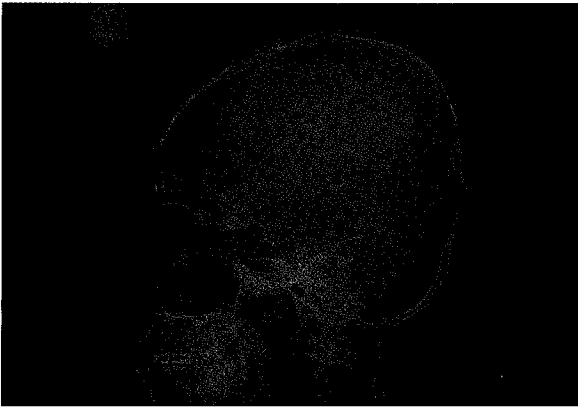## Discussion

There are four paired sinuses named after the skull bones in which they are located, namely, maxillary, ethmoid, frontal and sphenoid. The functional significance of these sinuses have been controversial since the early 1800s. Blanton and Biggs<sup>1</sup> reviewed several theories related to the function of the sinuses and concluded that most are conjecture. These theories include that the sinuses (a) impart resonance to the voice, (b) humidify and warm the inspired air, (c) increase the area for olfaction, (d) act as a shock absorber, (e) secrete mucus to keep the nasal chamber

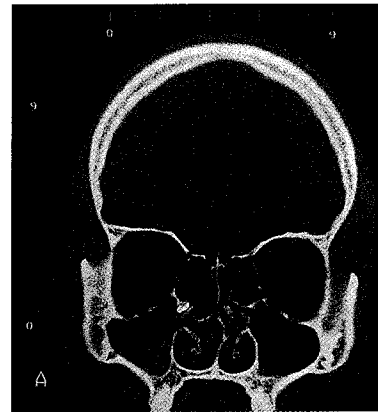
This article was accepted: 18 December 2004

Corresponding Author: Kenny Peter Pang, Department of Otorhinolaryngology, Tan Tock Seng Hospital, 11 Jalan Tan Tock Seng, Singapore

## CASE REPORT



**Fig. 1: Plain radiograph of the skull showing the foreign body located at the floor of the maxillary sinus.**



**Fig. 2: CT scan (coronal) of the sinuses. Showing the foreign body located at the maxillary ostia.**

moist, (f) provide thermal insulation for the brain, (g) contribute to facial growth, (h) represent vestigial structures, and (i) lighten the weight of the skull.

The sinuses are all similar, they contain air and are lined by the typical respiratory type epithelium, composed of pseudostratified ciliated columnar epithelial cells. A mucus blanket covers these cells. The cilia are in constant motion and act in concert to propel the mucous in a specific direction. The pattern of flow is specific for each sinus and will persist even if alternative openings are made. In the maxillary sinus, the mucous flow originates in the floor of the sinus, and beats centripetally toward the primary ostia<sup>2,3,4,5</sup>.

The cilia beat frequency is between 10 and 20 Hz at body temperatures with a mean of 14 Hz. It remains fairly constant between 32 and 40 degrees Celsius and does not appear to be temperature dependent within this range. Other factors affecting ciliary action include drying of the mucus layer, pH, infection and drugs.

The knowledge of the fundamentals of mucociliary clearance have largely been the result of work by Messerklinger, who followed animal experiments of Hilding Sr. Messerklinger's studies, on the observation that human nasal and paranasal sinus mucosa and their ciliary activity survive 24 to 48 hours beyond the death

of the individual. Messerklinger originally used fresh cadaver heads, staining the mucus by adding dust particles or different types of powders. He studied the pathways and duration of mucus transport in the paranasal sinuses.

With the advent of endoscopy, the endoscopist has discovered that not all sinus mucosa transport mucus uniformly. Occasionally, it can be noted that certain areas transport mucus faster than other areas, yet after a few minutes, the slower areas may speed up as the faster areas slow down. This phenomenon of "secretion expressways" can be found in both normal and abnormal sinus mucosa. It is not known if this phenomenon is an artefact caused by the light and warmth of the endoscope or by the trauma caused by the insertion of the endoscope.

There are many theories to the mucociliary transport system of the paranasal sinuses. This case illustrates the spontaneous movement of this metallic foreign body. It is postulated to have entered the floor of the maxillary sinus through a penetrating wound during the injury. It subsequently migrated, with the aid of the mucociliary action to the natural ostia of the maxillary sinus where it was removed endoscopically. This case demonstrates that the foreign body moved from the floor of the maxillary sinus to the natural ostia in 7 days.

---

NOTE: This paper was wrongly published in the August 2005 issue with the wrong figures and is now corrected.

References

1. Blanton PL, Biggs NL. Eighteen years of controversy: the paranasal sinuses. *Am J Anat.* 1969; 124: 135.
2. Kennedy DW, Zinreich SJ. The functional endoscopic approach to inflammatory sinus disease: current perspectives and technique modifications. *Am J Rhinol.* 1988; 2: 89.
3. Messerklinger W. *Endoscopy of the nose.* Baltimore. 1978. Urban and Schwarzenberg.
4. Stammberger H. *Functional sinus surgery.* Philadelphia. 1991. Mosby.
5. Wigand ME, Steiner W, Jaumann MP. Endonasal sinus surgery with endoscopic control: from radical operation to rehabilitation of the mucosa. *Endoscopy.* 1978; 10: 255.