

# Molecular Genetic Analysis of a Supratentorial Haemangioblastoma in a Non-Von Hippel Lindau Patient

I Zamzuri, MMed\*, M M Ghazali, BSc\*, N Zainuddin, MSc\*, S Sulong, MSc\*\*, S M Samarendra, MD(Path)\*\*\*, A A Mohd Yusoff, MSc\*, A R M Ariff, MMed\*\*\*\*, J Abdullah, PhD\*

\*Department of Neurosciences, \*\*Human Genom Center, \*\*\*Department of Pathology, \*\*\*\*Department of Radiology, School of Medical Sciences, Universiti Sains Malaysia, 16150 Kubang Kerian, Kelantan

## Summary

We describe a rare tumor site in a 46 year old man who presented with a two week history of headache. Physical examination revealed bilateral papilloedema with no other localizing signs. Computed Tomographic Scan as well as Magnetic Resonance Imaging of the brain revealed a lesion with a dura tail located adjacent to the falx cerebri of the right frontal lobe. This lesion was not invading the inner table of the skull base. A tumor blush was seen on angiogram. There were no abnormalities on CT scan of the abdomen and fundoscopy was normal. Intraoperatively a vascular tumor not attached to the dura was noted and removed totally. Histopathological examination was typical of a hemangioblastoma. Analysis revealed no mutations of the VHL gene in 5 regions, exon 5-8 of the p53 gene, exon 1-2 of the p16 gene and exon 5,6 and 8 of the PTEN gene. This is the first case report of a supratentorial hemangioblastoma in a non-Von Hippel Lindau patient with genetic evidence.

**Key Words:** Non Von-Hippel Lindau, Hemangioblastoma, Supratentorial, Neurogenetics

## Introduction

Hemangioblastomas are rare benign tumors of the central nervous system that account for 1.0-2.0% of all intracranial tumors. They usually arise in the cerebellar hemisphere and account for 7.3% of all posterior fossa tumors in adults. Supratentorial location occurs in only 2.9%. Hemangioblastoma is the most common CNS manifestation of Von Hippel-Lindau disease (VHLD), an autosomal dominant, inherited disorder characterized by tumors and cysts developing in multiple organs, including the retina, adrenal glands (pheochromocytomas), kidney, and pancreas<sup>1,2</sup>. Patients with hemangioblastomas usually present with cerebellar dysfunction or hydrocephalus. We report a case of supratentorial hemangioblastoma not associated with VHLD gene.

## Case report

A 46 year old Malay male with history of long drawn diabetes mellitus type II and hypertension presented with a history of chronic headache which had become worse since the last 2 weeks and was associated with nausea and lethargy. He experienced blurring of vision without diplopia or field loss. There was no history of seizure, gait or urinary disturbance, anosmia or abnormal behaviour. Family history revealed no evidence of haematological, ophthalmological or abdominal disorders. On clinical assessment, he was normotensive and examination for higher mental status revealed an alert and conscious man with no focal neurological deficit. There was reduced visual acuity in both eyes and bilateral papilloedema on fundoscopic examination. Complete hemogram and biochemical

This article was accepted: 12 August 2004

Corresponding Author: Jafri Malin Abdullah, Department of Neurosciences, Universiti Sains Malaysia, 16150 Kubang Kerian, Kelantan

analysis revealed no evidence of polycythemia, adrenal or pancreatic disorders. The CT of the brain disclosed a right extraxial frontal lobe lesion measuring about 5 x 4 cm located adjacent to the falx Cerebri. The lesion enhanced homogeneously with contrast. There was a marked perifocal oedema (Figure 1). The MRI showed a well defined rounded mass with dural tail at the right parasagittal region measuring 4 x 3.5 x 3.5 cm. It was isointense to grey matter on T1 and hyperintense on T2 which enhanced markedly post Gadolinium associated with perifocal oedema. The mass compressed the body of corpus callosum and extended to the inner table of skull. A 6 vessels Digital Substraction Angiogram revealed a tumoural blush in the right parasagittal area, which appeared early in the arterial phase and stayed on until the late venous phase. CT scan of the chest and abdomen revealed no abnormality.

This was typical of the meningioma blush described as "mother-in-law blush" sign. The tumour was supplied by the pericallosal branches of the right and left anterior cerebral arteries and also by the middle meningeal arteries. All these features were in keeping with meningioma.

The tumour was removed successfully via a right frontal craniotomy. Intraoperatively, a lesion that was not attached to the dura was removed totally.

#### **Pathological Examination**

Gross pathological examination of the resected tumour revealed multiple grey-tan soft tissue about 60 mm in diameter, the largest fragment measuring 40 x 30 x 20 mm. Histology showed a vascular tumour composed of a rich network of small narrow or dilated endothelial-lined channels and surrounding sheets of polygonal stromal cells with vesicular or dark large nuclei, insignificant nucleoli and abundant vacuolated or clear cytoplasm (Figure 2). A few scattered haemosiderin-laden macrophages were also seen in the stroma. Reticulin was rich highlighting the capillary meshwork and surrounding small or large clusters of stromal cell.

Mitosis and cellular atypia were not seen. Toluidine blue stain revealed moderate number of mast cells in the tumour. Tight whorls of cells and psammoma bodies characteristic of meningioma were absent.

#### **Immunohistochemistry**

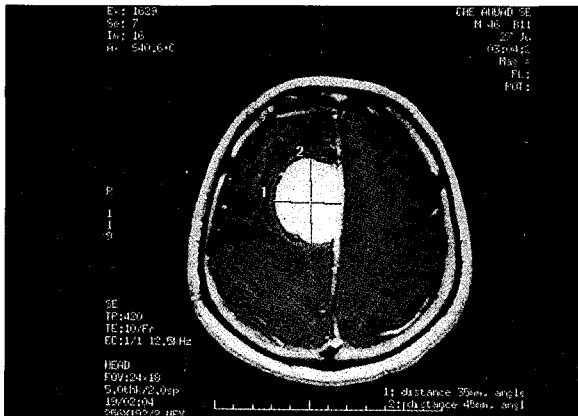
Immunohistochemical stain for factor VIII-related antigen and CD31, both endothelial cell markers, epithelial membrane antigen (EMA) and glial fibrillary acid protein (GFAP) were negative but vimentin was positive in the stromal cells. The findings were typical of hemangioblastoma.

#### **Molecular analysis**

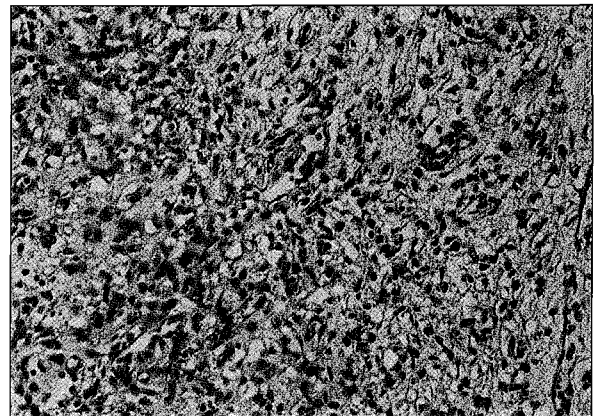
A DNA sample from the patient's brain tumor tissue was extracted using a commercial extraction kit (Qiagen, Valencia, CA, USA), according to standard protocol for mutational of the VHL gene, p53 gene, p16 gene and PTEN gene. Leucocytes from peripheral blood of normal patient was used to prepare normal DNA control.

#### **Mutational analysis**

Polymerase chain reaction (PCR)- single strand conformational polymorphism (PCR-SSCP) was performed on VHL gene in 5 regions, exon 5-8 of the p53 gene, exon 1-2 of the p16 gene and exon 5,6 and 8 of the PTEN gene. The SSCP analyses were performed using the DCode system. After the electrophoresis process was completed, the gels were stained using the silver staining method. The PCR products of the genes with variant SSCP patterns were purified using PCR Purification Kit (QIAGEN GmbH, Hilden, Germany) before proceeding with direct sequence analysis using ABI PRISM 3100 Genetic Analyzer (Applied Biosystems, Foster City, CA). No mutation was detected in exon 5-8 of the p53 gene, exon 1-2 of the p16 gene and exon 5, 6 and 8 of the PTEN gene. Analysis of the VHL gene showed no mutations in 5 region and all the conditions were carried out as previously described by Oberstrass et al 1996.



**Fig. 1: MRI T1WI post IV gadolinium showed a well defined enhanced rounded mass with a dural tail. Again there was a marked perifocal oedema.**



**Fig. 2: Photomicrograph showing abundant stromal cells with vacuolated cytoplasm around small endothelial-lined vascular channels (H & E x 100).**

**Discussion**

Hemangioblastoma is the most common central nervous system manifestation of VHL and the majority of them occur in the cerebellum. Supratentorial hemangioblastomas are very rare and most are associated with VHL. Although closely associated with the meninges, their histogenesis is controversial and they are now classified under tumours of uncertain origin<sup>1,4</sup>. The finding of gene expression of vascular endothelial growth factor in the stromal cells but not in the endothelial cells appear to shift the histogenetic role to the stromal cells<sup>1</sup>. The rich capillary network and the foamy stromal cells highlighted by reticulin stain are characteristic of hemangioblastoma (Figure 2). Immunohistochemical stains supporting hemangioblastoma include positivity for vimentin and negativity for EMA, GFAP, factor VIII-related antigen and CD31<sup>1,4</sup>.

MRI is the most effective non-invasive modality to diagnose haemangioblastoma. The characteristic features are cystic lesions with a mural nodule. The nodule shows strong enhancement with gadolinium.

Angiography is necessary not only to depict the highly vascular lesion with a prolonged stain, but also to

identify small nodules that can be missed in MRI<sup>4</sup>. In our case, we encountered a solid haemangioblastoma which enhanced with gadolinium. The lesion also showed dural tail on angiogram, lesion showed ‘mother in law’ phenomena as described in meningioma.

**Conclusion**

Hemangioblastomas are benign tumours. Though recurrences up to 25% occur after surgical excision, the prognosis is generally good<sup>1</sup>.

Involvement of mutations of the p53, p16 and PTEN tumor suppressor genes in capillary haemangioblastoma has not been reported. Based on our observations, we postulate that p53, p16 and PTEN genes may not be involved in the multistep pathogenesis of capillary haemangioblastoma in this case.

**Acknowledgements**

We thank Dr P.W.Allen, Flinders Medical Centre, Bedford Park, South Australia and Dr P. McKelvie, Anatomic Pathology, St. Vincent’s Hospital, 41 Victoria Parade, Fitzroy, Australia, for opinion on the slides.

References

1. Lantos PL, Vanden Berg SR, Kleihues P. Tumours of the nervous system In: Graham DI and Lantos PL eds. Greenfield's neuropathology 6th edn. Arnold, London, 1997; 2: 750-52.
2. Neumann HP, Eggert HR, Schretner R et al. Central nervous system lesions in Von Hippel-Lindau Syndrome. J Neurol Neurosurg Psychiatr 1992; 55: 898-90.
3. Oberstrass J, Reifenberger G, Reifenberger J, Wechsler W, Collins VP. Mutation of the Von Hippel-Lindau tumour suppressor gene in capillary haemangioblastoma of the central nervous system. J Pathol 1996; 179 (2): 151-56.
4. Berger PC and Scheithauer BW eds In: Tumours of the central nervous system. Atlas of tumor pathology, Fascicle 10, AFIP, Washington DC 1993; 239-48.