

# Acute Disseminated Encephalomyelitis: A Report of Six Cases

G S T Thomas, MRCPCH, I H M I Hussain, FRCP

Paediatric Neurology Clinic, Penang Hospital, Jalan Residensi, 10990 Penang

## Summary

Six children with Acute Disseminated Encephalomyelitis (ADEM) were seen at the Penang Hospital over a two year period (July 1999-June 2001). Diagnosis was based upon typical clinical features and characteristic findings on neuroimaging. Cerebrospinal fluid examination and other investigations were done, where appropriate, to rule out other causes of central nervous system disease.

Three children had a prodromal illness. The most common presenting symptoms were fever, seizures, ataxia, focal neurological deficits and labile mood. Two children presented with status epilepticus. All children had an abnormal neurological examination. Brain magnetic resonance imaging revealed hyperintense signals on T2-weighted and FLAIR sequences in the subcortical and deep white matter regions of the frontal, parietal, and temporal lobes, as well as in the thalami, cerebellum and brainstem. One child had multiphasic disseminated encephalomyelitis (three episodes).

The child with multiphasic disease had only one treated episode, and has suffered mild disability. Three children were treated with either methylprednisolone or immunoglobulins, and remain well. One child received both treatments but expired as a result of severe gastrointestinal bleeding from the use of methylprednisolone. The child who was not treated has severe disability.

**Key Words:** Acute disseminated encephalomyelitis, Children, Disability

## Introduction

Acute Disseminated Encephalomyelitis (ADEM) is a monophasic, immune mediated demyelinating disorder. Numerous reports were published in the early 1900's, but McAlpine was the first to review the clinical presentation, aetiology, outcome and its distinction from multiple sclerosis, in 1931<sup>1</sup>.

The disease commonly follows a viral infection or vaccination, though in many cases, no aetiology can be identified<sup>2,3</sup>. Recent reports have implicated a broader

spectrum of organisms, e.g. *mycoplasma*,  $\beta$ -haemolytic *streptococci*, *Campylobacter*, *Legionella*, *S. typhi* and malaria<sup>2,7</sup>. The pathogenesis is still unclear. There appears to be a T and B cell response to intrinsic myelin proteins<sup>3,8</sup>. Possible theories include molecular mimicry, an initiation of immune responses within the CNS or the action of viral and bacterial superantigens<sup>3</sup>.

Clinical features tend to be multifocal, reflecting the site and extent of CNS involvement. Cerebrospinal fluid examination shows lymphocytosis with a slight increase in protein content. Myelin basic proteins are

This article was accepted: 29 November 2003

Corresponding Author: Terrence GS Thomas, Paediatric Neurology Clinic, Penang Hospital, Jalan Residensi, 10990 Penang

present in the spinal fluid; oligoclonal bands are characteristically absent. The use of magnetic resonance imaging (MRI) has provided an early non-invasive tool for diagnosis, and superseded the need for brain biopsy. Characteristic findings are multifocal areas of increased signal intensity in the white matter on T<sub>2</sub>-weighted and FLAIR sequences<sup>10</sup>.

Recovery is the rule, though 10% of patients suffer permanent disability. This figure is higher (20-30%) if the disease followed a measles virus infection. Variant clinical forms exist, including a fulminant form that progresses to a haemorrhagic leukoencephalitis<sup>13-15</sup>.

There are no reports in the literature on the incidence of acute disseminated encephalomyelitis. Some tertiary centres have reported 2 to 5 cases per year<sup>2,9,10</sup>. We report 5 children over a 2½ year period at the Neurology Clinic in Penang Hospital. A 6th child had been seen earlier at another centre and referred to us for follow up and rehabilitation.

The following is a brief clinical description of the 6 cases:

### Case 1

Patient 1 is a Chinese girl who was well till age 13 months. She presented to another hospital with generalised clonic seizures which evolved into status epilepticus. She had had fever and diarrhoea for two days prior to admission. On admission she was drowsy, had a left sided ptosis and left hemiparesis. Reflexes were normal on admission. The encephalopathy persisted and she developed generalised hypertonia, ophisthotonus and brisk reflexes. She was managed as having encephalitis, and received antibiotics and anticonvulsants. Lumbar puncture was not performed. Computed tomographic (CT) scans of the brain showed cerebral oedema with multiple irregular hypodense areas in the right frontal, both parietal, left temporal and left cerebellar lobes. MRI scans revealed multiple lesions in the white matter of the same areas (Figure 1). Her hospital stay was complicated by intractable generalized tonic clonic seizures.

Since discharge, she has global developmental delay, cortical blindness, bilateral mild sensorineural hearing loss and poorly controlled myoclonic / tonic epilepsy.

She was seen at Penang Hospital at 18 months of age and a retrospective diagnosis of ADEM was made

based on the appearances of the CT/MRI scans. She is now 5 years old.

### Case 2

Patient 2 is a 7 years old Chinese boy who has had recurring episodes of ADEM, otherwise termed multiphasic disseminated encephalomyelitis.

He was first admitted at age 4½ years to a private hospital when he presented with fever for 2 days, associated with drowsiness and poor feeding. There were no seizures. He had had an upper respiratory tract infection a month before. On admission he had altered sensorium, neck stiffness, increased tone, brisk reflexes, clonus and upgoing plantars. He later developed generalised tonic clonic seizures which were controlled with anticonvulsants. He was treated for meningoencephalitis and received antibiotics. Lumbar puncture was not done. Computed tomographic (CT) scans of the brain showed patchy areas of oedema whilst MRI scans revealed multiple lesions in the white matter of both temporal and parietal lobes, as well as involving the corona radiata, corpus callosum, basal ganglia, dorsal pons, inferior cerebellar peduncles and left cerebellum (Figure 2).

He made a complete recovery after a few weeks and was attending kindergarten again. A year later, aged 5½ years, he developed fever for a day followed by generalised tonic clonic convulsions that lasted 10 minutes. Postictally he had a period of altered sensorium that lasted 16 hours. He had normal tone and power, but brisk lower limb reflexes. When awake he was noted to have an ataxic gait. MRI scans showed new lesions in the white matter of both cerebellar hemispheres, and in the frontal, temporal and parietal lobes.

Spinal fluid examination showed an absence of cells, a protein content of 0.28g/L, and a glucose level of 3.4 mmol/l (> 60% blood glucose level), and no oligoclonal bands. He received intravenous immunoglobulins (400mg/kg/day for 5 days). He was discharged after a week, clinically well, although visual evoked potentials showed delayed latencies on the left side.

Six months later he developed fever and a varicella zoster exanthem. On the same day he developed drowsiness, aphasia and focal seizures (twitching of the lips with deviated gaze to the right). He later exhibited a nystagmus to the left. All symptoms resolved in 12

hours. Lumbar puncture was not done. CT scan brain was normal. He received acyclovir for a week. He was discharged well.

At age 7 years he had a first afebrile seizure - generalised tonic clonic lasting 25 minutes, on awakening from sleep. Postictally he recovered well after a brief sleep. Electroencephalogram showed focal slowing over the left occipital area.

In between episodes he has returned to normal functioning. He now attends school in Primary 2. School performance is average, though he exhibits mild dyslexia.

### Case 3

A 4 years old Chinese girl presented with an afebrile partial status epilepticus (focal right sided facial seizures) associated with a right sided lower motor neuron seventh cranial nerve palsy. On admission she was alert and retained full consciousness, with no other positive signs apart from the cranial nerve palsy. Initial MRI brain and cerebrospinal fluid examination were normal. Electroencephalogram was normal. She was initially managed as having encephalitis with antibiotics, antiviral agents and anticonvulsants.

Upon weaning the anticonvulsants, she was noted to have persisting drowsiness, a fixed gaze to the left, hypotonia and hyporeflexia. A repeat lumbar puncture showed elevated lymphocytes (14 per mm<sup>3</sup>) with normal protein (0.36 g/L) and glucose (3.7 mmol/L). A second MRI brain scan on day 9 of illness showed diffuse signal changes in the grey and white matter in both parietal and temporal lobes and thalami. She received intravenous immunoglobulins (1 Gm/kg/day for 2 days) on day 10, but did not show improvement, by this time exhibiting increased tone with opisthotonus, extensor posturing and brisk reflexes. She thus received intravenous methylprednisolone (20 mg/kg/day for 5 days) but developed severe upper gastrointestinal bleeding, to which she succumbed.

### Case 4

This 6 years old Chinese girl had measles 2 weeks prior to presentation. She developed fever, ataxia, poor vision and labile mood over the preceding 5 days. Examination revealed an alert child who had poor visual acuity (right eye 6/60, left eye 6/36), ataxic gait, dysdiadochokinesia and a positive Romberg's sign.

Fundoscopy was normal. Spinal fluid examination showed no cells, elevated protein (0.69 g/L) and normal glucose (3.6 mmol/L). Visual evoked potentials were diminished bilaterally. MRI showed multiple lesions in the white matter of the frontal, parietal, temporal and occipital lobes as well as in the cerebellum. She received intravenous methylprednisolone (30 mg/kg/day for 5 days). On follow up, she recovered normal visual acuity at 3 months although visual evoked potentials remain abnormal.

### Case 5

An 11- year old Indian boy, who lives in a welfare home presented with a week of fever, 3 days of frontal headache and vomiting, and a day's history of diplopia. There was no alteration in sensorium or seizures. On examination he was noted to be alert and orientated, the only abnormal signs being slight blurring of the optic disc margins and bilateral sixth cranial nerve palsy. The guardians did not consent for lumbar puncture. CT scan of the brain was normal but an MRI showed 2 small lesions in the corona radiata and the white matter of the right parietal lobe. A neostigmine test for myasthenia was negative. He received intravenous methylprednisolone (30mg/kg for 3 days). He showed signs of recovery before discharge and was completely well after a month.

### Case 6

An 11-year old Malay girl developed 4 afebrile seizures over a 2 months period. The seizures were generalised tonic clonic; the longest seizure lasted 10 minutes. There was no aura and the postictal period was unremarkable. However, after the last seizure she developed aphasia, a right sided hemiplegia and labile mood. There was no history of fever, altered sensorium or a preceding illness. She was alert on examination, but had reduced tone, power (2/5) and depressed reflexes over the right side. Lumbar puncture was not done. MRI revealed multiple lesions involving the white matter of the cerebellar peduncles with extension to the cerebellum, at the junction of the right temporo-parietal lobe, and in the left frontal and parietal lobes. She received intravenous immunoglobulins (1 gm/kg/day for 2 days). By the end of the first week, she had regained some muscle power (3/5 - 4/5) and had begun to speak. She attained full recovery after a month.

**Table I: Patient characteristics**

Case	Age	Gender	Ethnicity	Prodrome	Presentation	Neuroimaging (MRI)
1.	13m	girl	Chinese	none	fever, seizures, encephalopathy	multiple white matter lesions of cerebral cortex, cerebellum
2.*	4 1/2 years	boy	Chinese	URTI	fever, seizures, encephalopathy	multiple white matter lesions of cerebral cortex, cerebellum. basal ganglia, pons also involved
	5 1/2 years			none	fever, seizure, ataxia	new white matter lesions of cerebral cortex, cerebellum
	6 years			varicella	drowsiness, aphasia, focal seizure, nystagmus	no imaging done
3.	4 years	girl	Chinese	none	afebrile partial status epilepticus, right LMN facial nerve palsy	day 1 : normal day 9: white matter lesions in both parietal, temporal lobes. thalamus also involved
4.	6 years	girl	Chinese	measles	fever, visual loss, ataxia labile mood	diffuse white matter lesions of cerebral cortex, cerebellum
5.	11 years	boy	Indian	none	headache, vomiting bilateral 6th nerve palsy	subtle white matter lesions in both parietal lobes
6.	11 years	girl	Malay	none	afebrile seizures, aphasia, labile mood, right hemiplegia	multiple white matter lesions of cerebral cortex, cerebellum

\* Case no. 2 had 3 presentations.

URTI = upper respiratory tract infection. LMN = lower motor neuron.

**Table II: Presenting symptoms**

Symptom	No.	%
Prodromal illness	3	37.5
Fever	6	75.0
Headache	1	12.5
Vomiting	1	12.5
Seizures	6	75.0
Generalised	4	
Simple Partial	1	
Complex Partial (Evolved to Status epilepticus)	1 2	
Altered sensorium	4	50.0
Aphasia	2	25.0
Visual disturbances	2	25.0
Diplopia	1	
Poor visual acuity	1	
Unsteadiness	2	25.0
Mood changes	2	25.0
Urinary incontinence	1	12.5

One child had multiphasic episodes (MDEM) = 3 presentations.

Therefore total no. of presentations = 8

**Table III: Presenting signs**

Sign	No.	%
Altered sensorium	5	62.5
Papilloedema	1	12.5
Cranial nerve involvement	4	50.0
Motor cranial nerve	3	
Sensory cranial nerve	1	
Motor involvement	5	62.5
Focal	3	
Generalised	2	
Increased tone	4	
Brisk reflexes, clonus	5	
Upgoing plantars	3	
Sensory involvement	0	0.0
Cerebellar dysfunction	5	62.5
Ataxic gait	2	
Nystagmus	1	
Dysdiadochokinesia	1	
Intention tremors	1	
Dysmetria	1	
Positive Romberg's sign	1	
Aphasia	2	25.0
Urinary incontinence	1	12.5
<b>Normal Neurological examination</b>	<b>0</b>	<b>0.0</b>

One child had multiphasic episodes (MDEM) = 3 presentations.

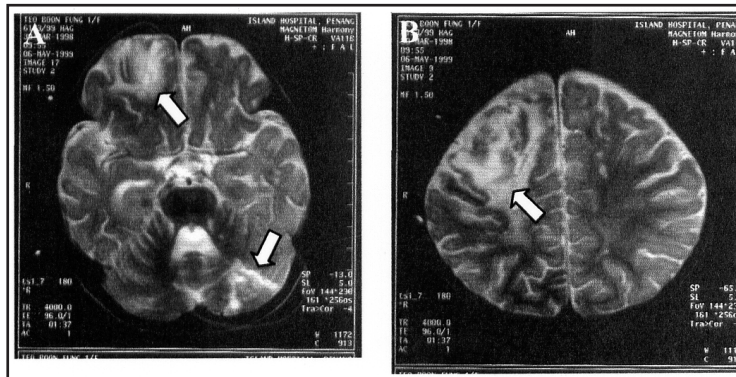
Therefore total no. of presentations = 8

**Table IV: Treatment and outcome  
(excludes the child with multiphasic disseminated encephalomyelitis) †**

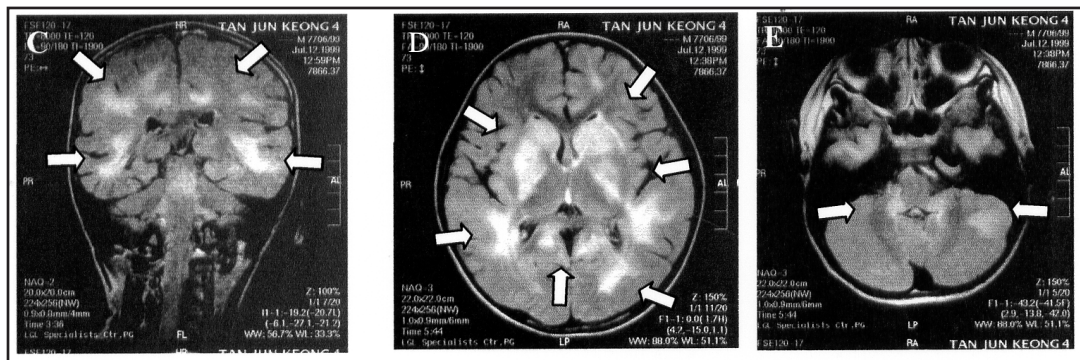
Treatment	No.	Outcome	No.	%
None	1	Disability (Severe)	1	100 %
IV Methylprednisolone	2	No Disability	2	Treatment outcome: No Disability 75 %
		Disability	0	
IV Immunoglobulins	1	No Disability	1	Death 25 % *
		Disability	0	
IV Methylprednisolone & IV Immunoglobulins	1	Death	1	

\* Death from complications of treatment, not disease

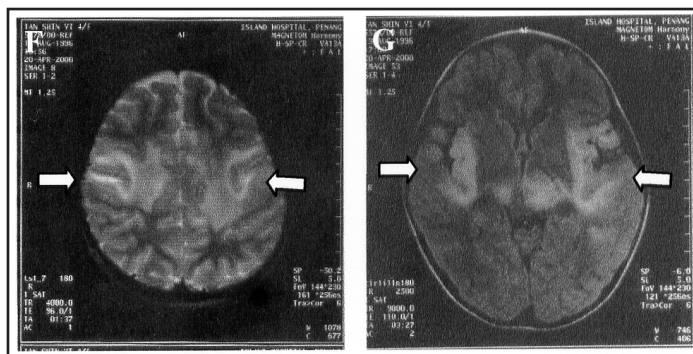
† This child had 3 episodes : 2 had no treatment, 1 treated with immunoglobulins;  
He has mild disability.



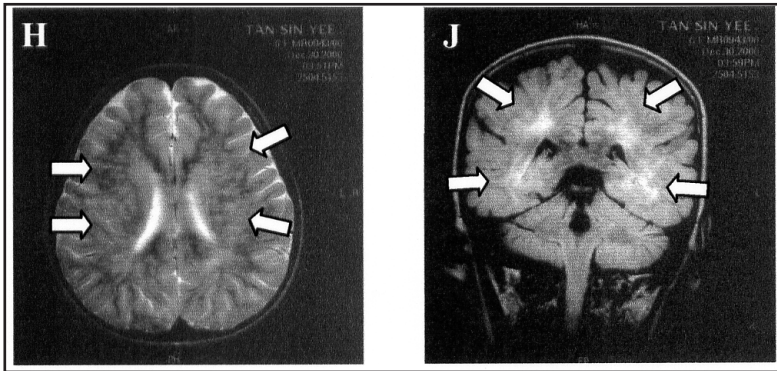
**Fig. 1: (Case 1) A, B: Magnetic resonance T2 weighted axial images showing hyperintense signals in the subcortical white matter of the right frontal and temporal lobes and in both cerebellar hemisphere (white arrows).**



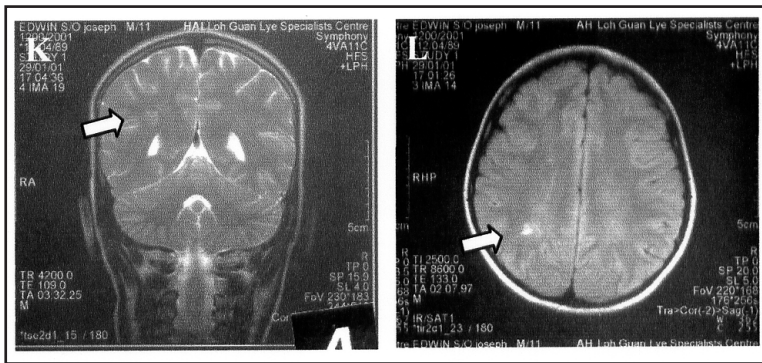
**Fig. 2: (Case 2): Magnetic resonance FLAIR coronal (C) and axial (D,E) images showing hyperintense signals in the subcortical and deep white matter of the right and left frontal, parietal and temporal lobes, basal ganglia, pons, and in the cerebellar hemispheres (white arrows).**



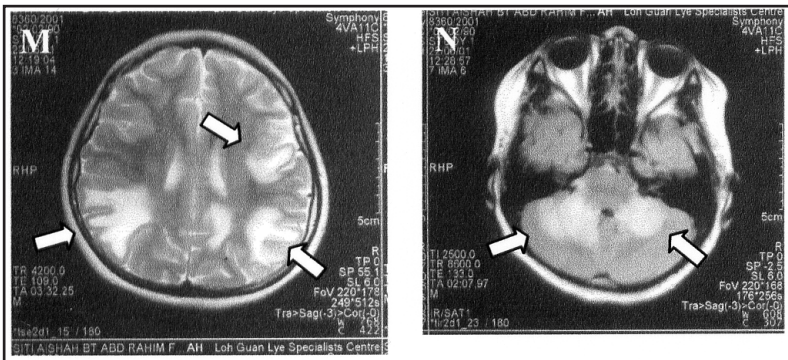
**Fig. 3: (Case 3): Magnetic resonance T2 weighted (F) and FLAIR (G) sequence axial images showing hyperintense signals in the white matter of both parietal and temporal lobes and well as in the basal ganglia (white arrows).**



**Fig. 4: (Case 4):** Magnetic resonance T2 weighted axial (H) and coronal FLAIR (J) sequence images showing diffuse hyperintense signals throughout the white matter of the cerebral cortex and cerebellum (white arrows).



**Fig. 5: (Case 5):** Magnetic resonance T2 weighted coronal (K) and axial FLAIR (L) sequence images showing subtle hyperintense signals in the white matter of the parietal lobes (white arrows).



**Fig. 6: (Case 6):** Magnetic resonance T2 weighted axial (M, N) images showing hyperintense signals in the white matter of the both frontal and parietal lobes, and well as in the cerebellar hemispheres (white arrows).

## Discussion

All the 6 children were from the state of Penang, which has a population of 413,800 children below the age of 15 years. Thus the crude annual incidence of ADEM in Penang is 0.58 per 100,000 children below the age of 15 years. This figure is probably an underestimate. Awareness of the condition is poor and some children with neurological disorders are managed at private hospitals and not seen at our centre.

Table I gives a summary of patient characteristics. A prodromal illness was seen in only three children. None had immunisations in the recent past. The prodrome may have been missed in the others or not specifically sought during history taking. The commonest prodrome is usually an upper respiratory tract infection or a non-specific febrile illness<sup>9</sup>, and may have been easily forgotten if mild.

Tables II and III give a summary of the presenting symptoms and signs. 75% of the children presented with fever and seizures, and 50% had altered sensorium. Two children had status epilepticus. The other symptoms reported were headache, vomiting, aphasia, visual disturbances, unsteadiness, mood changes, urinary incontinence and diarrhoea. Altered sensorium, focal cranial nerve and motor involvement, and cerebellar signs were prominent findings on physical examination. All the children had an abnormal neurological examination.

ADEM may present with any form of focal neurological deficit, reflecting the area of involvement in the central nervous system. There are reports of patients presenting with isolated psychosis, hypersomnia or urinary incontinence in the literature<sup>16,17,18</sup>. In our series, the diagnosis was made primarily on clinical features and characteristic changes of focal or multifocal demyelination in the central nervous system on magnetic resonance imaging. Cerebrospinal fluid examination proved helpful though assays of myelin basic protein were not performed as this is not currently available in Malaysia.

The children who presented with fever, altered sensorium and seizures were all initially managed as having encephalitis. Initial cranial CT scans were normal, and MRI scans done later revealed abnormalities. It is noteworthy that initial MRI scans may be normal<sup>20</sup>, as seen in case no.3.

With the exception of case no. 5, all children had florid bilateral white matter involvement. Basal ganglia and thalamic lesions were present in two of our children. Involvement of the deep gray matter feature prominently in patients in two recent paediatric series<sup>9,10</sup>; one author attributes a poorer outcome when these are present.

Case no. 2 had recurrent episodes of acute demyelination involving different areas of the central nervous system. This is termed multiphasic disseminated encephalomyelitis (MDEM)<sup>13</sup>. This is an unusual variant that must be differentiated from recurrent ADEM and multiple sclerosis. The former is defined as recurrence of similar symptoms and signs occurring more than a month after the resolution of the previous episode<sup>14</sup>. There are no new areas of pathology seen on serial neuroimaging. Multiple sclerosis has a multiphasic course with recurrent demyelination (dissemination in time and place) typically affecting the infratentorial, juxtacortical and periventricular areas, or the spinal cord<sup>19</sup>. The presence of oligoclonal bands in the spinal fluid is expected, and persistent. In the rare instance that oligoclonal bands are identified in a child with MDEM, they are transient<sup>13</sup>. This patient had no oligoclonal bands in his spinal fluid, although he had evidence of persistent abnormalities on visual evoked potentials. The white matter signal changes persisted on MRI even though he returned to normal functioning in between episodes. White matter changes in ADEM have been reported to persist for a few years<sup>21</sup>. This patient now has developed afebrile generalised tonic clonic seizures and has mild dyslexia. These could possibly be attributed to sequelae from MDEM.

Table IV gives a summary of treatment and outcome. The child with MDEM had three episodes of ADEM, only one of which was treated. He has mild disability. The child that was not treated has severe disability, whereas three out of the four (75%) of the treated patients have no disability. The other child who was treated succumbed to complications of treatment, and not the disease.

The treated children in our series received either methylprednisolone or immunoglobulins. The numbers are too small to compare the treatment options. There have been no trials to compare treatment modalities in ADEM. Anecdotal reports<sup>22,23</sup> and recently published case series<sup>9,10,12</sup> describe treatment with either high dose intravenous methylprednisolone or immunoglobulins. Plasmapheresis is limited to use in adult patients<sup>24</sup>.



## Conclusion

Awareness concerning ADEM is still limited in Malaysia, leading to affected patients being treated as infective encephalitis. The early use of MR imaging in a child

with multifocal central nervous system involvement and characteristic spinal fluid findings will improve diagnostic accuracy. Early diagnosis and appropriate treatment may prevent long term neurological sequelae.

## References

- McAlpine D. Acute disseminated encephalomyelitis: its sequelae and its relationship to disseminated sclerosis. *Lancet* 1931; i: 846-52.
- Hung KL, Liao HT, Tsai ML. Postinfectious encephalomyelitis: etiologic and diagnostic trends. *J Child Neurol* 2000; 15(10): 666-70.
- Hartung HP, Grossman RI. ADEM: distinct disease or part of the MS spectrum? *Neurology* 2001; 56: 1257-260.
- Dale RC, Church AJ, Cardoso F, Goddard E, Cox TC, et al. Poststreptococcal acute disseminated encephalomyelitis with basal ganglia involvement and auto-reactive antibasal ganglia antibodies. *Ann Neurol* 2001; 50(5): 588-95.
- Ito S, Nezu A, Matsumoto C, Aihara Y, Yokota S. Acute disseminated encephalomyelitis and poststreptococcal acute glomerulonephritis. *Brain Dev.* 2002; 24(2): 88-90.
- Krishna KK, Mitra DK, Diwan AG, Bamnikar AA. Acute disseminated encephalomyelitis with typhoid fever. *J Assoc Physicians India* 1999; 47(10): 1017-9.
- Mohsen AH, McKendrick, MW, Green ST, Hadjivassiliou M, Romanowski C. Postmalaria neurological syndrome: a case of acute disseminated encephalomyelitis? *J Neurol Neurosurg Psychiatry* 2000; 68: 388-90.
- Oleszak OL, Wan LL, Legido A, Melvin J, Hardison H, et al. Presence of oligoclonal T cells in cerebrospinal fluid of a child with multiphasic disseminated encephalomyelitis following Hepatitis A virus infection. *Clin Diagn Lab Immunol* 2001; 8: 984-92.
- Tenenbaum S, Chamoles N, Fejerman N. Acute disseminated encephalomyelitis. A long term follow-up study of 84 pediatric patients. *Neurology* 2002; 59: 1224-231.
- Hynson JL, Kornberg AJ, Coleman LT, Shield L, Harvey AS, et al. Clinical and neuroradiologic features of acute disseminated encephalomyelitis in children. *Neurology* 2001; 56(10): 1308-12.
- Hung KL, Liao HT, Tsai ML. The spectrum of postinfectious encephalomyelitis. *Brain Dev* 2001; 23(1): 42-5.
- Schwarz S, Mohr A, Knauth M, et al. Acute disseminated encephalomyelitis: a follow-up study of 40 patients. *Neurology* 2001; 56: 1313-318.
- Khan S, Yaqub BA, Poser CM, Al Deeb SM, Bohlega S. Multiphasic disseminated encephalomyelitis presenting as alternating hemiplegia. *J Neurol Neurosurg Psychiatry* 1995; 58: 467-70.
- Cohen O, Steiner-Birmanns B, Biran I, Abramsky O, Honigman S, et al. Recurrence of acute disseminated encephalomyelitis at the previously affected brain site. *Arch Neurol* 2001; 58: 797-801 .
- Takata T, Hirakawa M, Sakurai M, Kanazawa I. Fulminant form of acute disseminated encephalomyelitis: successful treatment with hypothermia. *J Neurol Sci* 1999;165(1): 94-7.
- Nasr JT, Andriola MR, Coyle PK. ADEM: literature review and case report of acute psychosis presentation. *Pediatr Neurol* 2000; 22(1): 8-18.
- Sakakibara R, Hattori T, Yasuda K, Yamanishi T. Micturitional disturbance in acute disseminated encephalomyelitis (ADEM). *J Auton Nerv Syst* 1996 Sep 12; 60(3): 200-5.
- Kubota H, Kanbayashi T, Tanabe Y, Takanashi J, Kohno Y. A case of acute disseminated encephalomyelitis presenting with hypersomnia with decreased hypocretin level in cerebrospinal fluid. *J Child Neurol* 2002; 17: 537-39.
- McDonald WI, Compston DAS, Edan G. Recommended diagnostic criteria in multiple sclerosis: guidelines from

- the International Panel on the Diagnosis of Multiple Sclerosis. *Ann Neurol* 2001; 50: 121-27.
20. Honkaniemi J, Dastidar P, Kahara V, Haapasalo H. Delayed MR imaging changes in acute disseminated encephalomyelitis. *Am J Neuroradiol* 2001; 22(6): 1117-24.
  21. O'Riordan JI, Gomez-Anson B, Moseley IF, Miller DH. Long term MRI follow-up of patients with post infectious encephalomyelitis: evidence for a monophasic disease. *J Neurol Sci* 1999; 167(2): 132-6.
  22. Straub J, Chofflon M, Delavelle J. Early high-dose intravenous methylprednisolone in acute disseminated encephalomyelitis: A successful recovery. *Neurology* 1997; 49: 1145-147.
  23. Hahn JS, Siegler DJ, Enzmann D. Intravenous gammaglobulin therapy in recurrent acute disseminated encephalomyelitis. *Neurology* 1996; 46: 1173-174.
  24. Weinsheker B, O'Brien PC, Petterson TM, et al. a randomized trial of plasma exchange in acute central nervous system inflammatory demyelinating disease. *Ann Neurol* 1999; 46: 878-86.