

Biopsy-Proven Childhood Glomerulonephritis in Johor

J J Khoo, MPath*, S Pee, MRCP**, B Thevarajah, MRCP***, Y C Yap, MRCP**, C K Chin, MRCP****

*Department of Pathology, **Department of Paediatrics, ***Department of Medicine, Sultanah Aminah Hospital, 80100 Johor Bahru, ****Medical Specialist Centre, Johor Bahru

Summary

Background: There has been no published study of biopsy-proven childhood glomerulonephritis in Malaysia.

Objectives: To determine the pattern of childhood glomerulonephritis in Johor, Malaysia from a histopathological perspective and the various indications used for renal biopsy in children.

Materials and Methods: Retrospective study was done of all renal biopsies from children under 16 years of age, received in Sultanah Aminah Hospital, Johor between 1994 and 2001. The histopathological findings were reviewed to determine the pattern of biopsy-proven glomerulonephritis. The indications for biopsy, mode of therapy given after biopsy and the clinical outcome were studied.

Results: 122 adequate biopsies were received, 9 children had repeat biopsies. Of the 113 biopsies, minimal change disease formed the most common histopathological diagnosis (40.7%) while lupus nephritis formed the most common secondary glomerulonephritis (23.0%). The main indications for biopsy were nephrotic syndrome (50.8%), lupus nephritis (25.4%) and renal impairment (13.1%). The mode of therapy was changed in 59.8% of the children. Of 106 patients followed-up, 84 children were found to have normal renal function in remission or on treatment. 4 patients developed chronic renal impairment and 16 reached end stage renal disease. Five of the 16 children with end stage disease had since died while 11 were on renal replacement therapy. Another 2 patients died of other complications.

Conclusions: The pattern of childhood GN in our study tended to reflect the more severe renal parenchymal diseases in children and those requiring more aggressive treatment. This was because of our criteria of selection (indication) for renal biopsy. Renal biopsy when performed appropriately in selected children may not only be a useful investigative tool for histological diagnosis and prognosis but may help clinicians plan the optimal therapy for these children.

Key Words: Childhood, Glomerulonephritis, Renal biopsy, End stage renal failure

Introduction

Percutaneous renal biopsy is a valuable tool in the management of renal parenchymal diseases. However, it is generally used more selectively in the paediatric

population. This is because of the general good outcome of many renal diseases in children.

There has been no published study of biopsy-proven glomerulonephritis in children in Malaysia. This study

This article was accepted: 20 September 2003

Corresponding Author: Khoo Joon Joon, Department of Pathology, Hospital Sultanah Aminah, 80100, Johor Bahru

aims to determine the pattern of childhood renal diseases in Johor from a histopathological perspective and the various indications used for renal biopsy in children. It also studies the influence of renal biopsy on therapeutic decisions and the clinical outcomes of the children. Although biopsy-proven renal diseases may not reflect the true spectrum of renal diseases, it gives an insight to the clinically significant renal diseases that may or may not require a change in the mode of therapy.

Materials and Methods

A retrospective study was undertaken of all renal biopsies performed on native kidneys of children under the age of 16 years, received in Department of Pathology, Sultanah Aminah Hospital, Johor (HSA, JB) between 1st January 1994 and 31st December 2001. Only renal biopsies that were considered adequate were included. The biopsy was adequate if a minimum of 5 glomeruli¹ was seen in the formalin fixed tissue. Percutaneous renal biopsies under ultrasound guidance were obtained by attending nephrologists or paediatric nephrologists. Specimens for light microscopy were fixed in 10% buffered formalin while fresh tissues received were submitted for immunofluorescence studies. Formalin fixed tissues were processed and sectioned at 1 to 2 micron thickness. These sections were stained with Haematoxylin-eosin, Periodic acid Schiff (PAS), silver methanamine (PAAG), Martius scarlet blue and Masson's trichrome. For immunofluorescence (IF) studies, fresh tissues were sectioned with a freezing microtome and stained for immunoreactivity against IgG, IgA, IgM, C3, C4, C1q and fibrinogen, using the fluorescein-labelled specific anti-sera. Immunoperoxidase staining of the paraffin embedded tissue was done when there was no tissue submitted for IF study or where no glomerulus was present in the frozen section. These sections were stained for immunoreactivity against IgG, IgA, IgM, C3, C4 and fibrinogen.

The histopathological findings were reviewed to determine the pattern of biopsy-proven glomerulonephritis in children. For cases of lupus nephritis: the histological grading by WHO classification² was used and the activity and chronicity indices were computed according to the criteria as proposed by Austin³. The clinical records of the patients (where available) were studied. The demographic data, indications for biopsy and their clinical presentations were analysed. The modes of

therapy given after renal biopsy and the final clinical outcome of these children at their last follow-up were also studied.

Results

One hundred and forty three renal biopsies were done between 1994 and 2001. Nineteen biopsies were inadequate and 2 were performed on transplanted kidneys. These were excluded. Hence, a total of 122 biopsies with adequate renal tissue received from 113 children were suitable for our study. Nine children had repeat biopsies done over the period studied. One hundred and four biopsies in the study had adequate renal tissue for immunofluorescence studies. Immunoperoxidase staining was done instead for the 18 remaining cases.

Demographic Profile:

The ages of the children at the time of biopsies ranged from 1 year to 15 years 10 months. Figure 1 shows the age distribution of these children at the times they had their first renal biopsies. The majority of the children (43.4%) were in the age group between 7 and 12 years old. There was a male predominance with 72 boys and 41 girls. The ethnic distribution of the patients was: Malays 68.1%, Chinese 24.8%, and Indians 7.1%. This was similar to the pattern of distribution of patients who attended the paediatric clinic at HSA, JB during the study period. The ethnic distribution for patients attending the paediatric clinic was: Malays (62.2%), Chinese (26.0%), Indians (11.1%) and other races (0.7%).

Histological Pattern:

Fifty-seven out of the 113 children (50.4%) had primary glomerulonephritis (GN). There were 46 cases (40.7%) of minimal change disease. These formed the most common entity in the primary glomerulonephritis followed by focal segmental glomerulosclerosis (5.3%) and membranous glomerulonephritis (4.4%). There were 26 cases of lupus nephritis (23.0%). Twenty-two out of 26 cases (84.6%) were diffuse proliferative glomerulonephritis (WHO classification: Type IV). Lupus nephritis formed the most common group in the secondary glomerulonephritis followed by post-infectious glomerulonephritis (8.0%), Henoch-Schonlein nephritis (4.4%) and IgA nephropathy (4.4%). There were 3 cases (2.7%) of rapidly progressive glomerulonephritis (RPGN); one of which was secondary to post-infectious GN. Haemolytic uraemic syndrome (HUS) formed another 1.8% of the

cases. The other types of renal diseases together constituting 5.3% of the biopsies included 2 cases of acute tubular necrosis, a case each of mesangiocapillary GN, focal proliferative GN, chronic glomerulonephritis and renal involvement by acute leukaemia. Nine children had repeat biopsies done. Among them were 4 children with minimal change disease: 3 to determine whether there were cyclosporin toxicity after 2 years of treatment while the other case had nephrotic syndrome with frequent relapses. The histology of all these four repeat biopsies remained as minimal change disease. In addition to the primary glomerular lesion, one of these cases had features of cyclosporin toxicity. Five children with systemic lupus erythematosus (SLE) had biopsies repeated: 4 had deterioration of renal function while the other case had a 'full-blown' clinically active lupus with severe nephrotic syndrome. All 5 repeat biopsies of the SLE children did not show any change in classification of the renal lesions but 4 of them showed deterioration in their chronicity indices. Table I shows the histological patterns of the renal biopsies of 113 children.

Indications for Renal Biopsy:

The indications for biopsy including repeat biopsies (n=122) in our study were:

- a) nephrotic syndrome in 62 cases (50.8%). The children were either steroid-dependent, steroid-resistant or frequent relapsers. Of the 62 cases, 4 had nephrotic syndrome with atypical features which included hematuria.
- b) evidence of renal involvement in SLE children in 31 cases (25.4%), of which 16 had nephrotic range proteinuria, 9 had active urinary sediments and 6 had renal impairment.
- c) non-nephrotic range proteinuria with atypical features such as hematuria, abdominal pain or rash in 5 cases (4.1%)
- d) recurrent gross hematuria in 5 cases (4.1%)
- e) renal impairment or renal failure in 16 cases (13.1%) and
- f) to determine cyclosporin toxicity after 2 years of treatment with cyclosporin in 3 cases (2.5%).

Modes of presentation:

Table II shows the modes of presentation of 113 children studied and the histology of the renal lesions. Nephrotic syndrome was the main presentation at the time of biopsies. Seventy-six patients presented with nephrotic syndrome. Most of the children (45) with nephrotic syndrome were found histologically to have minimal change disease. Fifteen patients with

nephrotic syndrome were lupus nephritis, 6 children were focal segmental glomerulosclerosis and 5 were membranous GN.

Nine patients with clinical features of systemic lupus erythematosus had active urinary sediments. Five children presented with hematuria, 2 of which were found to have IgA nephropathy. Renal impairment or renal failure (acute or chronic) was the presentation in 18 patients. Two of these children were lupus nephritis; another 6 were post-infectious glomerulonephritis while 3 were rapidly progressive glomerulonephritis: one of which was secondary to post-infectious GN.

Treatment and Clinical Outcome:

Of the 113 children biopsied, a total of 106 cases had clinical records available for review. The children were followed up for a period from 1 month to 7 years 8 months from the time of the first renal biopsy. The mean period of follow-up was 2 years 9 months.

Table III shows the therapeutic management after renal biopsy.

A change in the mode of therapy was instituted following the findings of 73 biopsy reports (59.8%). It was found that treatment modalities chosen was dependent on the histology of the renal lesions together with the present medication the patients were on, duration of treatment already given and the clinical state of the patients.

Sixty-four patients were started on immunosuppressives such as cyclosporin, alkylating agents such as cyclophosphamide, pulse methyl prednisolone or steroid, or a combination of these drugs. Most of these cases were either minimal change disease (31 cases) or lupus nephritis (25 cases). The histological grading of lupus nephritis, activity and chronicity indices helped influence the treatment modality chosen.

Another 9 children had their current treatment stopped after the biopsy findings while 14 others had some forms of treatment changed unrelated to the histological findings. They were clinical decisions that included giving anti-hypertensives, diuretics or fresh frozen plasma. Treatment was not known in 7 cases, as the clinical records were not available.

Of 106 children followed-up, renal function remained normal in 84 patients (79.2%). These children were

either in remission or on treatment. Four children (3.8%) developed chronic renal impairment while another 16 patients (15.1%) reached end stage renal failure (ESRF). The most common cause for renal failure was lupus nephritis (8 children), followed by post-infectious GN (3 children, one of which had RPGN). Other causes include FSGS, Henoch-Schonlein purpura, mesangiocapillary GN, membranous GN and chronic GN of unknown cause (one each). Five of these children had since died, secondary to causes related to the renal failure. The remaining 11 children with ESRF were either on continuous peritoneal dialysis (6 children) or haemodialysis (5 children).

Another 2 children died of other complications: one patient of acute complications of fulminant SLE during treatment while another of aspiration pneumonia from hypoxic ischaemic encephalopathy, with chronic renal impairment. Thus a total of 7 children (6.6%) died. Table IV shows the outcome of the children at their last follow-up.

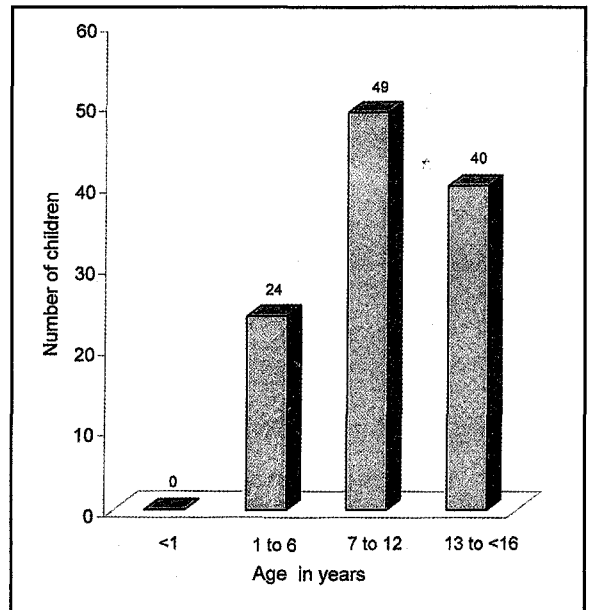


Fig. 1 : Age distribution of children at time of first biopsy (n=113)

Table I: The histological patterns of renal biopsies in children in Sultanah Aminah Hospital, Johor

Histology:	No. of cases (%)
Minimal Change disease	46 (40.7)
Membranous GN	5 (4.4)
Focal segmental glomerulosclerosis	6 (5.3)
Rapidly progressive GN	3 (2.7)
Lupus nephritis	26 (23.0)
Post-infectious GN	9 (8.0)
Henoch-Schonlein nephritis	5 (4.4)
IgA Nephropathy	5 (4.4)
Haemolytic Uraemic syndrome	2 (1.8)
Others	6 (5.3)
Total :	113 (100)

Table II: Modes of presentation (n=113)

Histology:	Nephrotic Syndrome	Proteinuria ^Φ	Hematuria	Active Urine Sediments [⊗]	Renal Impairment	Renal failure (acute or chronic)
Minimal Change disease	45		1			
Membranous GN	5					
Focal segmental GS	5 + 1*					
RPGN						3
Lupus nephritis	15			9	2	0
Post-infectious GN	1 + 1*		1		3	3
Henoch-Schonlein nephritis		5				
Ig A nephropathy	1 + 1*		2		1	
HUS			1 [∇]			1
Others [#]	1*				1	4
Total:	76	5	5	9	7	11

Φ Proteinuria of non-nephrotic range

⊗ SLE with active urine sediments

* Nephrotic syndrome with atypical features that included hematuria

∇ Clinical features suspicious of HUS

The other types of renal diseases included acute tubular necrosis, mesangiocapillary GN, focal proliferative GN, chronic GN and a case of renal involvement by acute leukemia.

Table III: Treatment modalities used after renal biopsy

Mode of therapy after each biopsy	Number of cases
No change	28
Start or change dosage of steroid	8
Pulse methyl prednisolone with or without cyclophosphamide	6
Start cyclophosphamide or / and cyclosporin with or without steroid	50
Stop treatment: steroid or cyclosporin	9
Other treatment unrelated to biopsy findings*	14
Unknown treatment given **	7
Total:	122

n=122

*Other forms of treatment included giving anti-hypertensives, diuretics or fresh frozen plasma

** Treatment given was not known as clinical records were not available.

Table IV: Outcome of Children

Histology:	Normal renal function [#]	Chronic renal impairment	ESRF-CAPD	ESRF-dialysis	Death	Unknown ^ψ
Minimal change disease	44					2
Membranous GN	3			1		1
Focal Glomerulosclerosis	4	1			1*	
RPGN	2				1*	
Lupus nephritis	14	1	4	2	2* + 1	2
Post-infectious GN	7			1	1*	
Henoch-Schonlein nephritis	4		1			
Ig A Nephropathy	4	1				
Haemolytic Uraemic syndrome	1				1	
Others	1	1	1	1		2
Total:	84	4	6	5	5* + 2	7

n= 113

#Normal renal function: in remission or on treatment

*Died secondary to causes related to end stage renal failure

ψUnknown as clinical records not available

Discussion

The pattern of renal diseases in children varies from country to country and centre to centre. This may be due to true variation in population but may also be partly due to different selection criteria used for biopsies in different centres as well as different referral patterns to the centres.

Minimal change disease (MCD) was seen in 40.7% of our patients. It formed the most common histopathological diagnosis in the paediatric population with renal disease. MCD was the most common cause of idiopathic nephrotic syndrome in children. This was comparable with many studies^{4,6} reported in nearby regions. On the other hand, membranous glomerulonephritis was an infrequent finding in children with nephrotic syndrome, unlike that found in adults. This was similarly reported in the findings of the International Study of Kidney Disease in Children⁷.

Lupus nephritis was the most common cause of secondary glomerulopathy. It formed 23.0% of all renal biopsies reported in children in our study. This was comparable with other studies of renal biopsies for all ages⁸⁻¹⁰ in Malaysia (between 18.4 to 31.0%) and for children in Singapore⁵ and Hong Kong⁶ (15.8 to 17.3 %). This reflected the common occurrence of SLE in the

Asian community, both in children and adult population. In our study, there were 16 Malays and 10 Chinese children with lupus nephritis with a predominance of females to males. The male to female ratio was 1: 2.25. This ratio reflected the female predominance in SLE patients.

Most of the histological findings of the lupus nephritis (84.6%) were diffuse proliferative glomerulonephritis (WHO classification: Type IV). These children required drastic modification of therapy. Alkylating agents such as cyclophosphamide, immunosuppressives such as cyclosporin, or pulse methyl-prednisolone were started in addition to the oral steroid. The activity index in the biopsy report helped the clinician gauge the activity of the disease and tailor their treatment accordingly. The chronicity index given helped estimate the extent of damage to the kidney and prognosticate the survival of the organ. Lupus nephritis was the most common cause of end stage renal failure in children in our study.

Focal segmental glomerulosclerosis (FSGS) is also of major clinical importance as it generally does not respond well to treatment and carries a fairly poor prognosis leading to renal failure. Although only 6 children in our study were diagnosed with FSGS but one died of end stage renal disease and another

developed chronic renal impairment. We also noted that the number of cases of FSGS (5.3%) in our study was slightly lower compared to other reported studies^{7,11-13} (6.9% to 31% of all renal biopsies in children) in different parts of the world. This may be due to true variation in different countries due to the different ethnic population, shown by the wide variation in different studies. However, it should be noted that in some studies^{14,15} many patients were found to have the lesions of FSGS only on their repeat biopsy. This was so as FSGS was often missed on biopsy. Repeat biopsies for patients with frequent relapsing nephrotic syndrome or with atypical features may increase the chances of picking up these cases.

IgA nephropathy was reported in 9.8 to 18.5% in patients of all ages in previous studies in Malaysia^{9,10}. In our study, there were only 5 children (4.4%) diagnosed with IgA nephropathy. This was largely due to the later age of onset of the disease. Children with persistent macroscopic hematuria were the most frequent presentation in IgA nephritis. This was the indication for renal biopsy in 3 out of 5 cases of IgA nephritis in our study. Atypical presentations of IgA nephritis included proteinuria, nephrotic syndrome or acute renal failure.

Changes in therapeutic modalities were seen in a large proportion of the children in our study after the renal biopsy. Renal biopsy findings played an important role in determining the appropriate therapy in patients with lupus nephritis, steroid-resistant and relapsing nephrotic syndrome. The changes in therapy modalities had probably helped change the course of clinical outcome of some of our patients.

The causes of ESRF in children differed markedly from that in adults. The Singapore Renal Registry¹⁶ reported the main causes of ESRF in children as

glomerulonephritis and congenital diseases. This probably reflected the picture seen in neighbouring Malaysia with a similar ethnic population.

In children, the choice of treatment modality for ESRF depended on the age of the patient and the availability of kidney donors. CAPD was used in the younger patients and haemodialysis in the older paediatric population. At present, organ transplantation (donor related or cadaveric) is not common in Malaysia due to lack of donors.

Conclusion

Despite the limitations due to bias referral and the different selection criteria used for biopsy, this study gave an overview and insight to the pattern of biopsy-proven renal parenchymal diseases in children in Johor, Malaysia. It also showed the various indications used for renal biopsy in children and the importance of renal biopsy not only as a useful investigative tool in defining the histological diagnosis and long term renal prognosis, but in deciding some of the therapeutic strategies used in some of these children. Thus, renal biopsy plays a significant role in the management of children with renal diseases.

Acknowledgements

We would like to thank Mr Chui Chor Sin and Miss Chin Cheau Wern for their assistance in data analysis, all the medical laboratory technicians in the Histopathology Unit with special reference to Puan Norzilah Mustapha and the paramedical staff of Paediatrics Unit and Haemodialysis Unit, Sultanah Aminah Hospital, Johor for their time and assistance.

1. Pirani CL. Evaluation of kidney biopsy specimens. In: Tisher CC, Brenner BM. *Renal Pathology with clinical and functional correlations*. Philadelphia: JB Lippincott, 1994: 85-115.
2. McCluskey RT. Lupus nephritis. In: Summers SC (ed). *Kidney pathology: Decennial*. New York: Appleton & Lange 1975: 456-9.
3. Austin HA III, Muenz LR, Joyce KM, Antonovych TT, Balow JE. Diffuse proliferative lupus nephritis: Identification of specific pathologic features affecting renal outcome. *Kidney Int* 1984; 25: 689-95.
4. Lai KN, Lai FM, Chan KW, Au TC, Tam A, Leung NK. Pattern of glomerulonephritis in Chinese population: The effect of renal biopsy on the therapeutic decision. *Aust Paediatr J* 1987; 23: 231-4.
5. Yap HK, Murugasu B, Saw AH et al. Pattern of Glomerulonephritis in Singapore Children-A Renal Biopsy Perspective. *Ann Acad Med Spore* 1989; 18(1): 35-9.
6. Lai FM, Lai KN, Chan KW, Au TC, Tong KL, Vallance-Owen J. Pattern of Glomerulonephritis in Hong Kong. *Pathology* 1987; 19: 247-52.
7. International Study of Kidney Disease in Children: Nephrotic syndrome in children: Prediction of Histopathology from clinical and laboratory characteristics at time of diagnosis. *Kidney Int* 1978; 13: 159-65.
8. Prathap K, Looi LM. Morphological patterns of glomerular disease in renal biopsies from 1000 Malaysian patients. *Ann Acad Med Singapore* 1982; 11: 52-6.
9. Looi LM. The pattern of renal disease in Malaysia. *Malays J Pathol* 1994; 16(1): 19-21.
10. Khoo JJ. Renal biopsies in Johor: a 7-year study. *Malays J Pathol* 2001; 23(2): 101-4.
11. Briganti EM, Dowling J, Finlay M et al. The incidence of biopsy-proven glomerulonephritis in Australia. *Nephrol Dial Transplant* 2001; 16: 1364-7.
12. Coppo R, Gianoglio B, Porcellini MG, Maringhini S. Frequency of renal diseases and clinical indications for renal biopsy in children. *Nephrol Dial Transplant* 1998; 13: 293-7.
13. Bonilla-Felix M, Parra C, Dajani T et al. Changing patterns in histopathology of idiopathic nephrotic syndrome in children. *Kidney Int* 1999; 55(5): 1885-90.
14. Southwest Paediatric Nephrology Study Group: Focal segmental glomerulosclerosis in children with idiopathic nephrotic syndrome. *Kidney Int* 1985; 27: 442-9.
15. Ahmad H, Tejani A. Predictive value of repeat renal biopsies in children with nephrotic syndrome. *Nephron* 2000; 84: 342-6.
16. Woo KT. The Singapore Renal Registry: An Overview. *Singapore Med J* 1993; 34: 157-63.