

Rhinosporidiosis Presenting as Recurrent Nasal Polyps

J J Khoo, MPath, K S Kumar, DpH

Department of Pathology, Hospital Sultanah Aminah, 80100 Johor Bahru

Summary

Rhinosporidiosis is a chronic granulomatous disease of the mucous membrane, predominantly of the nose and nasopharynx. It is uncommon in Malaysia but has been seen in immigrant workers from endemic areas like India and Sri Lanka. A case seen in Johor is reported here to highlight the need of awareness among clinicians at a time where there is increasing numbers of immigrant workers in our country.

The causative organism of this disease is *Rhinosporidium seeberi*, which is found in stagnant waters. Sporangia and endospores of *R. seeberi* are seen in the granulomatous polypoidal lesions. The patients commonly present with epistaxis and nasal blockage. Complete excision is the treatment of choice for this disease. Recurrences are common despite anti-microbial treatment.

Key Words: Rhinosporidiosis, Recurrent nasal polyps, Immigrant worker

Introduction

Rhinosporidiosis is an infective chronic granulomatous disease that is characterised by polypoidal lesions, predominantly of the nasal mucous membrane and the conjunctiva. It is endemic in India, Sri Lanka and East Africa but uncommon in Malaysia. However, with an increasing number of immigrant workers from these countries coming to Malaysia, clinicians should be aware of this disease entity especially in this group of patients presenting with nasal masses causing obstruction and epistaxis. This paper describes a case of nasal rhinosporidiosis presenting as recurrent nasal polyps and highlights the disease entity.

Case Report

A 27-year-old immigrant worker from Bangladesh presented to the outpatient clinic with a 6-month history of nasal obstruction, which was associated with epistaxis and intermittent post-nasal drip.

Three years prior to this presentation, he had similar symptoms for which he underwent nasal polypectomy. The specimen was then reported histologically as Rhinosporidiosis. The patient was asymptomatic in-between these episodes. The rest of the medical history was unremarkable. The patient was a factory worker in Malaysia for the past 4 years.

This article was accepted: 5 October 2002

Corresponding Author: Khoo Joon Joon, Consultant Pathologist, Department of Pathology, Hospital Sultanah Aminah, 80100, Johor Bahru

Anterior rhinoscopy and nasal endoscopy showed a fairly large friable fleshy mass, measuring 2.5 cm in diameter, arising from the lateral wall of the right nasal cavity. The mass was excised endoscopically and sent for histopathological examination.

Histopathological examination

Sections of the mass showed polypoidal structures that were covered by stratified squamous epithelium with epithelial hyperplasia. The underlying stroma showed multiple granulomas that comprised of epithelioid cells, lymphocytes, plasma cells, neutrophils and a few giant cells.

There were multiple sporangia full of endospores in different stages of development in the granulomatous stroma (Figure 1 and 2). This was diagnosed histologically as Rhinosporidiosis.

Follow-up:

One month after the excision, a small polyp was found on nasal endoscopy on follow-up. This was removed with a pair of forceps but was not sent for histopathological examination. The patient was given Itraconazole 200mg daily for 2 weeks. Eight months later, a repeat nasal endoscopy showed no obvious mass.

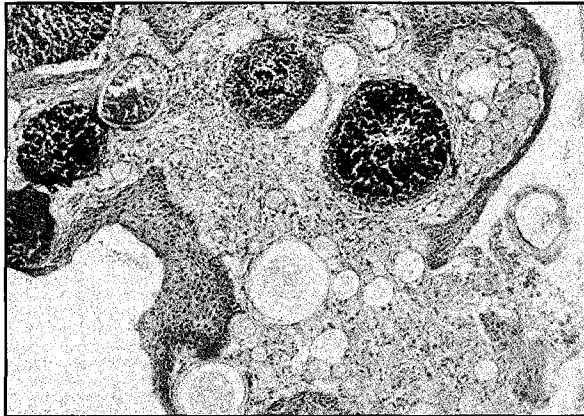


Fig. 1: Shows polypoidal structures with granulomatous inflammation and multiple sporangia full of endospores in different stages of development. (Haematoxylin and eosin stain: original magnification x 100).

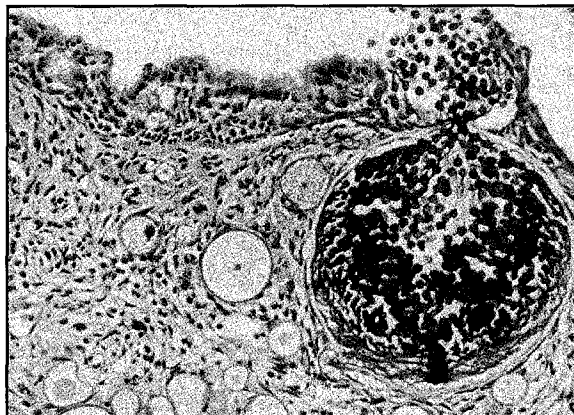


Fig. 2: Shows a large mature sporangium with numerous endospores released. (Haematoxylin and eosin stain: original magnification x 200).

Discussion

Rhinosporidiosis is caused by *Rhinosporidium seeberi*. Guillermo Seeber, an Argentinean, was the first person to describe the organism when he removed a nasal polyp from an agricultural worker in 1896. He reported his findings in his doctoral thesis in medicine, which was published in 1921. However, it was Ashworth who coined the term *Rhinosporidium seeberi* in 1923. Since then, more reports have appeared and the epidemiology of the disease became clearer.

Rhinosporidiosis is commonly seen in India, Sri Lanka and East Africa but not in Malaysia. The few cases of nasal rhinosporidiosis diagnosed here were mostly 'imported' cases. They were seen in immigrant workers who were either from the above-mentioned countries or in patients who gave a history of having visited endemic areas. Our patient was an immigrant worker from Bangladesh.

Traditionally, rhinosporidiosis was thought to be a mycotic (fungal) infection. However, recent molecular studies have shown conflicting results. The organism, *Rhinosporidium seeberi*, may either be a *cyanobacterium*¹, that is a bacterium capable of photosynthesis; or a *protist*², a novel clade of parasite that infest fish and amphibians. This issue of uncertain taxonomy has remained unresolved. However, most microbiologists classify *Rhinosporidium seeberi* as a fungus. It is also generally agreed that this causative agent is found in water in the ponds and rivers in endemic South India and Sri Lanka. A few in vitro studies have shown that watery substances visibly stimulate the mature sporangia of *R. seeberi* to discharge the endospores. This supports the epidemiological studies that linked this pathogen with the wet environments. In their study of one hundred and thirty-nine cases of rhinosporidiosis diagnosed histologically, Ratnakar³ et al found that nasal rhinosporidiosis was common among males who bathed in stagnant ponds. Most of the patients were in their second to fourth decade of life.

Rhinosporidiosis predominantly affects the mucous membrane of the nose and nasopharynx. It can also be found in the conjunctiva, larynx, trachea, skin and genitourinary tract but these are rare occurrences. Tumoral rhinosporidiosis is very rare but has been reported. These soft-tissue masses were result of systemic spread of the infection.

In the more common nasal rhinosporidiosis, there are formations of papillomatous and polypoidal lesions. The most common presenting symptom is epistaxis followed by nasal blockage. Our patient had enlarged nasal polyps that caused nasal blockage and also epistaxis.

Diagnosis of the disease is usually made histologically on biopsy specimens from these polypoidal lesions on the mucous membranes. Infected areas show granulomatous inflammation with numerous large sporangia and endospores of *Rhinosporidium seeberi*. The sporangia measure up to 350 µm in diameter and have a cell wall thickness of about 5 µm. The sporangia contain multiple endospores. These endospores develop in the sporangia and are released upon maturity (Figure 2).

The treatment of choice is surgery but it has risk of recurrences. Additional treatment options that have been described included electric cauterisation of the base of the nasal polyp but this did not show any significant reduction in recurrences. Anti-microbial therapy also may not be very effective. However, some reports⁴ have suggested that dapson supplement after surgical treatment may reduce the recurrences and prevent its spread. Repeated surgical removal may be necessary when recurrences occur. Our patient had surgical removal of a nasal polyp 3 years ago but it recurred and warranted another excision. He was given anti-fungal treatment. Eight months following the repeat excision, our patient was symptom-free and had no endoscopic evidence of residual disease. However, rhinosporidiosis is a chronic inflammatory disease that has a tendency

to recur despite medical and / or surgical treatment and may persist for decades. Thus, long term follow-up is advisable.

In summary, rhinosporidiosis is a differential diagnosis to be considered in patients from endemic region who present with nasal masses causing obstruction and epistaxis.

References

1. Ahluwalia KB. Culture of the organism that causes rhinosporidiosis. *J Laryngol Otol* 1999;113: 523-28.
2. Herr RA, Ajello L, Taylor JW, Arseculeratne SN, Mendoza L. Phylogenetic analysis of *Rhinosporidium seeberi*'s 18S small subunit ribosomal DNA groups this pathogen among members of the protactistan Mesomycetozoa clade. *J Clin Microbiol* 1999; 37: 2750-4.
3. Ratnakar C, Madhavan M, Sankaran V, Veliath AJ, Majumder NK, Rao VA. Rhinosporidiosis in Pondicherry. *J Trop Med Hyg* 1992; 95(4): 280-3.
4. Venkateswaran S, Date A, Job A, Mathan M. Light and electron microscopic findings in rhinosporidiosis after dapsone therapy. *Tropical-Medicine & International Health* 1997; 2(12): 1128-32.