

Melioidosis of the Head and Neck

W K Lim, FRCSEd*, G S Gurdeep, MS (ORL-HNS)*, K Norain, MRCPATH**, *ENT Department, **Pathology Department, Hospital Ipoh, Ipoh, Perak

Summary

Melioidosis is a potentially deadly infection that can affect any organ system. Reports of melioidosis of the ENT/head and neck region are relatively uncommon. Four cases are presented: (i) parotid abscess evolving into necrotising fasciitis, (ii) acute sinusitis and parapharyngeal cellulitis resulting in upper airway obstruction, (iii) acute suppurative lymphadenitis (iv) and chronic suppurative otitis media causing meningoencephalitis. Three of the four cases are believed to be unique, as a literature review of melioidosis in ENT/head and neck is also presented. Some practical issues of management are also discussed. Not suspecting melioidosis does not change contemporary empirical broadspectrum antibiotic therapy. The value of suspicion or on confirmation of diagnosis lies in anticipating and planning for rapid change.

Key Words: Melioidosis, Parotid Abscess, Necrotising fasciitis, Sinusitis, Suppurative lymphadenitis, Chronic suppurative otitis media

Introduction

In a world gripped by the recently emerging infectious diseases, like Ebola, HIV, Creutzfeld-Jakob Disease and Nipah, melioidosis is a relative unknown, but is just as deadly. For those who know, "melioidosis" conjures up the image of walking bare feet through paddy fields of Southeast Asia. It is a blanket term for all diseases caused by the erstwhile *Pseudomonas pseudomallei*, now known as *Burkholderia pseudomallei*. Terms such as "great mimicker" and "protein manifestations" attest to *B. pseudomallei*'s variability in presentation. The commonest presentation is pneumonia, but there are documented cases of involvement of skin, liver, spleen, the urogenital system and the central nervous system.

A literature review found only a few cases reported of melioidosis of the ENT/Head and Neck region. The following are four cases encountered by the authors. All were confirmed on culture or serology to be *Burkholderia pseudomonas*.

Case 1 Parotid gland abscess progressing to necrotising fasciitis

A 64 year old Malay man presented with a week's duration of right parotid area pain and swelling. There was trismus and fever. Examination revealed a right parotid swelling consistent with an abscess. Trismus limited oral examination, but thick, purulent secretions were seen. CT scan

This article was accepted: 14 October 2001

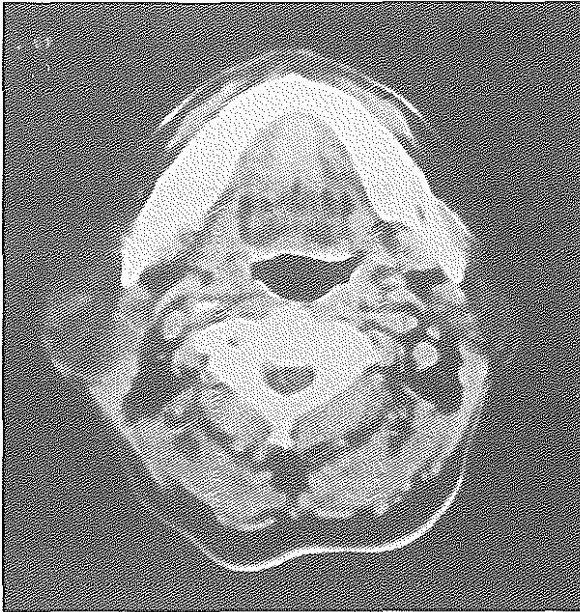


Fig. 1: CT scan of R parotid abscess.

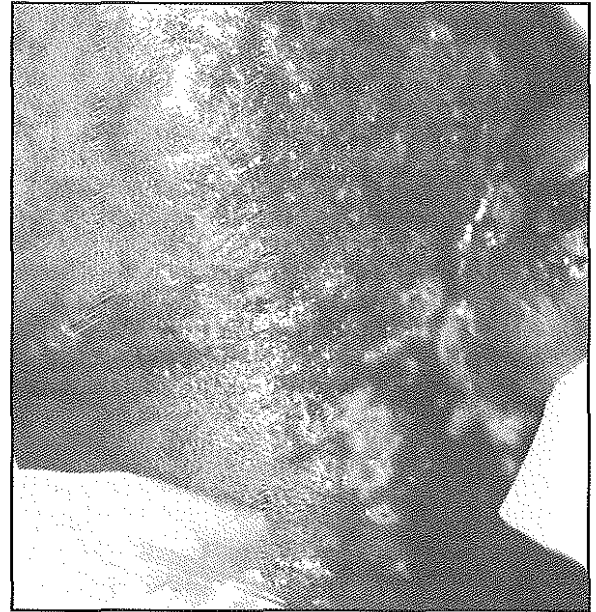


Fig. 2: Posterior view of R scalp necrotising fasciitis.

confirmed a parotid gland abscess with extension into the parapharyngeal space (Fig. 1). He was also a newly diagnosed diabetic.

An emergency incision and drainage of the parotid abscess was performed. He was continued on broadspectrum antibiotics and his condition improved over the next forty-eight hours, with his fever and trismus settling. However, he deteriorated soon after. The skin over the right periauricular, temporal and occipital areas progressively became dusky, swollen and boggy (Fig. 2). He also became septicaemic. Pus from the abscess grew *B. pseudomallei* on culture.

A diagnosis of necrotising fasciitis was made, whereupon emergency debridement of all necrotic skin down to the pericranium was done (Fig. 3). Despite extensive debridement and high dose intravenous ceftazidime with ICU support, the patient remained very ill. His diabetes

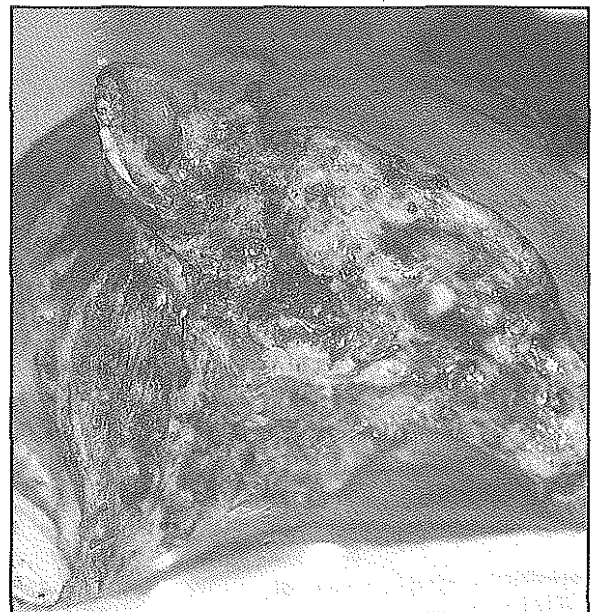


Fig. 3: Necrotising fasciitis post debridement.

remained unstable, and he developed renal failure. He succumbed to a chest infection three weeks after admission.

Case 2

Upper airway obstruction due to acute pansinusitis and parapharyngeal cellulitis

A 24 year old Malay woman presented with a week's duration of fever, feeling unwell, dyspnoea and stertor. She was then at twenty-four weeks of pregnancy. Significantly, she had a three year history of systemic lupus erythematosus treated with Prednisolone 50mg daily. On examination, she was Cushingoid in appearance, toxic-looking and severely dyspnoeic, with loud stertor. She had bilateral absolute nasal obstruction. Oropharyngeal examination was limited by trismus. An urgent CT scan revealed soft tissue masses in the nose and nasopharynx, pansinusitis, and concomitant parapharyngeal and pterygoid space cellulitis.

Emergency tracheostomy was performed. Upper airway endoscopy revealed the nose filled with polyps and mucopus. There was profuse postnasal drip of mucopus, forming crusts that peeled off easily from normal tonsils. The oropharyngeal lumen was narrowed and its mucosa congested. The larynx was normal.

Serial blood cultures grew *B. pseudomallei*, for which she was continued on intravenous ceftazidime, which lasted a month. Nevertheless, she developed pneumonia but did recover somewhat, only to become septic again a few weeks after discharge and finally succumbed. The foetus was stillborn just before her demise.

Case 3

Cervical acute suppurative lymphadenitis

A 35 year old Indian man presented with two weeks duration of an enlarging left neck swelling and fever. Significantly, he had had diabetes

mellitus for four years. He was also invalidated from employment because of a history of melioidosis, which first manifested as a splenic abscess three years before and had recurred twice prior to the current presentation.

On this presentation, examination revealed a rather well looking man. He had a left submandibular swelling which was firm and inflamed. Absence of both trismus and median shift of the lateral wall of the oropharynx suggested an abscess superficial to the deep investing fascia of the neck, consistent with suppurative lymphadenitis.

Emergency incision and drainage of the abscess was performed. A pus swab culture confirmed *B. pseudomallei*. He was continued on prolonged intravenous ceftazidime. After a month, he was discharged well and healthy.

Case 4

Meningoencephalitis from chronic suppurative otitis media

A 21 year old Orang Asli male presented with about two weeks of fever, productive cough and right sided weakness. There were associated symptoms of headache, unsteady gait and double vision. On examination, he was detached and disoriented, with right hemiparesis. A chest X-ray showed right midzone opacities consistent with bronchopneumonia. He was commenced on intravenous ceftazidime. The patient had a stormy next two months, which included intubation and ventilation after the first week and he developed tonic-clonic seizures.

Initial CSF and blood cultures were negative, but serial sputum cultures occasionally grew colonising *Pseudomonas* species without antibiotic sensitivities tested. It was only when atypical infections were considered did a clear picture emerge. The melioidosis indirect haemoagglutination (IHA) test was >1:1280, i.e.

positive, which meant the diagnosis of melioidosis meningoenzephalitis and pneumonia was confirmed.

After about two months of IV cefazidime, a repeat IHA disclosed a result of 1:40, i.e. negative, implying improvement, but the right hemiparesis persisted. It was at this convalescent stage that the patient complained of a chronic left ear discharge that had preceded the current event. He did not complain of vertigo, deafness or otalgia. The right ear looked normal.

Examination revealed an attic perforation of the left tympanic membrane. There was copious mucopus with keratin debris seen in the perforation. Left ear pus grew *Pseudomonas aeruginosa*. Findings during a left modified radical mastoidectomy were consistent with that of a cholesteatoma that extended from the epitympanum into the mastoid cavity. The tegmen tympani was eroded exposing the dura mater. The ossicles were eroded and the facial nerve was unexposed.

Postoperatively, the patient's condition was stable. The patient was discharged soon after.

Background of melioidosis

The history, microbiology and epidemiology of melioidosis are described in greater detail below and in the introduction¹.

History

The entity of melioidosis was first described in Rangoon in 1912, as a disease similar to glanders (a contagious equine infection caused by *Pseudomonas mallei*). The causative bacteria was isolated in 1913 at what was then Malaya's Institute of Medical Research. The term "melioidosis" is of Latin derivation, and was coined in 1921.

Epidemiology

The infectious agent has undergone several name changes since it was isolated in 1913, the last to *Burkholderia pseudomallei*. It is an oxidase-positive gram-negative rod. It is found in soil and water of certain endemic tropical areas of Southeast Asia (especially Thailand, Malaysia and Singapore) and Northern Australia, but in recent years many reports have surfaced from temperate climes and the Western Hemisphere. Infection is not restricted to humans, with rodents and domestic animals also found to be potential victims.

The disease in humans arises after the bacterium gains entry into the body, through contact of defective skin with soil or water, inhalation and ingestion. The incubation period reportedly ranges between 2 days to months or years. Certain pre-existing medical conditions can predispose to infection, those that compromise immunity, such as diabetes mellitus. But there are many patients without any apparent underlying medical conditions. However, severity of infection is influenced by immunocompetence.

Clinical presentation

Clinical presentation of melioidosis can be grouped into four, roughly corresponding to severity on infection:

- a). The most severe is acute septicaemia, with metastatic lesions in skin, muscle, bone and joints.
- b). Localised infection, either acute suppurative or chronic granulomatous.
- c). Prolonged fever without any apparent site of infection.
- d). The biggest group by far, the asymptomatic group, where infection may be subclinical, or obvious infection may only arise after a lengthy dormant period (the time-bomb).

Investigations

Investigations to confirm a diagnosis of melioidosis are as for any other bacterial infection. The gold standard is the positive culture. Serological tests are generally reliable but need to be interpreted according to local conditions. An example is the indirect haemagglutination test (IHA). Some centres internationally use polymerase chain reaction (PCR) kits to detect the presence of *B. pseudomallei*.

Treatment

The treatment of melioidosis has to depend on its presentation, with surgical intervention possible but the cornerstone remains appropriate and prolonged antibiotics. For initial intravenous therapy, different regimens exist, but the most effective combinations contain ceftazidime or imipenem. Subsequent post-acute oral antibiotics taken for three to six months are needed to prevent relapse.

Discussion of above Case Reports

Given that melioidosis can affect any part of the body, it is somewhat surprising that there have not been many reports involving the ENT/head and neck region. As far as one can tell, the earliest report was more than twenty years ago from the authors' hospital. This was a case of a young man who had melioidosis of the liver and lung successfully treated, only on review found to have melioidosis exudative tonsillitis². More recently a similar case of oro-and nasopharyngitis in a healthy 14 year old girl was documented³.

Case 1 described an acute parotid and parapharyngeal abscess that evolved into necrotising fasciitis and septicaemia. Melioidosis parotitis is common in children in Thailand⁴. Melioidosis parapharyngeal abscess has been reported⁵. But this may be the first case reported of necrotising fasciitis in the head and neck region due to melioidosis.

Case 2 was acute pansinusitis that also involved cellulitis in the parapharyngeal and pterygoid spaces. This resulted in the upper airway above the larynx to be narrowed, resulting in stertor. Once again, this is thought to be the first report of melioidosis causing upper airway obstruction. However, melioidosis acute sinusitis has been described previously⁶, of a middle-aged diabetic who had acute ethmoidal and frontal sinusitis with orbital complications.

Case 3 was an acute suppurative lymphadenitis. This has previously been reported⁷, where five of a series of 35 children had suppurative lymphadenitis. Another report⁸ described a chronic lymphadenitis that imitated tuberculosis.

Case 4 illustrates intracranial spread of infection from the middle ear. There has been a prior report of melioidosis chronic suppurative otitis media⁹. In Case 4, the evidence supports the source of infection from the left ear as the patient had right hemiparesis. The *Pseudomonas aeruginosa* that was cultured from the left ear probably replaced the eliminated *Burkholderia pseudomallei*. There have been many reports of melioidosis of the central nervous system¹⁰⁻²¹, but none of them indicate the source as Case 4 does, so it is believed this to be the first documentation of melioidosis spreading from ear to brain.

The above four cases share some characteristics of melioidosis. Firstly, there was no typical clinical picture. Presenting symptoms were non-specific, with each case resembling a more common infection. In Cases 1, 2 and 4 more common organisms were the early suspects. Melioidosis was not suspected until after cultures or serological tests were positive. It was only in Case 3 where a previous positive history of melioidosis gave a clue to the current infection.

The second of characteristic of melioidosis is it can be missed not only during clinical presentation, but even with microbiological culture. *B. pseudomallei* is a slow-growing organism, so cultures may be interpreted as

negative. In Case 4, all specimen cultures, whether CSF, sputum and ear pus were negative for *B. pseudomallei*. Perhaps the *Pseudomonas* species dismissed as colonizers were truly *B. pseudomallei*. Antibiotic sensitivities may have given a clue, as *B. pseudomallei* is generally resistant to gentamicin, but *Ps. aeruginosa* is generally sensitive to gentamicin. Commercial test strips are available to confirm the identity of *B. pseudomallei*²².

If cultures are indeed negative, then serological testing may be the only means of confirmation. In Case 4 of meningoencephalitis, this was certainly what happened. A report of encephalomyelitis from Australia was also confirmed only on serological testing¹⁹. But then again, serological tests have their sensitivity and specificity rates, so need to be interpreted accordingly.

Thirdly, the cases illustrate the spectrum of severity seen with melioidosis. Case 3 is an example of recrudescence melioidosis, *B. pseudomallei* lying dormant for months until a trigger event reactivated the infection. Even then, Case 3 was not severely ill as in the Cases 1, 2 and 4, which were primary acute septicaemic infections where the patients quickly deteriorated.

Fourthly, a characteristic of melioidosis seen here in three of the four cases was some degree of patient immunocompromise. It is appreciated that melioidosis has an affinity for those with some preexisting medical condition. A figure of 20 percent has been quoted⁹. Cases 1 and 3 had

diabetes mellitus, while Case 2 was pregnant and had SLE on corticosteroids, which meant each had impaired immunity. None were positive for HIV.

Conclusion

For ENT/Head and Neck surgeons, the moral of the story is to consider the possibility of melioidosis in each and every infection, however, unlikely. Two clues are, firstly, some form of immune impairment, and secondly, an infected patient who becomes relentlessly ill. Perhaps a third clue is if the patient came from a rural setting, where the possibility of contact with contaminated soil and water is higher.

Perhaps not initially considering the possibility of melioidosis does not change the initial management of a case of infection. Empirical antibiotics started in most centres nowadays are broadspectrum intravenous antibiotics, such as third generation cephalosporins, which mostly cover melioidosis.

But the value of confirmation of melioidosis by whatever means, by culture or serology, lies in subsequent management. In acute septicaemic melioidosis, the patient almost invariably deteriorates, therefore making it likely of changing management, either with more aggressive antibiotics, with a surgical procedure or even with ICU support. The clinician will at least have ample opportunity to be prepared for any eventuality. Moreover, in confirmed post-acute melioidosis, oral antibiotic therapy for prevention of relapse can be started.

References

1. Dance, DAB. Chapter 51 Melioidosis, Manson's Tropical Diseases, Edited by Gordon C. Cooke, 20th Edition, Saunders, 1996.
2. Ng TS. Melioidosis: a report of two cases. *Med J Malaysia*. 1979; 33(3): 269-71.
3. Tan NG, Sethi DS. An unusual case of sorethroat: nasopharyngeal melioidosis. *Singapore Med. J*. 1997; 38(5): 223-5.
4. Dance DA *et al*. Acute suppurative parotitis caused by *Pseudomonas pseudomallei* in children. *J Infect Dis*. 1989; 159(4): 654-60.
5. Elango S, Sivakumaran S. Parapharyngeal space melioidosis in a diabetic. *J Laryngol Otol*. 1991; 105(7): 582-3.
6. Wong PK, Ng PH. Melioidosis presenting with orbital cellulitis. *Singapore Med J*. 1996; 37(2): 220-1.
7. Karcher AM, Zaman N, Brewis C, Fahmy T. Neck lumps: expect the unexpected. *Lancet*. 2000 25; 355(9209): 1070.
8. Lumbiganon P, Viengnondha S. Clinical manifestations of melioidosis in children. *Pediatr Infect Dis J*. 1995; 14(2); 136-40.
9. Wilairatana P, Looareesuwan S. Melioidotic otitis media. *Southeast Asian J Trop Med Public Health*. 1994; 25(4): 776-7.
10. Singh N. Melioidosis presenting as encephalitis. *Aust N Z J Med*. 1976; 6(2): 156-7.
11. Beck RW, Janssen RS, Smiley ML, Schatz NJ, Savino PJ, Rubin DH. Melioidosis and bilateral third-nerve palsies. *Neurology*. 1984; 34(1): 105-7.
12. Lee MK, Chua CT. Brain abscess due to *Pseudomonas pseudomallei*. *Aust NZJ Med*. 1986; 16(1); 75-7.
13. Pit S, Chea FK, Jamal F. Melioidosis with brain abscess. *Postgrad Med J*. 1988; 64(748): 140-2.
14. Pelekanos JT, Appleton DB. Melioidosis with multiple cerebral abscesses. *Pediatr Neurol*. 1989; 5(1): 48-52.
15. Visudhiphan P, Chiemchanya S, Dheandhanoo D. Central nervous system melioidosis in children. *Pediatr Infect Dis J*. 1990; 9(9): 658-61.
16. Woods ML 2nd *et al*. Neurological melioidosis: seven cases from the Northern Territory of Australia. *Clin Infect Dis*. 1992; 15(1); 163-9.
17. Kasantikul V, Lerdlum S, Suwanwela N. Cerebral abscesses due to *Pseudomonas pseudomallei*. *J Med Assoc Thai*. 1992; 75(9): 536-41.
18. Kong HL, Ong BK, Lee TK, Cheah JS. Melioidosis of the brain presenting as a stroke syndrome. *Aust NZJ Med*. 1993; 23(4): 413-4.
19. Wells R, McCormack J, Lavercombe P, Tannenberg A. Melioidosis causing encephalomyelitis. *Aust NZJ Med*. 1996; 26(4): 567.
20. Maguire GP, Flavell HD, Burrow JN, Currie BJ. Relapsing neurological melioidosis from the top end of the Northern Territory. *Aust NZJ Med*. 1998; 28(2): 219-20.
21. Lath R, Rajshekhar V, George V. Brain abscess as the presenting feature of melioidosis. *Br J Neurosurg*. 1998; 12(2): 170-2.
22. Dance DAB, Wuthiekanum V, Naigowit P, White NJ. Identification of *Pseudomonas pseudomallei* in clinical practice: use of simple screening tests and API 20NE. *J Clin Pathol* 1989; 42: 645-8.