

# Low-Dose Inhaled Nitric Oxide in Term and Near-Term Infants with Hypoxic Respiratory Failure: A Malaysian Experience

A Y Goh, MRCP\*, L C Lum, MRCP\*, M Roziah, MRad\*\*, \*Pediatric Intensive Care Unit, \*\*Department of Radiology, University Malaya Medical Center, 50603 Kuala Lumpur

## Summary

Inhaled nitric oxide (iNO) improves oxygenation in term and near-term infants with persistent pulmonary hypertension of the newborn (PPHN) and decreases the need for treatment with extracorporeal membrane oxygenation (ECMO). This mode of treatment is currently being introduced in Malaysia. We report our preliminary experience using low dose inhaled nitric oxide (20 parts per million) in three newborn infants (meconium aspiration syndrome, primary PPHN and congenital diaphragmatic hernia) with severe PPHN who fulfilled criteria for ECMO with a mean oxygenation index (OI) of 40. Two of the infants showed rapid and sustained improvement in oxygenation with a reduction in oxygenation index (OI) over 24 hours. The infant with diaphragmatic hernia showed an initial improvement in OI, which was unsustainable and subsequently died. All three infants did not show significant elevation of methemoglobin or nitrogen dioxide (NO<sub>2</sub>). Inhaled nitric oxide is an effective and safe treatment for severe PPHN that can be used in a developing country like Malaysia.

**Key Words:** Hypoxic respiratory failure, Persistent pulmonary hypertension of the newborn, Inhaled nitric oxide, Oxygenation index

## Introduction

Hypoxic respiratory failure or persistent pulmonary hypertension of the newborn (PPHN) in term and near-term ( $\geq 34$  weeks gestation) neonates is characterised by marked pulmonary hypertension, altered vasoreactivity leading to extra-pulmonary right-to-left shunting of blood across the patent ductus arteriosus and foramen ovale<sup>1</sup>. This syndrome is often associated with severe parenchymal lung diseases (lung hypoplasia, meconium aspiration syndrome, respiratory distress

syndrome, congenital diaphragmatic hernia, pneumonia and sepsis) which causes intra-pulmonary shunting which complicates the clinical course and treatment<sup>1,2</sup>. In many cases the disease progressively worsens, becoming refractory to treatment and is associated with a high mortality<sup>3</sup>.

Treatment of hypoxic respiratory failure has been limited by the unavailability of a selective vasodilator of the pulmonary vascular bed. The use of vasodilators such as magnesium sulphate and adenosine have met with variable success but are associated with significant systemic side effects such as hypotension and neuromuscular

paralysis<sup>4,5</sup>. In Malaysia, treatment of PPHN mainly involves support with oxygen, mechanical ventilation, induction of alkalosis by hyperventilation or base infusion, neuromuscular blockade, sedation and non-specific pulmonary vasodilators. This mode of therapy is associated with significant morbidity and mortality. Nitric oxide or endothelium derived relaxing factor has been found to be an important regulator of vascular muscle tone<sup>6</sup>. Subsequent multi-center studies have shown that inhaled nitric oxide is a selective pulmonary vasodilator that improves oxygenation in infants with PPHN<sup>7,8,9</sup>. This treatment is in the early phase of introduction in Malaysia. We would like to report our initial experience with the use of low dose inhaled nitric oxide (iNO) in the treatment of 3 newborn infants with severe PPHN and refractory hypoxemia who had fulfilled criteria for extracorporeal membrane oxygenation treatment.

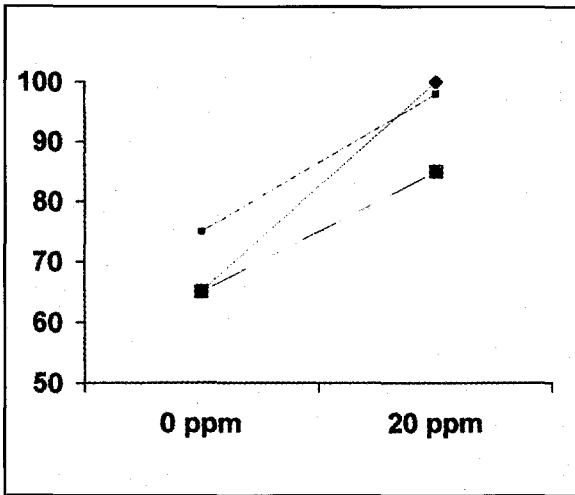
## Materials and Methods

We studied 3 severely hypoxemic neonates with a clinical diagnosis of PPHN who required assisted ventilation and had an oxygenation index of 25 or higher measured with a catheter in the descending aorta (post-ductal). The oxygenation index (OI) was used as a marker of the degree of hypoxemia and was calculated as the mean airway pressure times the fraction of inspired oxygen times 100, divided by the partial pressure of oxygen. The larger the value the more severe was the hypoxemia. Sustained values >25 have been recommended as one of the criteria for initiating extra-corporeal membrane oxygenation (ECMO) rescue<sup>10</sup>. All the neonates were ventilated with conventional pressure limited ventilators (Servo 300C, Siemens) and one of the infants had a trial of high frequency oscillatory ventilation (HFOV, SensorMedics). The neonates had clinical and echocardiographic evidence of pulmonary hypertension without structural heart disease. Clinical evidence of PPHN was defined as a difference of  $\geq 5$  percent between pre and post-ductal oxygen saturation and recurrent decrease

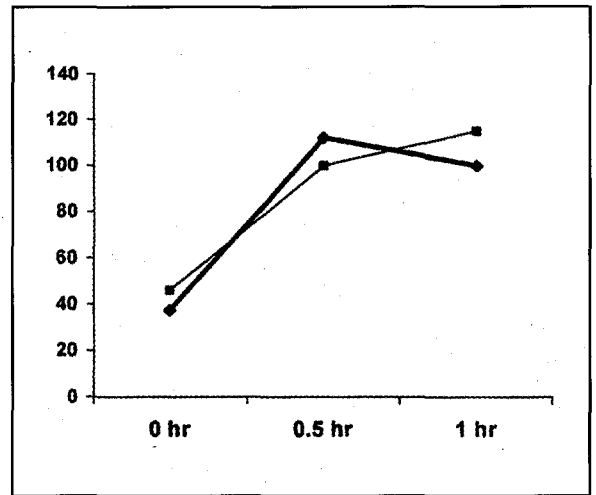
in arterial oxygen saturation to <85% (>2 episodes in 12 hours) despite optimal treatment of lung disease. Echocardiographic evidence were as follows 1) a right-to-left or bi-directional shunt across the ductus and/or foramen ovale and 2) a tricuspid regurgitation (TR) jet with an estimated systolic pulmonary artery pressure  $\geq 75\%$  of systolic aortic pressure<sup>9</sup>. The iNO delivery system (Inovent, Datex-Ohmeda) was designed to deliver NO mixed with nitrogen into the inspiratory limb of the ventilator circuit. Inhaled NO and NO<sub>2</sub> were measured continuously at the endotracheal tube by a specific calibration gas kit (iNOcal, Datex-Ohmeda).

## Case 1

A term newborn infant (40 weeks) was delivered with thick meconium stained amniotic fluid and developed severe respiratory distress soon after birth requiring positive pressure ventilation with both clinical and echocardiographic evidence of PPHN. Post-ductal SpO<sub>2</sub> remained well below 70% and there were frequent pre-ductal arterial desaturations to <85% despite being on a fraction of inspired oxygen (FiO<sub>2</sub>) of 1.0. Chest XRay was consistent with a diagnosis of meconium aspiration. Right to left shunting was demonstrated on echocardiography with a measured tricuspid regurgitation (TR) jet equivalent to systolic arterial pressure. The patient fulfilled criteria for ECMO with refractory hypoxemia with an OI of 43 despite full medical treatment including surfactant lavage. Inhaled NO was started at 20 ppm at 18 hours of life and after 30 minutes the OI fell by 60% with an increase in post-ductal SpO<sub>2</sub> and oxygenation (Figure 1 and 2). Measured tricuspid regurgitation jet after 10 hours of inhaled NO showed a decrease of TR jet to two thirds of systolic arterial value. A sustained and progressive improvement was noted and inhaled NO was stopped after 38 hours. Systemic arterial pressure was stable throughout NO inhalation and methemoglobin levels were constantly <1.0%. The patient was extubated by day 4 of life.



**Fig. 1: Improvements in post-ductal SpO<sub>2</sub> after inhalation of 20 ppm NO in three patients with PPHN.**



**Fig. 2: Improvements in oxygenation after initiation of inhaled NO therapy at 20 ppm in 2 responders (PaO<sub>2</sub> measured in mmHg).**

**Case 2**

A term newborn infant (38 weeks) was delivered uneventfully with good Apgar scores to a mother with prolonged rupture of membranes (>24 hours) and developed worsening respiratory distress requiring positive pressure ventilation. A clinical diagnosis of congenital pneumonia was suspected and despite full medical treatment including antibiotics she developed progressive refractory hypoxemia with an OI of 40. Chest Xray was relatively normal and the blood cultures were sterile. A diagnosis of primary PPHN was then made. There was both clinical and echocardiographic evidence of PPHN. Post-ductal SpO<sub>2</sub> was constantly below 80% with episodic pre-ductal desaturations to <85%. Echocardiography showed bi-directional shunting with a measured TR jet of >75% of systolic arterial pressure. Inhaled NO was started at 20 ppm at 32 hours of life with an improvement in post-ductal SpO<sub>2</sub>, oxygenation and fall in OI by 58% (Figure 1 and 2). A similarly sustained improvement in oxygenation was noted and NO inhalation was discontinued after 48 hours. Systemic arterial

pressure remained stable and methemoglobin levels were constantly <1.5% during NO treatment. Patient was extubated by day 5 of life.

**Case 3**

A term newborn infant with antenatally diagnosed left congenital diaphragmatic hernia, (CDH) developed severe respiratory distress soon after birth with clinical and echocardiographic evidence of PPHN with an OI of 38. A trial of high frequency oscillation was attempted but the patient progressively deteriorated. Echocardiography showed a measured TR jet equivalent to systolic arterial pressure. A trial of inhaled NO was attempted at 20 ppm at 30 hours of life. This temporarily improved the post-ductal SpO<sub>2</sub> to 85% from 65% but this improvement was unsustainable (Figure 1). Inhaled NO was increased to 80 ppm but this did not lead to further improvement in post-ductal oxygen tension. After a trial of 4 hours inhaled NO was discontinued. The patient remained severely hypoxemic and died on day 2 of life.

## Discussion

Persistent pulmonary hypertension of the newborn (PPHN) is an important cause of cardiorespiratory failure in the near-term infant (>34 weeks), occurring either as a primary condition related to neonatal vascular maladaptation or more commonly secondary to other diseases such as meconium aspiration syndrome, hyaline membrane disease, congenital pneumonia, sepsis or congenital diaphragmatic hernia<sup>1,2,3</sup>. Conventional therapy for PPHN including those used in Malaysia<sup>11</sup> includes paralysis, sedation, and induction of alkalosis by hyperventilation or base infusion and use of non-specific pulmonary vasodilators such as magnesium sulphate and adenosine<sup>4,5</sup>. None of these have been tested in a randomised fashion and a survey by Walsh-Sukys *et al*<sup>2</sup> has shown a great heterogeneity and diversity in application of these treatments amongst board certified neonatologists in the United States.

Treatment of PPHN has been hampered by the lack of a specific pulmonary vasodilator without systemic side effects until the discovery of nitric oxide<sup>6</sup>. Numerous multi-center trials have since demonstrated the efficacy of low dose inhaled nitric oxide in improving oxygenation in severely hypoxemic infants with PPHN and reducing the need for extracorporeal membrane oxygenation<sup>7,8,9,13</sup>. This improvement in oxygenation was associated with minimal systemic side effects. There was however no improvement in the survival rate of infants treated with inhaled NO compared to the controls. Part of this lack of improvement in survival with iNO might have been the availability of an effective rescue treatment in the form of extracorporeal membrane oxygenation (ECMO). Data from the Extracorporeal Life Support Organization Registry shows an overall survival rate of 81% in all treated

newborns<sup>14</sup>. The criteria for referral to ECMO had been previously associated with mortality in excess of 80%<sup>10</sup>. ECMO is however both significantly labour and cost intensive and may be associated with significant neuro-developmental deficits<sup>15,16</sup>. In a country like Malaysia where this rescue therapy is unavailable and the cost too exorbitant to introduce, the use of iNO might be expected to lead to increased survival in neonates with hypoxic respiratory failure when compared to conventional therapy.

However it is important to remember that as an inhalational agent the efficacy of NO treatment is dependent on adequate delivery to the target resistance vessels within the lung. Strategies which improve lung underinflation (augment lung recruitment and sustainment of adequate lung volume) in order to reduce intra-pulmonary shunting, including the use of high frequency ventilation (HFOV) combined with NO have been shown to be superior to HFOV or NO alone<sup>17</sup>. Pharmacologic pulmonary vasodilatation alone would not be expected to sustain clinical improvement in many cases.

We have shown that inhaled NO can be used safely and effectively in a tertiary paediatric ICU in Malaysia for the treatment of PPHN when used in combination with mechanical ventilation strategies that augment lung recruitment rather than hyperventilate. Low dose inhaled nitric oxide at 20 ppm is a safe and effective treatment for hypoxic respiratory failure in term and near-term infants without diaphragmatic hernia. It should be considered as part of an overall clinical strategy that manages parenchymal lung disease, cardiac performance and systemic haemodynamics in Malaysia. Larger studies are needed locally to access the cost-benefit ratio of this mode of treatment in the management of neonatal hypoxic respiratory failure.

## References

1. Gersony WM. Neonatal pulmonary hypertension: pathophysiology, classification and aetiology. *Clin Perinatology* 1984; 11: 517-24.
2. Graves ED III, Redmond CR, Arensman RM. Persistent pulmonary hypertension of the neonate. *Chest* 1988; 93: 638-41.
3. Goetzman BW, Riemenschneider TR. Persistence of the fetal circulation. *Paediatr Res* 1980; 2: 37-40.
4. Abu-Osba YK, Galal O, Manasra K, Rejjal A. Treatment of severe persistent pulmonary hypertension of the newborn with magnesium sulphate. *Arch Dis Child* 1992; 67: 31-5.
5. Konduri GG, Garcia DC, Kazzi NJ, Shankaran S. Adenosine infusion improves oxygenation in term infants with respiratory failure. *Paediatrics* 1996; 97: 295-300.
6. Palmer RMJ, Ferrige A, Moncada S. Nitric oxide release accounts for the biological activity of endothelium-derived relaxing factor. *Nature* 1987; 327: 523-6.
7. The Neonatal Inhaled Nitric Oxide Study Group. Inhaled nitric oxide in full-term and nearly full-term infants with hypoxic respiratory failure. *N Engl J Med* 1997; 336: 597-604.
8. Roberts JD Jr, Fineman J, Morin FC III, *et al.* Inhaled nitric oxide and persistent pulmonary hypertension of the newborn. *N Engl J Med* 1997; 336: 605-10.
9. Davidson D, Barefield ES, Kattwinkel J, and I-NO/PPHN study group. Inhaled nitric oxide for the early treatment of persistent pulmonary hypertension of the term newborn: a randomized, double-masked, placebo controlled, dose-response, multicenter study. *Paediatrics* 1998; 101: 325-34.
10. Bartlett RH, Roloff DW, Cornell RG, Andrews AF, *et al.* Extracorporeal circulation in neonatal respiratory failure: a prospective randomized study. *Paediatrics* 1985; 76: 479-87.
11. Chong BO, Goh AYT, Chan PWK, Lum LCS, Lim CT. Outcome of persistent pulmonary hypertension of the newborn (PPHN) managed without ECMO. Proceedings 6th Annual Congress of the Perinatal Society of Malaysia 1999.
12. Walsh-Sukys MC, Tyson JE, Wright LL, *et al.* Persistent pulmonary hypertension of the newborn in the era before nitric oxide: practice variation and outcomes. *Paediatrics* 2000; 105: 14-20.
13. Clark RH, Kueser TJ, Walker MW, *et al.* Low-dose nitric oxide therapy for persistent pulmonary hypertension of the newborn. Clinical Inhaled Nitric Oxide Research Group. *N Engl J Med* 2000; 342: 469-74.
14. Extracorporeal Life Support Organization. ECMO registry report. Ann Arbor, Michigan: ELSO, July 1993.
15. UK Collaborative ECMO Trial Group. UK collaborative randomised trial of neonatal extracorporeal membrane oxygenation. *Lancet* 1996; 348: 75-82.
16. The Collaborative UK extracorporeal membrane oxygenation (ECMO) trial: follow up to 1 year of age. *Paediatrics* 1998; 101: E1.
17. Kinsella JP, Truog WE, Walsh WF, *et al.* Randomized, multi-center trial of inhaled nitric oxide and high frequency oscillatory ventilation in severe persistent pulmonary hypertension of the newborn. *J Paediatr* 1997; 131: 55-62.