

# Upper Genital Schistosomiasis Mimicking an Ovarian Tumour

K C Shekhar\*, E B S Soh\*\*, P Jayalakshmi\*\*\*, \*Department of Parasitology, \*\*Department of Obstetrics & Gynecology, \*\*\*Department of Pathology, Faculty of Medicine, University of Malaya, 50603 Kuala Lumpur

## Summary

Schistosomiasis is a widely prevalent disease in the world and usually involves the gastro-intestinal and urinary tract. The involvement of the female genital tract has been well-established in *S. haematobium* infections and is rare with *S. japonicum* infections. This case involves a Filipino female who was admitted to the University Hospital Kuala Lumpur for right iliac fossa pain and was diagnosed initially as acute appendicitis. Ultrasound showed a multi-septated pelvic cyst leading to a provisional diagnosis of ovarian torsion. Intraoperatively a right parovarian cyst was detected and removed. Histology revealed a congested cyst wall with areas of haemorrhage with several viable and calcified eggs of *S. japonicum* measuring 85µm x 62µm. Within the cystic cavity blood admixed with eggs were seen. Confirmation was carried out by using the indirect haemagglutination (IHA) test. This is a first report of upper genital schistosomiasis mimicking an ovarian tumour.

**Key Words:** Upper genital schistosomiasis, *S. japonicum*

## Introduction

Schistosomiasis, caused by *Schistosoma mansoni*, *S. japonicum* and *S. haematobium*, a chronic debilitating disease is the fourth most prevalent disease in the world and has been estimated to globally infect 1 in 30 people<sup>1</sup>. The disease results directly from eggs and from the granulomatous host response to them. The adult worms produce little damage other than deposition of eggs. Schistosomiasis may produce a variety of lesions in any part of the female genital tract<sup>2</sup>. To what extent *S. mansoni*, and *S. japonicum* cause genital schistosomiasis is still debated. Lower genital tract (LGT) lesions by *S. japonicum*, seems to be extremely rare while affliction of the ovaries is common. *S. mansoni* eggs have been regularly encountered in the cervix, vagina and uterus but seldom in the vulva, fallopian tubes or ovaries. Unlike *S. mansoni*, a significant portion of *S. haematobium* ova, calcify and accumulate in the affected organs.

Of the female genital organs, the fallopian tubes, ovaries, uterine cervix, parametrium and vagina are the most commonly affected. It has been reported that female genital schistosomiasis is a neglected disease entity that has been associated with considerable suffering among women of child-bearing age in all the endemic areas for urinary schistosomiasis. It has been found to cause infertility, pregnancy complications, menstrual disorders, problems related to sexual intercourse, diagnostic difficulties with STD's and cancer, unspecified complaints related to blood loss, chronic abdominal pain, social segregation and psychological problems. Lower genital tract (LGT) lesions are easily detectable by gynaecological examination and colposcopy. Typical eggs can be identified by examining wet-crushed tissues of biopsies. The eggs in the lower genital tract can give rise to a wide array of symptoms that cause severe psychological effects in the affected individuals. On the other hand,

## CASE REPORT

lesion of the upper genital tract (UGT) are less discernible by routine clinical examination and thus explains why no data is available on its prevalence in the various age groups to determine the exact morbidity of this condition. This also explains why this disease manifestation has caught little attention from gynaecologists and parasitologists.

The gynaecological involvement in *S. japonicum* infection is a rare entity. Narabayashi<sup>3</sup> in 1914 reported the first case of infection of a foetus by trans-placental passage of the parasite. Later Ching-Ch'ien<sup>4</sup> reported from China, a case of uterine involvement in a 42 year old patient who presented with menometrorrhagia and an enlarged uterus. Thus far only a few cases have been reported. This paper describes the various courses undertaken by surgeons and gynaecologists in this hospital to arrive at a diagnosis of upper-genital schistosomiasis mimicking an ovarian tumour. This would constitute a rare case reported for the first time in this country and within the Southeast Asian region.

### Case Report

A 24-year-old, single, nulliparous Filipino woman presented with an acute onset of continuous right iliac fossa pain followed by vomiting. She was afebrile and did not have any prior bowel or urinary symptoms. Whilst in the Philippines, she lived in a suburban apartment in Manila on the main island of Luzon. She used well water for cooking and washing purposes. She had worked in an electronics factory previously in Manila and denied a history of regular contact with any pools of water. For the past four years, she had lived in Malaysia. She works as a maid and lives in an urban area with good piped water and hygienic sanitation facilities. There is no pool of water in her present area of residence.

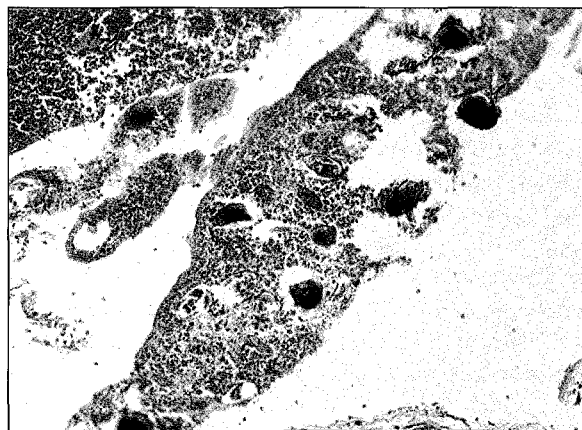
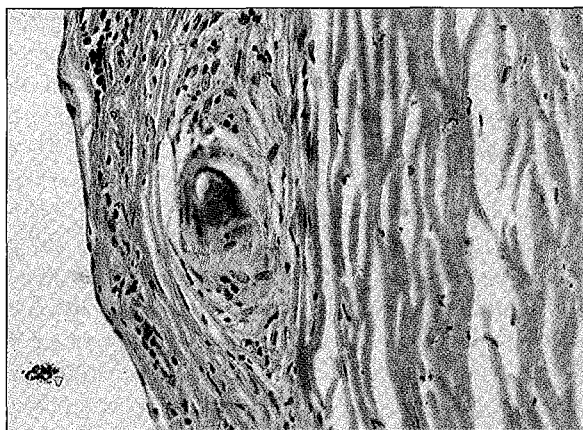
On examination, she was in obvious pain but her vital signs were stable. Systemic examination was unremarkable. A vague mass was felt in the right iliac fossa and there was guarding and rebound tenderness. A pelvic examination revealed a vague mass superior to the uterus. The rest of the pelvis was normal but examination was limited by tenderness. Lab investigations showed leucocytosis and a few white blood cells in the urine.

The surgical team who first saw her made a tentative diagnosis of acute appendicitis based on her symptoms. She was observed overnight and subsequently referred to the gynaecology team for the vague pelvic mass. A urine pregnancy test done to exclude an ectopic pregnancy was negative. An ultrasound examination showed a multi-septated pelvic cyst, probably of ovarian origin measuring 6.0 x 3.5 x 4.7cm with a regular thick capsule. The uterus and the contra-lateral ovary were normal. A provisional diagnosis of an ovarian torsion was made and a laparotomy was performed.

Intra-operatively, a congested and haemorrhagic right par-ovarian cyst measuring 9 x 7 x 6cm was found enveloped by the greater omentum. The right fallopian tube was firmly adherent to it. The cyst was removed and a partial right salpingectomy performed. A partial omentectomy was done. A small nodule on the left ovary measuring 0.5cm and another 0.5-cm nodule from the rectal serosa were similarly removed. Part of the omentum was also taken for histopathological examination. The rest of the pelvic and peritoneal viscera was explored and was found to be normal.

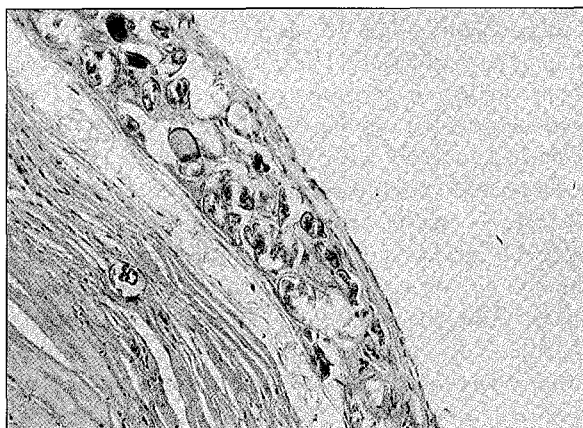### Histopathology

The cyst wall was congested with areas of haemorrhage and measured 9 x 7 x 6 centimetre. Microscopic examination showed inflamed granulation tissue and fibrous tissue in the cyst wall. The histological diagnosis of schistosomiasis was based on the finding of several viable as well as calcified eggs of *Schistosoma japonicum* in the cystic-cavity admixed with blood. They measured 85µm x 62µm. The ova were in various stages of degeneration and often only distorted shell fragments were present. Ova containing mature miracidia were recognised by their eosinophilic glands and small germinal cells. Large numbers of shell fragments trapped in fibrous tissue was present with little or no inflammation. The nodule on the surface of the ovary revealed eggs of *Schistosoma japonicum*, some of which were surrounded by epithelioid and scarring granuloma (pseudotubercles). [Figure 1-3]. The rectal tissue showed fibrosis with granulation tissue without evidence of schistosome eggs.



**Fig. 1:** Section of the cyst-wall showing numerous eggs of *Schistosoma japonicum* - viable and calcified eggs. H&E x 100

**Fig. 3:** Many schistosome ova suspended in blood clot. H & E x 200



**Fig. 2:** Scarring granuloma with the egg in the nidus in fibrotic cyst wall. H & E x 200

### Discussion

Involvement of the female genital tract is a relatively rare condition in schistosomiasis though it has been known to occur in the female reproductive organs. Although numerous papers have been published on the occurrence of female genital schistosomiasis with *S. haematobium* infection, scant reports exist for *S. mansoni* and *S. japonicum* infections. *S. haematobium* is a significant cause of gynaecological morbidity of both upper and lower genital tract<sup>5</sup>. It has been reported that a significant portion of *S. haematobium* ova calcify and accumulate in the affected organs making pathological sequelae more likely<sup>6</sup>. The involvement of the lower genital tract is extremely rare in *S. japonicum* infections, though affliction of the ovaries has been quoted to be quite common. This does not appear to be true as no reports have been published of upper genital involvement in schistosomiasis japonica except this present case.

### Parasitology

Her stool, urine and vaginal smears were negative for *Schistosoma* eggs. However, serology using the Indirect Hemagglutination (IHA) [Cellognost<sup>®</sup> schistosomiasis Behring] showed significant positivity with an IgG titre of 1:256. Based on these findings, she was prescribed praziquantel at 40-mg/kg-body weight. Her post-operative recovery was unremarkable.

The first case of genital schistosomiasis was of the vagina reported in Egypt in 1899<sup>7</sup>. Gibson<sup>8</sup> described schistosomiasis haematobium infestation of the female genital tract in Africa. The involvement of the female genital tract by *S. mansoni* in South America was reported from Puerto Rico and Brazil in 1956<sup>9</sup>.

## CASE REPORT

How the parasites gain access to the upper genital tract is still a subject of debate. It has been postulated that the adult worms of *S. haematobium* are able to gain easy access to the internal and external genitalia via the intricate vascular links between the plexus rectalis and vesicalis on the one side and veins of the female genital organs on the other. Gelfand *et al.*<sup>2</sup> based on their autopsy study concluded that any woman with urinary schistosomiasis would have ova in one or several organs of the reproductive tract based on the location of the adult parasites. However, in the case of *S. mansoni* and *S. japonicum* whose main predilection sites are the mesenteric veins, the mechanism of invasion and sequestration of eggs is still unknown. It is believed that the worms are able to pass via the anastomoses of the anorectal plexus through the recto-vaginal septa to reach the vaginal wall, cervix, bladder, lower-end of uterus, fallopian tubes and ovaries. This probably explains the involvement of ovaries in this case. It is a rare phenomenon and would be considered a 'pathological curiosity'. The patient, a Filipino, claimed that she had not entered pools of water, rivers or any area of water collections to get infected. This defeats the natural history of the disease as the only mode of entry of this parasite is through the skin. Being a chronic disease, she would have acquired this infection early in childhood to manifest the disease now. It takes approximately between 5-10 years to have a full-blown disease from the time of acquiring the infection. Physicians and gynaecologists treating female immigrants need to obtain a detailed residence and travel history to trace the source of infection when upper genital tract disease is strongly suspected. The reason is because the disease is present in six islands in the Philippines, where at least a million people are living in endemic areas and 650,000 estimated to be infected.

There seems to be a relationship between topographical localisation of schistosome lesions and age. In very young girls or those at puberty, the vulva is often affected but at a later age the vagina, cervix and upper genital organs are affected<sup>10</sup>. This has been attributed to the anatomy, principally due to vascular adaptations starting during puberty, early womanhood and culminating during pregnancy. This case confirms the above statement as this particular patient is in her early womanhood.

From the clinical point of view, localisation of adult worms and deposition of eggs in ectopic sites are of considerable medical importance. Eggs deposited in these anatomical sites induce formation of granuloma and eventually lead to fibrosis and scar formation. Giese *et al.*<sup>11</sup> described two distinct patterns of tissue reactions in the histological specimens of their patients with female genital schistosomiasis. The first type was a strong inflammatory reaction characterised by a diffuse infiltration of plasma cells, lymphocytes, eosinophils and macrophages around sites of egg deposition particularly viable eggs. The second type was a fibrous connective tissue reaction with a minimal cellular infiltrate best described as scar tissue. They found surprisingly that this pattern was observed in the majority of cases around non-viable eggs or calcified shell fragments. In this particular case, the second type of histological reaction was mostly seen and interestingly, we found typical epithelioid and scarring egg granulomas.

Wright *et al.*<sup>7</sup> who studied retrospectively 176 cases of schistosomiasis of the female genital tract in Malawi found the ovary involved in 17 cases. Most of these were from salpingo-oophorectomy specimens removed for various reasons including tubo-ovarian abscess, pelvic adhesions, ovarian cysts, ectopic pregnancy and tubal ligation. Most of the patients presented during the third decade. In six of the cases, schistosomiasis was a probable incidental finding and the diagnosis was based purely on histological examinations which showed sparsely distributed shell fragments in tubal smooth muscle. In this particular case, the operative procedures were almost similar with the discovery of an ovarian cyst as an incidental finding confirmed on histology as upper genital schistosomiasis.

The etiologic role of schistosomiasis in oncogenesis has been observed in several circumstances. *S. mansoni* has been associated with cancer of the colorectum, spleen, bile duct and hepatocellular malignancy. Tumorigenic factors secreted by the worms have been implicated in the development of cervical cancer. *S. haematobium* has been associated with squamous cell carcinoma of the urinary bladder, ovarian carcinoma, ovarian teratoma, cervical cancer the evidence pointing to the role of chronic inflammatory stimulus delivered by sequestered eggs. Epithelial hyperplasia, basal cell hyperactivity,

leukoplakia abnormalities frequently observed in women with female genital schistosomiasis have been regarded as precancerous reactions evoked by *S. haematobium* eggs present in cervical tissue<sup>12</sup>. An etiologic link between *S. japonicum* and cancer formation are being reported with increasing frequency. Pathological records and analyses have shown a direct correlation between this infection and cancer. Patho-histological description has become numerous together with clinical case reports. However, no reports are available on the involvement of *S. japonicum* infection in the female genital tract and cancer from the endemic areas. The symptoms and signs seen in this patient appeared to mimic a par-ovarian tumour and an etiologic link could be established definitely as eggs were seen within the cyst. Gynaecologists, pathologists and parasitologists working in endemic areas for schistosomiasis japonica need to determine the distribution and extent of female genital schistosomiasis and cancer from either autopsies or biopsies to determine the extent of the involvement of this infection in their population. In endemic areas, it is envisaged that a large number of women of childbearing age could be having

disease involving the upper genital tract, which is undiagnosed, as it is asymptomatic unless complicated.

It is interesting to note that the initial diagnosis of this case based on the right iliac fossa pain was acute appendicitis. Subsequently, it was diagnosed as ovarian tumour and later on laparotomy was found to be a twisted right parovarian cyst. The diagnosis of schistosomiasis would never have been arrived had it not been for histopathology and the serology. The events of this case from initial to final diagnosis shows that upper genital tract schistosomiasis can mimic a number of disease conditions. An increased awareness of female genital schistosomiasis is necessary for our Malaysian gynaecologists who are encountering immigrants from endemic areas in their hospital settings.

### Acknowledgements

The authors wish to thank Professor Dr R. Pathmanathan, Consultant Pathologist, Subang Jaya Medical Centre for taking the histopathograph of the slides.

### References

1. Elliot DE. Schistosomiasis. Pathophysiology, diagnosis and treatment. *Gastroenterology Clinics of North America* 1996; 25(3): 599-625.
2. Gelfand M, Ross MD, Blair DM, Weber MC. Distribution and extent of schistosomiasis in female pelvic organs with special reference to the genital tract, as determined at autopsy. *American Journal Tropical Medicine and Hygiene* 1971; 20(6): 846-49.
3. Narabayashi: 1914; cited by Carpenter CB, Mozley PD, Lewis NG. Schistosomiasis japonica involvement of the female genital tract. *Journal of the American Medical Association* 1964; 188(7): 647-50.
4. Ching-ch'ien K. Pathology of schistosomiasis. 1st ed. Shanghai: Commercial press. 1951.
5. Madden FC. A case of bilharzia of the vagina. *Lancet* 1899; I: 1716.
6. Christie JB, Crouse D, Kelada AS, Anis-Ishak E, Smith JH, Kamel IA. Patterns of *S. haematobium* egg distribution in the human lower urinary tract. II. Cancerous lower urinary tracts. *American Journal of Tropical Medicine and Hygiene* 1986; 35: 759-64.
7. Wright ED, Chipangwi J, Hutt MSR. Schistosomiasis of the female genital tract. A histopathological study of 176 cases from Malawi. *Transactions of the Royal Society of Tropical Medicine and Hygiene* 1982; 76(6): 822-29.
8. Gibson RWB. Bilharziasis of the female genital tract. *Medical Journal of South Africa* 1925; 21: 44-45.
9. Areen VM. Manson's schistosomiasis of the female genital tract. *American Journal of Obstetrics and Gynecology* 1956; 72: 1038-53.
10. Artili RV, Hira SK, Dube MK. Schistosomal genital granulomas: a report of 10 cases. *British Journal of Venereal Diseases* 1983; 59: 269-72.
11. Giese GH, Sjaastad A, Poggensee G, Kjetland EF, Richter J, Chitsulo L, Kunwenda N, Racz P, Ronald B, Gundersen SG, Kruntz I, Feldmeier H. Female genital schistosomiasis (FGS): relationship between gynecological and histopathological findings. *Acta Tropica* 1996; 62: 257-67.
12. Youssef AF, Fayad MM, Shafeek MA. Bilharziasis of the cervix uteri. *Journal of Obstetrics and Gynaecology of British Commonwealth* 1970; 77: 847-51.