

Conventional Versus Endoscopic Inferior Turbinate Reduction: Technique and Results

B S Gendeh, MS(ORL-HNS), Department of Otorhinolaryngology, Faculty of Medicine, Hospital Universiti Kebangsaan Malaysia, Jalan Yaacob Latif, Bandar Tun Razak, 56000 Kuala Lumpur

Summary

Different modalities of turbinate reduction procedures are available for treatment of vasomotor rhinitis not responding to appropriate medical therapy. Amongst these, conventional inferior turbinectomy (non-endoscopic) is the most widely performed procedure. With the advent of nasal endoscopes, inferior turbinoplasty has been gaining popularity worldwide. The purpose of this study was to compare the post-operative complaints and hospital stay of conventional versus endoscopic inferior turbinate reduction techniques performed non-randomly on 15 and 21 patients of vasomotor rhinitis respectively from January 1998 to December 1999 at Hospital Universiti Kebangsaan Malaysia (HUKM). A total of 36 patients (22 males and 14 females) with a mean age of 30.6 years underwent turbinate reduction procedures during this period with a post-operative follow up ranging from 3 months to 6.7 months (mean 3.8 months). There was a significant difference between the conventional and the endoscopic technique with regards to nasal discomfort ($p=0.05$) and dry throat ($p=0.02$) which was less severe when performed endoscopically. The average hospital stay in hours by the endoscopic technique was almost half compared to the conventional technique.

Due to the improved visualisation and minimal post-operative complaints and reduced hospital stay, the technique of endoscopic inferior turbinoplasty is currently the procedure of choice at our center. In septoplasty when endoscopic instrument is not needed, the standard turbinate reduction procedure is still performed. The availability of pre and post-operative acoustic rhinomanometric evaluation will be helpful as an objective measurement of nasal symptoms in the near future.

Key Words: Inferior turbinate reduction: Conventional, Endoscopic

Introduction

Most rhinologist agree that surgical treatment of inferior turbinate in nasal and sinus disease provide symptomatic relief of nasal obstruction and congestion¹⁻⁴. Various techniques have been described including submucous resection², partial turbinectomy^{3,4} total turbinectomy^{5,6} and endoscopic inferior turbinoplasty^{1,7,8}. Cauterization⁹, cryotherapy^{10,11} and LASER^{12,13} ablation have been described in addition to resection. The advantage of

preserving functional mucosa is to reduce the risk of dry throat, nasal crusting and overly patent nasal cavity. Freer in 1911¹⁴ originally described the procedure of inferior turbinoplasty. The procedure was reintroduced and popularized by Mabry⁷. The operation consists of development of a medial mucosal flap of the inferior turbinate and then resection of bone and lateral mucosa. The advantage of this procedure is that it significantly reduces the bulk of the turbinate, but preserves the functional medial mucosa.

In some centers, endoscopic technique is recommended as an adjunctive procedure during endoscopic sinus surgery when inferior turbinate hypertrophy is present. Literature review of endoscopic inferior turbinoplasty shows no incidence of reported atrophic rhinitis on long term follow up⁸ compared to conventional techniques.

The purpose of this article is to discuss the post-operative complaints and hospital stay of conventional versus endoscopic inferior turbinate reduction techniques with main focus of emphasis on the latter new technique.

Materials and Methods

From January 1998 to December 1999, with the availability of new endoscopic instrumentation and technology at HUKM, the author has performed a non-randomized conventional and endoscopic inferior turbinate reduction technique on 16 and 23 patients of vasomotor rhinitis respectively who have failed appropriate medical therapy. Of the 39 cases, three patients (one with conventional and two with endoscopic technique) with inadequate data and rhinological follow-ups were excluded from the study. The follow up period ranged from 3 months to 6.7 months (mean 3.8 months). In the conventional group, there were 7 Indians, 5 Malays and 3 Chinese patients constituting of 9 males and 6 females with the average age of 32 years (range 17 to 49). In the endoscopic group, there were 9 Indians, 7 Malays and 3 Chinese patients constituting 13 males and 8 females with an average age of 29.5 years (range 22 to 45). Almost 10% of the patients in both the groups had additional endoscopic sinus surgery for nasal polyposis. The patients chart was reviewed for post-operative nasal discomfort, passageway, dry throat, duration of surgery and length of hospital stay. Statistical calculations were used employing the chi-square analysis method and p value less than 0.05 was taken as significant.

Surgical technique

The following surgical techniques were undertaken by the author in the conventional inferior turbinectomy and endoscopic inferior turbinoplasty. The patient was placed in semi-recumbent position and draped after informed consent and adequate anesthesia. The

oropharynx was packed with gauze to prevent accumulation of blood in the hypopharynx prior to draping. Cotton pledgets of five percent cocaine were placed in the nasal cavity for 10 to 15 minutes to decongest the nasal mucosa. Throughout the procedure, visualization is accomplished using the Welch Allen head light and the 4mm, 0 degree nasal endoscope in the conventional inferior turbinectomy and endoscopic inferior turbinoplasty respectively. Two to three ml of local anesthesia containing 1:100,000 epinephrine is each injected into the inferior turbinate. Injections are performed along the inferior edge of the turbinate until it blanches the medial mucosa.

In the **conventional inferior turbinectomy**, the turbinate mucosa was initially crushed at its attachment to lateral nasal wall using a intestinal clamp forceps. Using the turbinectomy scissors, the bulk of the anterior and mid-portion of the inferior turbinate was removed medial to the crush portion. Care was taken to avoid removing the posterior part of the inferior turbinate which can result in excessive bleeding. Suction cautery was used to cauterize the posterior blood supply to control bleeding. Haemostasis was maintained by inserting a Merocel nasal pack. In the majority of the cases, the nasal packing was removed on the second post-operative day.

In **endoscopic inferior turbinoplasty**, the inferior turbinate was primarily addressed in the majority of the cases and in 10% of cases after the sinus portion of the procedure was completed. With a 11 number blade and visualization accomplished using nasal endoscope, an incision was performed along the inferior edge of the turbinate up to the anterior attachment to the lateral nasal wall (Fig. 1). Using an endoscopy scissors, the medial mucosa was then elevated along the length of the turbinate (Fig. 2). The posterior edge of the flap was left attached to the turbinate bone. The turbinate bone with the attached lateral mucosa was resected, preserving the posterior turbinate attachment (Fig. 3). Suction cautery was used to cauterize the posterior blood supply to control bleeding.

After resection, the residual bone was lateralized and the mucosal flap folded over the bone edge and secured in place with a nasal pack (Fig. 4). In the majority of the cases, the nasal packing was removed the morning after surgery.

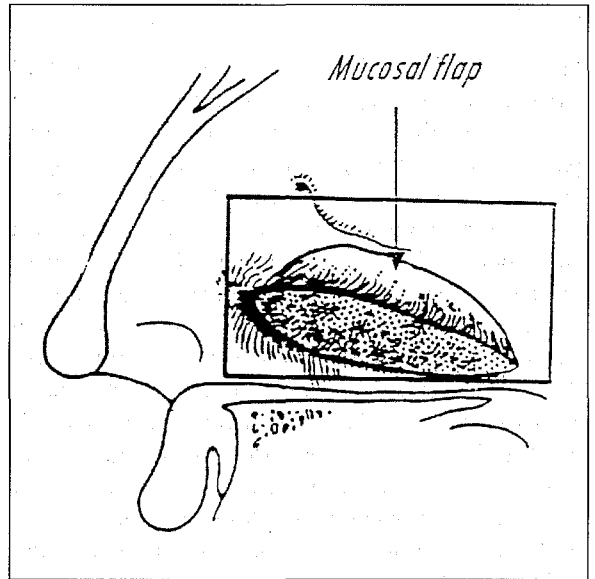
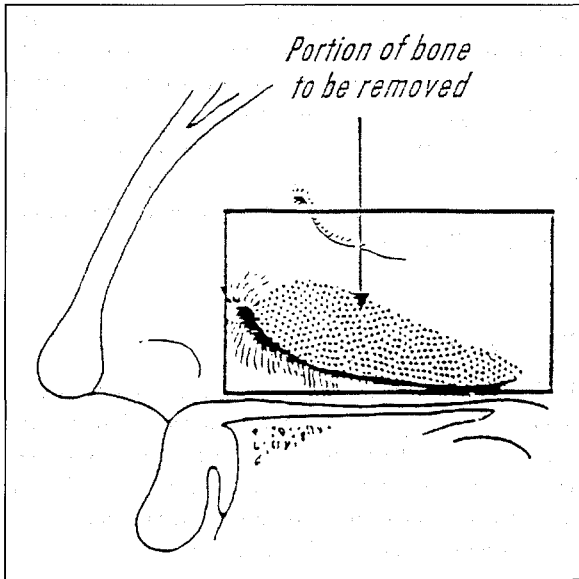


Fig. 1: Medical View of inferior turbinate—shaded area demonstrates bone and lateral mucosa to be resected.

Fig. 2: Medical view of inferior turbinate demonstrating elevation of the mucosal flap on medical surface.

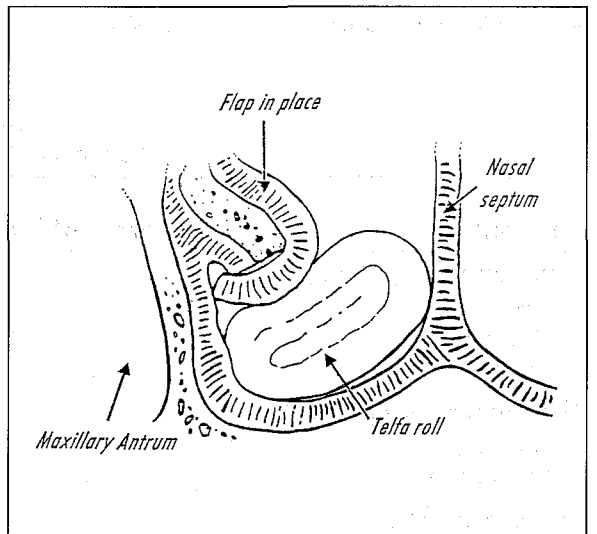
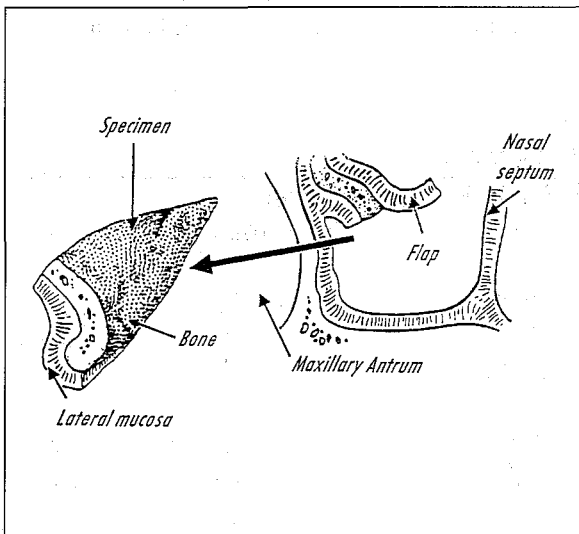


Fig. 3: Turbinate remnant after resection.

Fig. 4: Medical mucosal flap's folded over bone remnant and held in place by telfa roll.

Results

Fifteen patients underwent the conventional and 21 patients the endoscopic technique. The patients chart was reviewed for post-operative nasal discomfort, nasal passageway, dry throat, duration of surgery and hospital stay. With regard to nasal discomfort and dry throat, comparison between the conventional and the endoscopic technique revealed significant difference respectively except for nasal passageway. Majority of the patients had moderate nasal discomfort (53.3%) in the conventional technique compared to mild nasal discomfort (52.3%) in the endoscopic technique as shown in Table I. There was marked improvement in nasal passageway in both the techniques. In the conventional technique, majority of the patients had moderate throat symptoms (46.6%) compared to 52.3% with mild throat symptoms in the endoscopic technique. The average post-operative hospital stay in the conventional technique was 58 hours compared to endoscopic technique of 32 hours. In majority of the cases, the medial mucosa flap was easily elevated with no injury to the flap noted.

All patients in this series have a minimum of 3 months follow-up with complete evaluation including endoscopic examination at each visit. None of the

patients developed long term dryness or crusting problems in the mean follow-up of 3.8 months. An average of 94.2% of patients reported improvement in nasal passageway in both techniques compared to 5.6% with no improvement. The surgical time with endoscopic technique averages 7 minutes per side, compared to 9 minutes per side with the conventional technique (Table I).

Discussion

Endoscopic inferior turbinoplasty is a technique designed to be an adjunctive procedure to endoscopic sinus surgery, accounting for 10% of the cases in the author's experience which was consistent with that of Mark's study¹⁵. It is indicated for treatment of significant vasomotor rhinitis causing symptomatic nasal obstruction.

The main advantage of endoscopic turbinoplasty is in the visualisation during the procedure. Problems encountered during inferior turbinoplasty are damage to the mucosal flap or transection of the posterior blood supply. The former problem was not a rare encounter by the author. Elevation of the mucosal flap under headlight visualization may be difficult if the curvature of the turbinate bone prevents visualization of the

Table I
Post-operative Complaints

Complaints	Inferior Turbinate Reduction			
	Conventional (n=15)	%	Endoscopic (n=21)	%
Nasal discomfort (p=0.05)				
Mild	2	13.3%	11	52.3%
Moderate	8	53.3%	7	33.3%
Severe	5	33.3%	3	14.2%
Nasal passageway (p=0.66)				
No change	1	6.6%	1	4.7%
Improvement	14	93.3%	20	95.2%
Dry throat (p=0.02)				
Mild	2	13.3%	11	52.3%
Moderate	7	46.6%	8	38.0%
Severe	6	40.0%	2	9.5%

* Average surgical time (minutes) and the post-operative stay (hours) for the conventional and endoscopic technique was 9:7 and 58:52 respectively. The p value for the surgical time was 0.12 and for post-operative stay was 0.04

posterior half of the inferior turbinate resulting in tears in the flap or inadvertent avulsion of the posterior attachment. The improved visualization provided by the endoscope allows precise elevation of the mucosal flap and preservation of the posterior attachment of the mucosal flap, thus avoiding damage to the blood supply to the turbinate which can result in excessive intra-operative and post-operative bleeding¹⁵.

Endoscopic inferior turbinoplasty has the advantage over other turbinate procedures of preserving sufficient mucosa to avoid complications, while resecting enough to improve the airway significantly. There was a significant difference between the conventional and the endoscopic technique with regards to nasal discomfort ($p=0.05$) and dry throat ($p=0.02$). The severity of the symptoms was more marked by the conventional compared to endoscopic technique. The patient satisfaction was excellent with an average of 94.2% of patients who reported improvement in nasal passageway by both techniques but the difference was not significant. Topical nasal steroid spray was commenced in the rest 5.6% of patients who underwent conventional and endoscopic techniques with no improvement and the symptom benefits seem to be lasting. With the conventional turbinate reduction procedures, there is the concern of long term complications including dry throat, dry nose and atrophic rhinitis¹⁴. The average post-operative hospital stay involving the conventional technique (58 hours) was almost double compared to endoscopic technique (32 hours) which was statistically significant.

Endoscopic inferior turbinoplasty is not intended to replace completely the conventional inferior turbinate

reduction procedures. During septoplasty when endoscopic instrumentation is not required, the conventional procedure is still performed. This avoids the time and resources necessary to set up the endoscopic sinus surgery equipment. It is advantages during the performance of endoscopic sinus surgery to use the endoscopic technique for inferior turbinoplasty since it is performed with the same equipment and does not necessitate introduction of additional equipment¹⁵.

In conclusion, endoscopic inferior turbinoplasty is a simple and safe technique using endoscopic sinus surgery equipment. The significant post-operative complaints for inferior turbinate reduction was nasal discomfort and dry throat but the severity was more marked by the conventional compared to endoscopic technique. With the state of the art nasal endoscopy and with less severe nasal symptoms and reduced hospital stay, endoscopic inferior turbinoplasty is currently the procedure of choice at our center. It is also recommended as an adjunctive procedure during endoscopic sinus surgery when inferior turbinate hypertrophy is present. Pre and post-operative acoustic rhinomanometric evaluation will be more helpful in the near future.

Acknowledgements

I acknowledge with gratitude the cooperation of Mr Mohd. Nizam for the graphics, Dr K. G. Rampal for the statistical analysis and Dr Abdullah Sani (Head of Department of Otorhinolaryngology) for his valuable comments. I am thankful to Dr Khalid Yusoff (Dean Medical Faculty) and Dr Khalid Abdul Kadir (Director of Hospital) for permission to publish this data.

References

1. Mabry RL. Surgery of the inferior turbinate: How much and when? *Otolaryngology Head and Neck Surgery* 1984; 92: 571-76.
2. Raphael GD, Baranuik JN, Kaliner MA. How and why the nose runs. *J Allergy Clin Immunol* 1991; 87: 457-67.
3. Spector M. Partial resection of the inferior turbinates. *Ear Nose Throat J* 1982; 61: 200.
4. Fanous N. Anterior turbinectomy. A new surgical approach to turbinates hypertrophy. *Arch Otolaryngol Head Neck Surgery* 1986; 112: 850-52.
5. Courtiss EH, Goldwyn RM, O'Brien JJ. Resection of obstructing inferior turbinates. *Plast Reconstr Surg* 1978; 62: 249-57.
6. Martinez SA, Nissen AJ, Stock CR, *et al.* Nasal turbinate resection for relief of nasal Obstruction. *Laryngoscope* 1983; 93: 871-75.
7. Mabry RL. How I do it-plastic surgery. Practical suggestions on facial plastic surgery. Inferior turbinoplasty. *Laryngoscope* 1982; 92: 459-61.
8. Mabry RL. Inferior turbinoplasty: Patient selection, technique and long-term consequences. *Otolaryngol Head Neck Surg* 1987; 98: 60-66.
9. Jones AS, Lancer JM. Does submucosal diathermy to the inferior turbinates reduce nasal resistance to airflow in the long term? *J Laryngol Otol* 1987; 101: 448-51.
10. Principato JJ. Chronic vasomotor rhinitis: Cryogenic and other surgical modes of treatment. *Laryngoscope* 1979; 89: 619-38.
11. Terao A, Meshitsuka K, Suzuki H, Fukuda S. Cryosurgery on post-ganglionic fibres (posterior nasal branches) of the pterygo-palatine ganglion for vasomotor rhinitis. *Acta Otolaryngol* 1983; 96: 139-48.
12. Lenz H. Eight year's LASER surgery of the inferior turbinates in vasomotor rhinopathy in the form of LASER strip carbonization. *HNO* 1985; 33: 422-25.
13. Selkin SG. LASER turbinectomy as an adjunct to rhinoseptoplasty. *Arch Otolaryngol* 1985; 111: 446-49.
14. Freer OT. The inferior turbinate: Its longitudinal resection for chronic intumescence. *Laryngoscope* 1911; 21: 1136-44.
15. Marks S. Endoscopic inferior turbinoplasty. *Am J rhinol* 1998; 12(6): 405-07.