

# Traumatic Herniation of the Heart into the Right Hemithorax

P S Wong, FRCS-CTh, Cardiothoracic Surgery Unit, Sultanah Aminah Hospital, 80100 Johor Bahru, Johore

## Summary

Pericardial rupture after blunt chest trauma is described in the literature. This case report summarises our experience with a 22-year old male patient who suffered blunt chest trauma during a motor vehicle accident. On admission no serious injuries could be detected, but 3 hours later, displacement of the heart to the right hemithorax combined with sudden cardiac failure appeared. Emergency thoracotomy revealed a right-sided rupture of the pericardium with complete herniation of the heart into the right pleural cavity and consequent strangulation by the margins of the pericardial defect.

**Key Words:** Pericardial rupture; Blunt chest trauma; Cardiac luxation

## Introduction

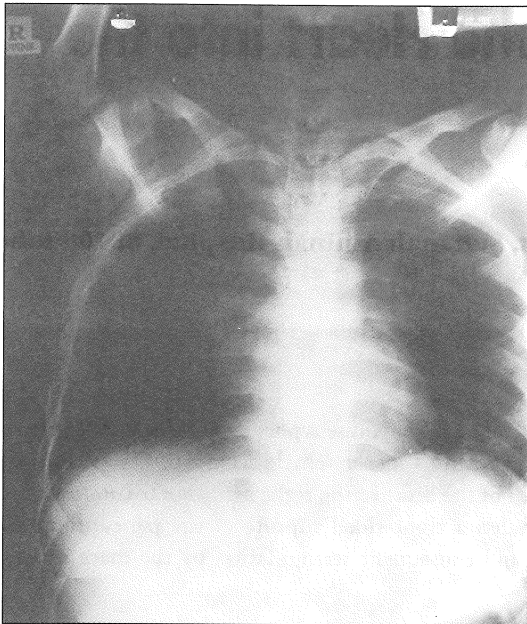
Herniation of the heart with subsequent torsion is extremely rare, and fatal if unrecognised. In most cases these injuries are lethal and are therefore diagnosed at post-mortem. The majority of cardiac herniations occur after surgically created defects in the pericardium, and more uncommonly through congenital pericardial defects. Blunt trauma to the chest may rupture the pericardial sac, allowing cardiac herniation to occur with subsequent torsion or entrapment within the edges of the pericardial defect<sup>1,2</sup>. We report the case of a patient with cardiac herniation following an isolated pericardial rupture secondary to blunt trauma.

## Case Report

A 22-year old male patient suffered blunt chest trauma after being involved with a high-speed motor cycle accident. He skidded on the ground and his right chest hit the tyre of a stationary car. The patient was admitted to the local hospital and there was no evidence of any life-threatening injuries. He was reported to suffer from

soft tissue injuries to his right chest, left upper limb, and forehead. On physical examination the patient was pale with blood pressure of 140/85mmHg. The pulse rate was 90 beats per minute and regular. Normal heart sounds were heard. Breath sounds were reduced. Percussion of the chest was normal. There was mild surgical emphysema over his right chest wall. There were no significant neurological or abdominal signs. Initial radiological examination of the chest (Fig. 1) and skull showed no evidence of fracture, haemo- or pneumo-thorax or enlargement of his mediastinum.

Three hours after admission he became dyspnoeic and had features of pericardial tamponade, including tachycardia, hypotension, raised jugular venous pulse with a positive Kussmaul's sign, and features of poor cardiac output. Working on a diagnosis of a tension pneumothorax, a right chest drain was inserted but with no significant improvement of his symptoms. Chest radiograph showed herniation of the heart into the right pleural cavity, right pneumothorax and pneumomediastinum (Fig. 2). The patient was transferred to the operating room and emergency right

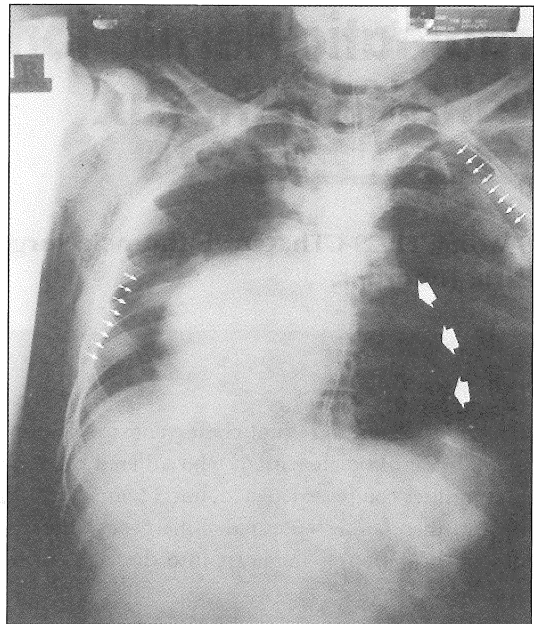


**Fig. 1: Chest radiograph of the patient on admission to hospital.**

thoracotomy was performed. The heart was found to be rotated and completely herniated into the right pleural cavity and the margins of the pericardial defect, measuring 12cm by 8cm, were causing constriction of the heart preventing it from returning into the pericardial cavity. The heart was relocated back into the pericardial cavity with immediate improvement of the haemodynamic stability. A Dacron prosthetic patch was used to repair the defect taking care not to injure the phrenic nerve, which was along the posterior margin of the pericardial defect. The patient was discharged 3 weeks following surgery.

### Discussion

Pericardial rupture secondary to trauma is usually related to a high velocity trauma. The predominant side of the pericardial tear is seen mainly on the left side<sup>1,2</sup>. In a retrospective series of 20,000 patients admitted to a level 1 trauma centre, 59 patients were found to have pericardial rupture<sup>1</sup>. Isolated pericardial rupture was seen in only 17 patients (<0.1%). In a collective review



**Fig. 2: Chest radiograph of patient showing herniation of the heart into the right pleural cavity with small arrows showing bilateral pneumothoraces. Large arrow shows pneumopericardium.**

of 142 patients with pericardial rupture, Clark et al<sup>2</sup> reported an overall mortality of 25%. In another series<sup>1</sup>, a mortality rate of 64% was reported. Associated injuries of the heart have been reported to occur in 23 to 28% of patients with pericardial injuries<sup>1,2</sup>. Most of these consist of chamber rupture.

Symptoms due to pericardial rupture depend mainly on the underlying trauma and associated injuries<sup>1,2</sup>. In the case of isolated pericardial rupture symptoms may be mild or absent. The effects of cardiac torsion are related to the nature of the cardiac malposition. For left-sided herniation, patients may present with hypotension due to strangulation of the ventricular walls by the edges of the pericardial sac. For right-sided cardiac herniations, superior vena cava syndrome or features of pericardial tamponade develops as a result of complete torsion on an axis formed by the inferior vena cava and the great

vessels at the base of the heart<sup>2</sup>. Clinically, patients may develop retrosternal pain, syncope, cardiac arrhythmia, and even sudden cardiac death. The apex beat may be displaced. There may be electrocardiographic changes of axis deviation and non-specific changes like ST-T changes and right bundle branch block. Cardiac herniation secondary to traumatic rupture of the pericardium had been reported to occur intermittently giving rise to intermittent episodes of cardiac tamponade. Delayed presentation of cardiac luxation secondary to trauma has also been reported as late as 6 months following the initial injury<sup>3</sup>.

There is no single test that can be used as a screening tool. Detection of this injury in a patient with multiple chest and other injuries is difficult, especially if this per se is a rare entity. In this case, it was fortuitous that a chest radiograph was performed after placement of a

right chest tube for a suspected tension pneumothorax. Plain chest radiographs is usually diagnostic. Most commonly, pericardial rupture is an incidental finding during surgery. Once recognised, treatment is relatively straight forward with either a direct suture repair if the defect is small, or if the defect is large, it is covered with a prosthetic patch. The outcome of this injury is determined usually by the successful management of associated injuries<sup>1,2</sup>. However, in the case of an isolated cardiac herniation secondary to traumatic rupture of the pericardium, the outcome can be favourable if it is detected early enough.

### Acknowledgement

The author would like to thank the Director General of Health, Ministry of Health Malaysia for his kind permission to publish this paper.

---

### References

1. Fulda G, Rodriguez A, Turney SZ, Cowley RA. Blunt traumatic pericardial rupture: a 10 year experience 1979 to 1989. *J Cardiovasc Surg* 1990; 31: 525-30.
2. Clark DE, Wiles III CS, Lim MK, Dunham CM, Rodriguez A. Traumatic rupture of the pericardium. *Surgery* 1983; 93: 495-503.
3. Watkins BM, Buckley DC, Peschiera JL. Delayed presentation of pericardial rupture with luxation of the heart following blunt trauma: a case report. *J Trauma* 1995; 38: 368-9.