

The Biopsy of Nonpalpable Breast Lesions Detected on Mammography

M A Zulfiqar, M.Med (Radiology)*, S Nair, FRCS**, M Lily, MPath***, M A Norizan, DCP***, *Department of Radiology, Hospital Universiti Kebangsaan Malaysia, **Department of Surgery, Hospital Kuala Lumpur, ***Department of Pathology, Hospital Kuala Lumpur

Summary

This is a review of the positive biopsy rate of nonpalpable breast lesions detected on mammography. The histology of 130 hookwire excision biopsy from 1990 to 1995 and the cytology of 39 stereotactic fine needle aspiration cytology in 1995 were reviewed. The yearly positive biopsy rate of each procedure was determined. In 1990, the positive biopsy rate for hookwire excision biopsy was 15%, in 1991 20%, in 1992 11%, in 1993 17%, in 1994 33% and in 1995 39%. In 1995, the positive biopsy rate for stereotactic fine needle aspiration cytology was 21%. The positive biopsy rate for hookwire excision biopsy had improved from 15% in 1990 to 39% in 1995.

Key Words: Mammography, Nonpalpable lesions, Biopsy

Introduction

The main purpose of mammography is to detect early breast carcinoma in asymptomatic patients. Early breast carcinoma is defined as a nonpalpable lesion that is less than 1cm in diameter and has not involved the lymph nodes. Early breast carcinoma may be a cluster of calcifications in isolation without any associated mass.

There is no formal breast screening program in Malaysia. The majority of mammography patients at Hospital Kuala Lumpur are symptomatic patients with complaints such as breast lump or lumpiness, breast pain or nipple discharge. The rest of the patients comprise of patients on follow-up subsequent to a mastectomy or breast conservation surgery, women on hormone replacement therapy and those with a family history of breast cancer.

The positive biopsy rate (percentage of malignant biopsies out of the total number of biopsies done) of nonpalpable breast lesions provides a valuable indicator to evaluate the performance of a mammography unit.

Competent radiographers, meticulous mammographic technique and good maintenance of equipment will produce the good quality images that are required to perceive an abnormality. Proper training, the interpretive skill and experience of the radiologist are required to determine the significance of a mammographic finding. Therefore, a high positive biopsy rate would reflect better upon the performance of the mammographic unit.

The purpose of this report is to review the positive biopsy rate of nonpalpable breast lesions detected on mammography.

Materials and Methods

The nonpalpable breast lesions detected on mammography were categorized according to the degree of suspicion for malignancy based on (1) the mammographic features of calcifications such as the size, number, shape, margins and distribution and (2) the mammographic features of nodules such as the margins,

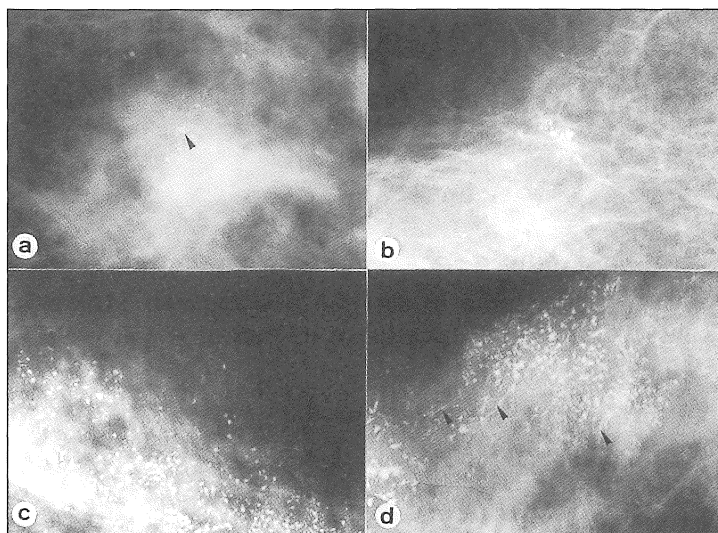


Fig. 1: Magnified views of microcalcifications. (a) A cluster of calcifications (arrow head) with smooth outlines. Mammographically classified as indeterminate and histologically proven to be fibrocystic change. (b) A cluster of calcifications with irregular outlines. Mammographically classified as suspicious and histologically proven to be fibrocystic change. (c) Irregular calcifications of varying shapes and sizes showing a 'dot-dash' appearance. Mammographically classified as malignant and histologically proven to be ductal carcinoma in situ. (d) Irregular calcifications with some showing a ductal distribution (arrow heads). Mammographically classified as malignant and histologically proven to be ductal carcinoma in situ.

associated calcifications, density and location¹⁻⁴. The nonpalpable breast lesions were then classified into 5 categories in order of increasing likelihood of malignancy i.e. benign, most likely benign, indeterminate, suspicious and malignant (Fig. 1 and Fig. 2).

From 1990 to 1993, lesions that were classified as indeterminate, suspicious or malignant had hookwire (HW) excision biopsy and lesions that were classified as most likely benign had mammographic follow-up for a period of 3 years³. The first follow-up examination was performed 6 months after the initial study. If the lesion remained unchanged at the 6 month study, another follow-up examination was done after a further 6 months interval. If the lesion remained stable, 2 additional examinations were performed at yearly intervals.

In 1994, only lesions that were classified suspicious or malignant had HW excision biopsy and lesions that were classified as most likely benign or indeterminate had mammographic follow-up for a period of 3 years.

In 1995, only lesions that were classified as malignant had HW excision biopsy. The indeterminate and suspicious lesions had stereotactic fine needle aspiration cytology (SFNAC). The decision to proceed to HW excision biopsy or otherwise was based on the cytology report. Lesions with cytology findings of malignant cells, cells suspicious of malignancy or atypical cells proceeded to HW excision biopsy. Lesions with benign cytology findings but suspicious mammographic findings had repeat SFNAC. Lesions with benign cytology findings and indeterminate mammographic

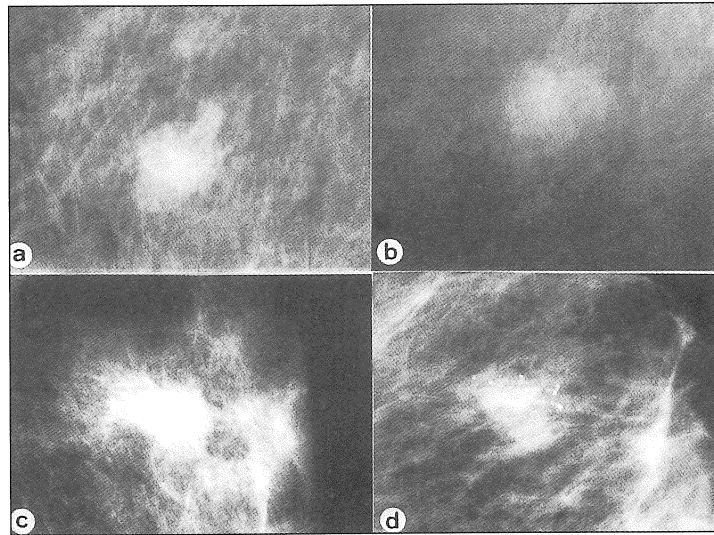


Fig. 2: Magnified views of nodules. (a) A lobulated nodule with well-defined margins. Mammographically classified as indeterminate and histologically proven to be fibroadenoma. (b) A nodule with ill-defined margins. Mammographically classified as suspicious and histologically proven to be fibroadenoma. (c) A nodule with spiculated margins. Mammographically classified as malignant and histologically proven to be infiltrating ductal carcinoma. (d) A spiculated nodule with associated irregular calcifications. Mammographically classified as malignant and histologically proven to be infiltrating ductal carcinoma.

findings had routine follow-up. Lesions with inconclusive findings had repeat SFNAC.

From 1990 to 1994, 112 nonpalpable breast lesions that were classified as indeterminate, suspicious or malignant on mammography had HW excision biopsy. In 1995, 10 lesions classified as malignant on mammography and 8 lesions with SFNAC findings of malignant cells, cells suspicious of malignancy or atypical cells had HW excision biopsy.

In 1995, 39 lesions classified as indeterminate or suspicious on mammography had SFNAC. This involved 33 patients (1 patient had 3 SFNAC and 4 patients had 2 SFNAC).

The histology of the 130 HW excision biopsies and the cytology of the 39 SFNAC were reviewed. The yearly positive biopsy rate for each procedure was determined.

Results

The majority of the lesions that had HW excision biopsy were calcifications. The rest were either nodules or nodules with calcifications (Table I). Twenty percent of the lesions were malignant. More than half of the malignant lesions proved to be infiltrating ductal carcinoma. Less than a third were ductal carcinoma in situ (Table II).

The positive biopsy rate for HW excision biopsy in 1990 was 15%, in 1991 20%, in 1992 11%, in 1993 17%, in 1994 33% and in 1995 39%. The average positive biopsy rate for the 6 years was 20% (Table III).

The positive biopsy rate for SFNAC in 1995 was 21% (Table IV). Thirty-eight percent had inconclusive cytology findings. Of the 8 patients who had HW excision biopsy following SFNAC, 6 were malignant on histology and 2 were benign (Table V).

Table I
Mammographic Abnormality and Hookwire Excision Biopsy Result

Mammographic Abnormality	Histology		Number of cases
	Malignant	Benign	
Calcifications	16 (20%)	60 (80%)	76 (60%)
Nodule	6 (10%)	32 (90%)	38 (30%)
Nodule with calcifications	4 (25%)	12 (75%)	16 (10%)
Total	26 (20%)	104 (80%)	130

Table II
Mammographic Abnormality and Histology of Malignant Lesions

Mammographic Abnormality	Histology			Total
	Ductal Carcinoma in Situ	Infiltrating Ductal Carcinoma	Infiltrating Lobular	
Calcifications	7	9	-	16
Nodule	-	5	1	6
Nodule with calcifications	1	3	-	4
Total	8 (31%)	17 (65%)	1 (4%)	26

Table III
Positive Biopsy Rate of Hookwire Excision Biopsy

Year	Number of Cases	Number of Positive Cases	Positive Biopsy Rate
1990	7	1	15%
1991	10	2	20%
1992	35	4	11%
1993	43	7	17%
1994	17	5	33%
1995	18	7	39%
Total	130	26 (20%)	

Table IV
Mammographic Abnormality and Stereotactic Fine Needle Aspiration Cytology Result

Mammographic Abnormality	Cytology			Total
	Malignant, Suspicious of Malignancy or Atypical	Benign	Inconclusive	
Calcifications	4	7	9	20
Nodule	4	7	5	16
Nodule with calcifications	-	2	1	3
Total	8 (21%)	16 (41%)	15 (38%)	39

Table V
The Histology of HW Excision Biopsies of Lesions with a Positive SFNAC

Mammographic Abnormality	Histology			Total
	Ductal Carcinoma in Situ	Infiltrating Ductal Carcinoma	Fibrocystic Change	
Calcifications	1	2	1	4
Nodule	-	3	1	4
Nodule with calcifications	-	-	-	-
Total	1 (12.5%)	5 (62.5%)	2 (25%)	8

Discussion

Although the average positive biopsy rate for the 6 years was 20%, there was a steady increase of the positive biopsy rate from 15% in 1990 to 39% in 1995.

In 1994 there was a decrease in the total number of HW excision biopsies done although the positive biopsy rate was 33%. The reason for this decrease was because a review of the first 3 years' experience had reported an average positive biopsy rate of only 17%.⁵ As a result of this report, the decision to do HW excision biopsy became more discriminate. Patients with lesions classified as indeterminate were placed on mammographic follow-up. This change in approach however caused increased patient anxiety. Follow-up mammography meant waiting for a period of three years before a decision was made on whether a lesion was

benign or malignant. During this period no definitive diagnosis could be offered to the patient. Recognizing these problems, SFNAC was introduced in 1995.

In 1995, 39 SFNAC were done on lesions that were classified as indeterminate or suspicious. The positive biopsy rate for SFNAC was 21%. Cases with cytology findings of malignant cells, cells suspicious of malignancy or atypical cells had HW excision biopsy. This change in approach increased the positive biopsy rate of HW excision biopsy to 39% in 1995.

Since SFNAC did not require hospitalization or general anaesthesia it was more cost-effective compared to HW excision biopsy. Further, it did not result in unnecessary scarring especially since the majority of nonpalpable lesions proved benign. However, SFNAC was not that simple. More than a third of the aspirates had

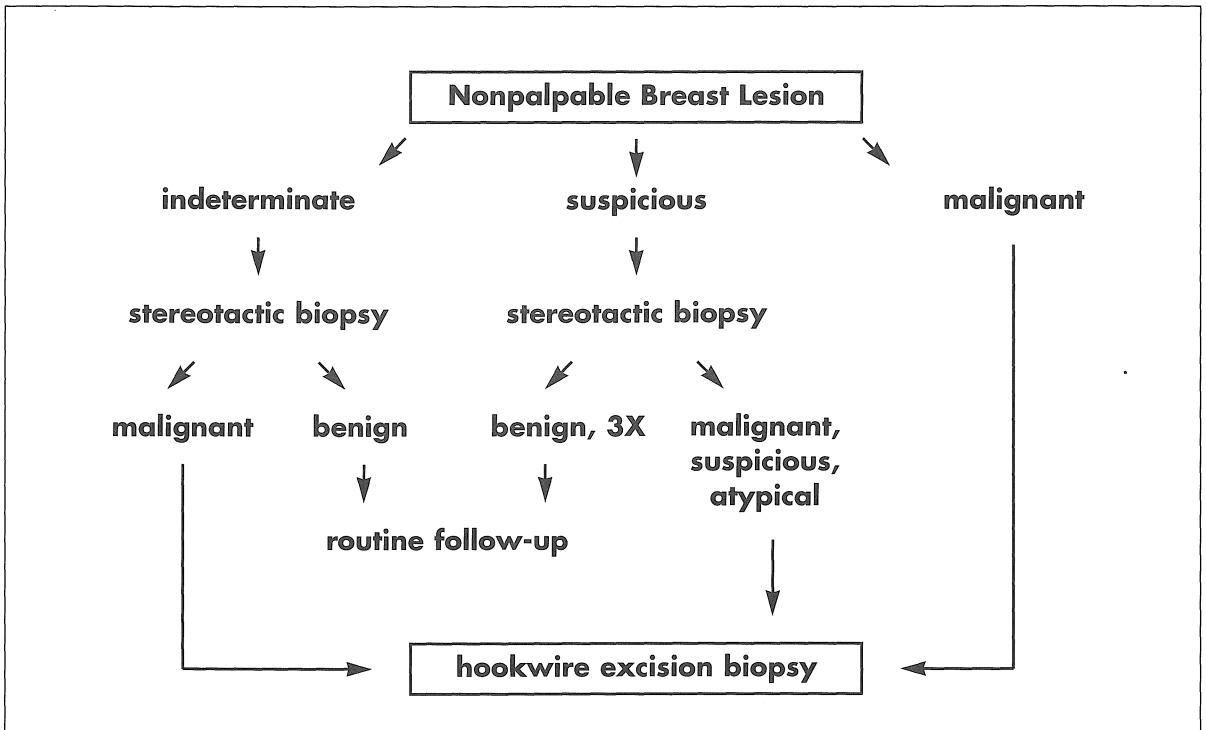


Fig. 3: Approach to the investigation of a nonpalpable breast lesion detected on mammography.

inconclusive cytology findings. As a result of this, stereotactic core biopsy was introduced in 1996. The outcome of this change in technique will be the subject of a forthcoming study.

From this review of our 6 years experience, the most appropriate approach for the assessment of nonpalpable breast lesions would be to do SFNAC as an initial investigation for indeterminate and suspicious lesions. Lesions that had cytology findings of malignant cells, cells suspicious of malignancy or atypical cells proceeded to HW excision biopsy. Lesions classified as suspicious on mammography and found to have a negative cytology had repeat SFNAC. These were placed on routine follow-up if 3 consecutive biopsies proved negative. Indeterminate lesions that proved benign on cytology were placed on routine follow-up (Fig. 3).

The positive biopsy rate of 39% in 1995 was comparable with the 20% to 40% positive biopsy rate reported in other series⁶⁻⁹. A level lower than 20% would mean that the degree of suspicion for malignancy was high and would result in an unacceptably high benign biopsy rate. However, a positive biopsy rate of more than 40% would mean that the degree of suspicion for malignancy was low and this could result in missed early breast carcinoma.

Conclusion

The positive biopsy rate for HW excision biopsy had improved from 15% in 1990 to 39% in 1995. The practice of doing stereotactic biopsy prior to doing an excision biopsy would improve cost-effectiveness.

References

1. Tabar L, Dean PB. Circumscribed Lesions. Stellate Lesions. Calcifications. In: Teaching Atlas of Mammography (2nd ed). New York: Thieme Inc. 1986; 17-210.
2. Kopan DB. Mammography. In: Breast Imaging. Philadelphia: JB Lippincott Co 1989; 34-2256.
3. Homer MJ. Localizing Signs of Breast Cancer. In: Mammographic Interpretation. A practical Approach. New York: McGraw-Hill Inc. 1991; 30-58.
4. Zulfiqar MA. Asas Bagi Pentafsiran Imej. Dalam: Atlas Pengajaran. Mamografi dan Ultrasonografi Buah Dada. Kuala Lumpur: Dewan Bahasa dan Pustaka 1995; 7-9.
5. Zulfiqar A, Param V, Meah FA, Nair S, Siti-Aishah MA, Norizan A. Prebiopsy Localization of Nonpalpable Breast Lesions. Med J Malaysia 1993; 48: 317-24.
6. Tresadern JC, Asbury D, Hartley G, Sellwood RA, Borg-Grech A, Watson RJ. Fine-wire localization and biopsy of nonpalpable breast lesions. Br J Surg 1990; 77: 320-2.
7. Johnston JA, Clee CZ. Analysis of 308 Localisation Breast Biopsies in New Zealand Hospital. Australas Radiol 1991; 35: 148-51.
8. Rissanen TJ, Makarainen HP, Mattila SI, Karttunen AI, Kiviniemi HO, Kallioinen MJ, Kaarela OI. Wire Localized Biopsy of Breast Lesions: A Review of 425 Cases Found in Screening or Clinical Mammography. Clinical Radiology 1993; 47: 14-22.
9. Wilson TE, Helvie MA, August DA. Breast Cancer in the Elderly Patient: Early Detection with Mammography. Radiology 1994; 190: 203-7.