

Tumoral Cystitis In Children

M A Zulfiqar, M.Med.*, A M Zaleha, M.Med.**, I Zulkifli, M.Med.***, W Y Chia****, FRCS, S.A. Samad, FRCR*, *Department of Radiology, Universiti Kebangsaan Malaysia, **Department of Diagnostic Imaging, Hospital Kuala Lumpur, ***Department of Paediatrics, Universiti Kebangsaan Malaysia, ****Formerly of the Department of Surgery, Hospital Kuala Lumpur

Summary

Three children aged 3 - 11 years had ultrasonography of the urinary tract for the investigation of dysuria and haematuria. A bladder mass was seen in these 3 children. One child had computed tomography scan, cystoscopy and bladder biopsy because rhabdomyosarcoma was considered. The biopsy revealed an inflammatory process. The urine culture of the other 2 children revealed *E. coli*. On ultrasonography, the inflammatory mass may appear homogeneously hypoechoic or may contain moderate level echoes. The mucosal surface of the mass may be smooth or lobulated. It is important to consider an infective cause for a bladder mass in children because computed tomography, cystoscopy and biopsy may be avoided.

Key Words: Inflammatory cystitis, Pseudotumoral cystitis, Bladder tumour, Ultrasonography

Introduction

A bladder mass detected in a child with haematuria would raise a suspicion of rhabdomyosarcoma. However, inflammatory infiltration with focal proliferation of the bladder epithelium could simulate neoplasm¹.

The purpose of this report is to illustrate the ultrasonographic appearance of the inflammatory bladder mass. It is important to recognize the ultrasonographic appearance because ultrasonography is the preferred imaging modality of the urinary tract. Intravenous urography and micturating cystourethrography are less favourable modes of imaging especially in children because of the ionizing radiation involved. This report also highlights the importance of considering an infective cause for a bladder mass in children with dysuria and haematuria.

Case Reports

Case 1

A 10 year-old boy had 2 episodes of gross haematuria, dysuria and frequency. On examination, there was

suprapubic tenderness. Urinalysis showed gross haematuria and numerous pus cells. Urine culture was sterile. He had leukocytosis with a lymphocytic predominance. Ultrasonography of the bladder showed a hypoechoic mass at the fundus of the bladder (Fig 1A, Fig 1B). Bladder rhabdomyosarcoma was suspected. A computed tomographic scan showed thickened and irregular bladder mucosa at the fundus. Cystoscopic examination 5 days after admission revealed hyperaemic bladder mucosa but no mass comparable to that seen on ultrasonography. Biopsy revealed fragments of fibrous tissue with groups of epithelial cells and leukocytic infiltration, indicating an inflammatory process.

Case 2

A 3 year-old girl had gross haematuria and fever for 1 day. Following this she developed difficulty in micturition, dysuria and suprapubic pain for 1 week. On examination, the patient had suprapubic tenderness. Ultrasonography of the bladder showed a lobulated mass of moderate level echogenicity at the bladder fundus and trigone (Fig. 2A). The patient had earlier

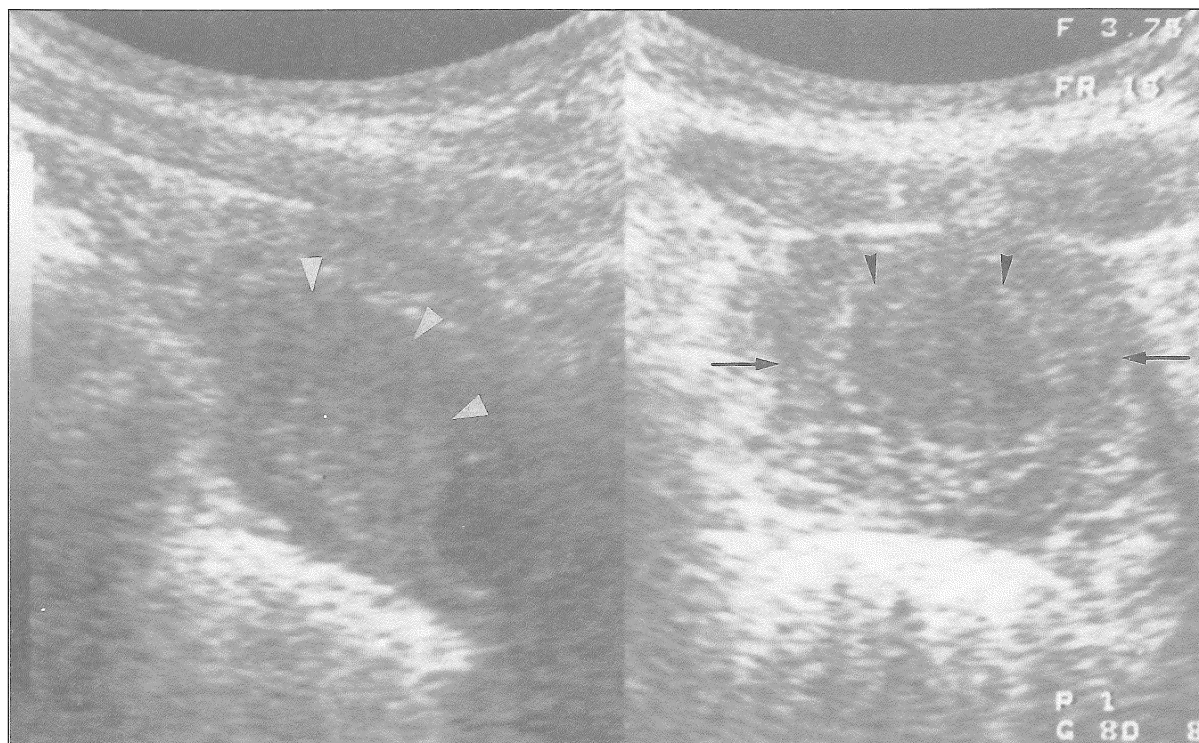


FIG. 1A: Sagittal scan of the bladder shows a homogenously hypoechoic mass, 2x2x3 cm, at the fundus of the bladder. The surface of the mass is smooth (arrow heads).

FIG. 1B: Transverse scan of the bladder fundus shows the mass (arrow heads) within a thick-walled bladder (arrows).

been treated with co-trimoxazole by a general practitioner. Treatment with cephalexin was started empirically while awaiting urine culture results. The urine culture and sensitivity revealed *E. coli*, which was resistant to co-trimoxazole and sensitive to cephalexin. A follow-up ultrasonography 1-week later showed a reduction in the thickness of the mass. Two weeks later, the bladder was normal (Fig. 2B).

Case 3

An 11 year-old boy had 1 week of dysuria and haematuria in the form of clots and fresh blood. On examination, the patient had suprapubic tenderness. Urine culture revealed *E. coli* and patient was treated with co-trimoxazole. Ultrasonography of the bladder showed a hypoechoic mass at the bladder fundus. Three weeks later the bladder was completely normal.

Discussion

Tumoral cystitis is an uncommon inflammatory process of the bladder¹. The clinical presentation is that of acute or subacute cystitis. Tumoral cystitis is characterized by an inflammatory mass, which simulates a bladder neoplasm. The condition usually affects the bladder base and trigone and may cause ureteric obstruction. Histologically, the inflammatory mass has been described as proliferative cystitis, bullous cystitis, eosinophilic cystitis, cystitis follicularis, cystitis cystica and cystitis glandularis². The cause of this condition is not clear. In some cases it is a sequelae of bacterial or viral infection. Allergy and hypersensitivity reaction has also been implicated.

The clinical presentation of the 3 cases reported is suggestive of acute haemorrhagic cystitis, which is the

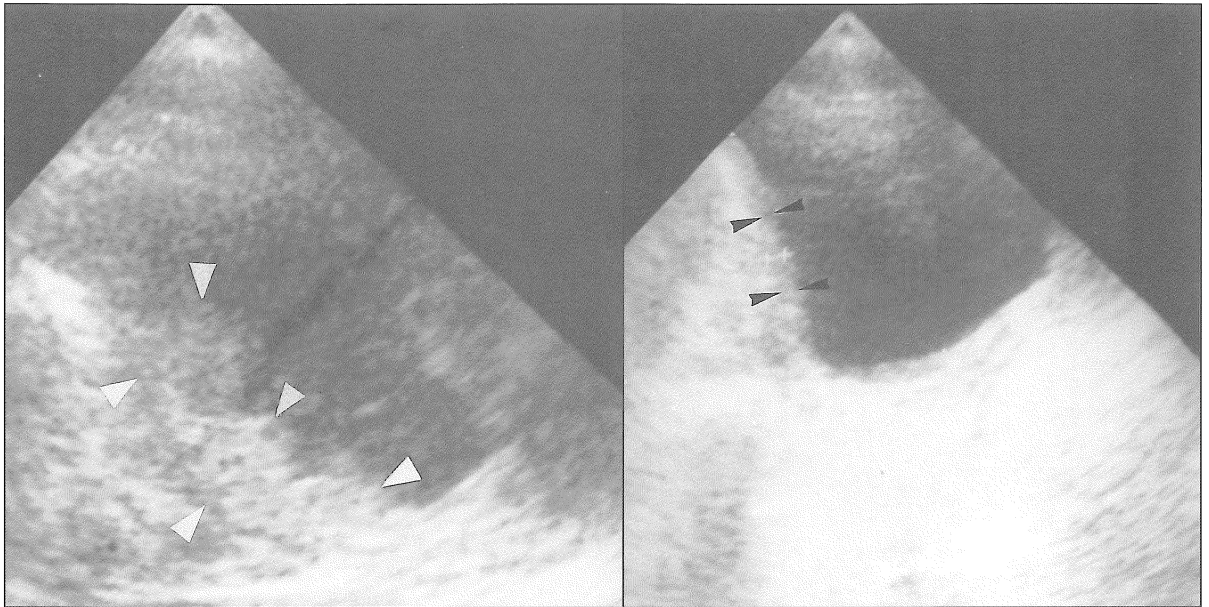


FIG. 2A: Sagittal scan of the bladder shows a lobulated mass of moderate level echogenicity (arrow heads), 1 cm thick, at the fundus and trigone.

FIG. 2B: Sagittal scan of the bladder two weeks after antibiotic shows a normal bladder wall (arrow heads), 2 mm thick.

commonest cause of gross haematuria in children³. Acute haemorrhagic cystitis is characterized by gross haematuria and symptoms of bladder inflammation. In children, this condition is self-limiting and subsides in a few days to 2 or 3 weeks without any complications. The majority has no known cause and about a third of cases are due to adenovirus type 2 or *E. coli* infection. The presence of leukocytosis with a lymphocytic predominance and sterile urine culture suggest a viral cystitis in Case 1. In Cases 2 and 3, *E. coli* was isolated. In these 2 cases since an inflammatory condition was considered, computed tomography, cystoscopy and biopsy were avoided. Treatment with antibiotics and follow-up ultrasonography showed the bladder mass had subsided by 2 to 3 weeks.

The ultrasonographic appearance of cystitis are variable and may be diffuse or focal. Cystitis may appear as a diffuse thickening of the bladder wall or as a focal mass simulating a neoplasm. A hypochoic bladder mass should raise the possibility of an inflammatory condition - the hypochoic appearance indicating gross

oedema. This was seen in Cases 1 and 3. However, in Case 2, the mass was lobulated and contained moderate level echoes. This ultrasonographic appearance cannot be differentiated from a neoplastic lesion such as rhabdomyosarcoma. In Case 2, the diagnosis of tumoral cystitis was based on the clinical symptoms of dysuria and suprapubic pain and confirmed by the isolation of *E. coli* in the urine.

Ultrasonography after one week of antibiotic would show evidence of resolution of the inflammatory mass. Ultrasonographic follow-up should continue at between 2 to 4 weeks interval until the bladder appears completely normal. However, if after one week of antibiotic, there is no evidence of resolution either clinically or on ultrasound then biopsy is indicated.

Conclusion

The ultrasonographic appearance of inflammatory cystitis may simulate bladder neoplasm. The lesion may

be hypoechoic or hyperechoic, smooth or lobulated. Symptoms of cystitis, such as dysuria, suprapubic pain and fever are relevant in making a diagnosis of tumoral cystitis. A child with symptoms of cystitis, haematuria and a bladder mass on ultrasonography should have the urine sent for culture and sensitivity, followed by empirical antibiotic therapy and ultrasonographic follow-up after one week. It is important to consider an infective cause for a bladder mass in children because

cystoscopy, biopsy and unnecessary irradiation with computed tomography may be avoided.

Acknowledgement

I would like to thank Encik Kamarulzaman Othman of the Medical Illustration Unit, Faculty of Medicine, Universiti Kebangsaan Malaysia for the photographs.

References

1. Currarino G, Wood B, Majd M. Abnormalities of the pelvicalyceal system, ureter, bladder and urethra. In Caffey's Pediatric X-ray Diagnosis. Mosby, 1993: 1282 - 4.
2. Hoeffel J C, Drews K, Gassner J, Arnaudin A. Pseudotumoral cystitis. *Pediatr Radiol* 1993; 23: 510 - 4.
3. Mufson M A, Belshe Radiologi B, Horrigan T J, Zoller L M. Cause of hemorrhagic cystitis in children. *A.J. Dis Child* 1973; 126: 605 - 9.