

Efficacy of *Radix Ginseng* Against Reperfusion After Regional or Global Ischemia in the Dog: An Assessment on Myocardial Ultrastructure

S M Yuan, MD, K Pu, C R Gao, Q Wang, MD, Department of Cardiothoracic Surgery, The 254 Hospital of Tianjin, Tianjin, People's Republic of China

Summary

Background Comparisons between reperfusion injuries after regional and global ischemia remain uncertain. The efficacy of *Radix Ginseng* against reperfusion injury on myocardial ultrastructure after either experimental regional or global ischemia has not been studied.

Methods 20 mongrel dogs were divided randomly into 2 groups for the regional and global ischemia models (Groups 1 and 2), and further into 4 subgroups: 2 control (1A and 2A), and 2 experimental (1B and 2B). Animals received a 45 minute ischemic interval before reperfusion, by coronary ligation in the regional model, and under normothermic cardiopulmonary bypass in the global model. In the experimental subgroups, *Injectio Radix Ginseng Compositae* was given continuously by a roller pump for 1 hour. Ultrastructural alterations of the myocardium were assessed.

Results The myocardial mitochondrial ultrastructure of the ischemic region was better in Subgroup 1B than in Subgroup 1A. During warm cardioplegia, it showed more deterioration in Subgroup 2A than in Subgroup 2B. The introduction of *Injectio Radix Ginseng Compositae* made mitochondrial structures less severe than in the controls. Changes in the ischemic myocardium appeared more severe than the reperfused myocardial structure in the same subgroup.

Conclusion Reperfusion injury after ischemia is more severe in the global model by normothermic cardiopulmonary bypass than in regional model by coronary ligation; *Injectio Radix Ginseng Compositae* has effectiveness in protection against myocardial reperfusion injury after ischemia; and *Injectio Radix Ginseng Compositae* might be considered as a component of cardioplegia in open heart surgery.

Key Words: Mitochondria, *Radix Ginseng*, Reperfusion injury

Introduction

With regard to the assessment of myocardial preservation, ultrastructural changes have been evaluated in isolated¹⁻³, and perfused human heart⁴, respectively. Of the latter, both the regional⁵ and the global models⁶ were involved. However, comparisons of myocardial pathologic alterations between the

regional and the global ischemic models remain uncertain.

Materials and Methods

20 healthy mongrel dogs (obtained from Tianjin Experimental Animal Center, fed on germ free food under standard housing conditions, and received

human care in compliance with the "Principle of Laboratory Animal Care" formulated by the National Society for Medical Research) weighing 11 to 16.5 kg were divided randomly into 2 groups, the regional and the global ischemia models (Groups 1 and 2), and further into 4 subgroups: 2 control (1A and 2A), and 2 experimental (1B and 2B). The animals were anesthetized with 2.5% thiopental sodium (Shanghai Xinya Pharmaceutical Factory, Shanghai, China) (1 ml/kg) and then intubated. Animals in Group 1 were for the normothermic regional ischemia by coronary ligation, and in Group 2 for the global, under normothermic cardiopulmonary bypass (CPB), all with a 45-minute ischemia interval. Subgroups B received *Injectio Radix Ginseng Compositae* (a standard preparation of Angel Power Allied Pharmaceutical Company of Tianjin, Tianjin, China; composed mainly of 16.2 g/dl of *Radix Ginseng* associated with 16.2 g/dl of *Rhizoma Ligustici Chuanxiong* and 21.6 g/dl of *Radix Polygoni Multiflori*) as experimental subgroups. Subgroups A were the controls.

In Group 1, through a left thoracotomy, an inflatable occluder was placed around the left anterior descending coronary artery (LAD) between the first and second main diagonal branches, approximately 2 cm from the origin of the LAD⁷. As soon as the LAD was occluded, *Injectio Radix Ginseng Compositae* was infused continuously, via the femoral arterial indwelling catheter to the ascending aorta with a roller pump at a rate of 3 to 4 ml/min, and a total amount of 10 ml/kg for 1 hour in Subgroup 1B.

CPB was instituted through a sternotomy in Group 2, and warm blood cardioplegia was given antegradely, as described by Yuan⁸. The aorta was crossclamped for 45 minutes. *Injectio Radix Ginseng Compositae* of 10 ml/kg, mixed with warm blood in a venous reservoir, was infused together with cardioplegia during ischemia in Subgroup 2B. And 15 minutes more of *Injectio Radix Ginseng Compositae* with warm blood after crossclamp removal. Arterial blood pressure and leads 1, 2 and 3 of the electrocardiogram were monitored continuously.

The anterior wall biopsies from the left ventricle (a) before coronary occlusion or aortic crossclamp; (b) end of ischemia; and (c) 30 minutes after reperfusion were

analyzed as Kimose and associates described⁹. The latter 2 biopsies were taken from the ischemic region.

Data of myocardial ultrastructural changes were assessed qualitatively and semiquantitatively following the score system of Kimose and associates⁹. Differences between microscopic scores were determined by non-parametric analysis; $p < 0.05$ was considered of statistically significant.

Results

The myocardial mitochondrial ultrastructure (mitochondrial edema, cristae and matrix dissolution, mitochondrial membranous broken and amounts of myelin figures) of the ischemic region was better in ischemic than in reperfusion period in each subgroup. The ultrastructure changes were most severe in normothermic CPB, more severe in coronary ligation without and with the introduction of *Injectio Radix Ginseng Compositae*, and less severe in normothermic CPB with *Injectio Radix Ginseng Compositae*. Similar tendency appeared in damage to the sarcoplasm and capillary systems. No changes of nucleus were observed in each subgroup (Table I, Figures 1 and 2).

Discussion

Myofibrils are rather resistant to ischemic damage¹⁰. However, the presence of postischemic cellular and especially mitochondrial edema during reperfusion following cardiac arrest were found¹¹. Myocardial edema is probably of multifactorial changes in the permeability of capillaries, venules, and cellular membranes^{12,13}. Jennings and Ganote¹⁴, through studying regional ischemia in experimental infarction, postulated that the loss of cell volume regulation was the primary event causing injury during ischemia and reperfusion. Swelling of cells' and especially of the mitochondria, at the onset of the reperfusion are indicative of incomplete myocardial protection. Both mitochondrial injury and myocyte edema were less when perfusate temperature and pressure were slowly raised after 3¹/₂ hours ischemia (abrupt reperfusion with perfusate at 37°C and 70 mmHg) in Langendorff-perfused rat hearts⁶.

The ultrastructural changes after cardioplegia were

Table I
Semiquantitative assessment of myocardial ultrastructure^a

Subgroup	45 min after ischemia				30 min after reperfusion			
	1A	1B	2A	2B	1A	1B	2A ^b	2B ^c
I Mitochondria								
a) Damage rate (%)	35	35	50	15	35	35	70	25
b) Cristae broken	2	1	2	1	2	2	3	1
c) Matrix light	2	2	2	1	2	2	3	1
d) Membrane broken	1	1	2	1	2	1	2	1
e) Myelin figures	2	1	2	1	3	1	3	1
f) Calcium overloading	2	1	1	0	1	1	2	1
II Nuclear changes	0	0	0	0	0	0	0	0
III Sarcomere: Z band	1	1	1	0	1	1	1	0
IV Intercalated disk	1	1	1	0	2	1	1	1
V Sarcotubular system	3	2	2	1	3	1	1	1
VI Capillary edema	2	1	1	0	3	1	2	1

^a Score system. Data were presented as median.

Mitochondria: a) Damage rate: percentage of damaged mitochondria out of those of slides observed, b) Cristae 0 = very densely packed, 1 = a few disarranged and broken, 2 = disarrangement with up to half the cristae broken, 3 = sparse, widely spread and mostly broken. c) Matrix 0 = very dark, 1 = a few light areas, only a few spaces between the cristae, 3 = only a few disarranged cristae present, most of the matrix disappeared. d) Membranous broken 0 = no, 1 = local, 2 = spread. e) Myelin figures 0 = no, 1 = single, 2 = a few and cluster, 3 = multiple and cluster. f) Calcium overloading 0 = no, 1 = slight, 2 = moderate, 3 = severe.

Nuclear changes - Chromatin clumping, crenation of nuclear membrane, coarse nucleoli: 0 = absent, 1 = slight, 2 = moderate, 3 = severe.

Sarcomere - Z band 0 = present, normal, 1 = present, disarranged, thickened.

Intercalated disk - Structural dissolution and decreasing of electron density substances: 0 = normal, 1 = present, obscure, 2 = present, partly dissolution, 3 = mostly dissolution and even disappeared.

Sarcotubular system - Saccular dilation: 0 = normal, 1 = slight, 2 = moderate, 3 = severe.

Capillary edema - increased swelling of the capillary wall or narrowing of the vessels: 0 = absent, 1 = slight, 2 = moderate, 3 = severe.

^bSee Fig. 1, ^cFig. 2

dependent primarily on the extent of preexisting ischemic damage. After reperfusion, the majority of the patients had progressive changes of ischemia, with marked mitochondrial and sarcotubular swelling, depletion of glycogen, chromatin clumping, and myofibrillar disruption; amorphous mitochondrial densities were occasionally seen¹⁵. Chen *et al*⁴ suggested that from the viewpoint of ultrastructural morphometric study myocardial injury after an average

of 83 minutes of ischemic arrest is poorer in the right chambers of the heart than in the left ventricle, with the right atrium having the poorest.

In human hearts, intraoperative global ischemia alone produces qualitative mitochondrial changes. By reperfusion with blood, the mitochondria change qualitatively and quantitatively: the increased mitochondrial volume density is indicative of the




Fig. 1: Myocardial ultrastructure after 30 minutes' reperfusion in Subgroup 2A (x 9900).

- a) Mitochondria: Cristae broken -3;
Matrix light -3.
b) Sarcomere: Z band -1.

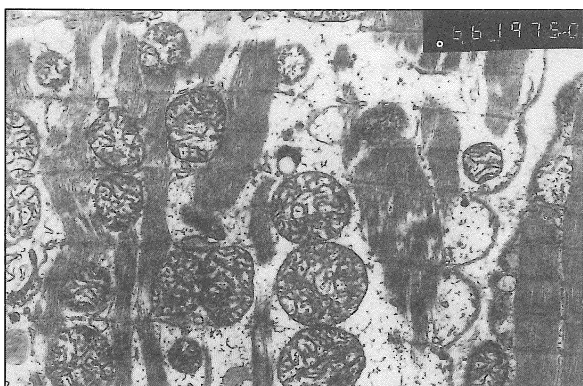

Fig. 2: Myocardial ultrastructure after 30 minutes' reperfusion in Subgroup 2B (x 9900).

- a) Mitochondria: Cristae broken -1;
Matrix light -1.
b) Sarcomere: Z band -0.

occurrence of swelling due to uptake of fluid and is the presence of a virtually unchanged surface density, of fusion of mitochondria to larger complexes^{10,11}. Schaper *et al*¹¹ found that per standard volume of cardiac cell, the mitochondria occupy a larger space during reperfusion than they did at control and at the end of ischemia.

Mitochondrial edema and matrix broken usually means disturbances in Krebs' cycle, amino acid decomposition, protein synthesis and lipoxidation. Cristae dissolution and intercrystal space narrowing and disappearance reveal dysfunction of respiratory chain enzymes. Mitochondrial membranous structure alterations would indicate an injury of oxidative phosphorylation. Amounts of myelin figures reflect the oxidative free radical damage. Otherwise, damages in sarcoplasmic and capillary systems reveal dysfunction of Na⁺-K⁺ pump and anion channels. Thus, ultrastructure changes was the most severe in normothermic CPB, more severe in coronary ligation without and with the introduction of *Injectio Radix Ginseng Compositae*, and less severe in normothermic CPB with *Injectio Radix Ginseng Compositae*.

Accordingly, *Injectio Radix Ginseng Compositae* was shown to have effects in antioxidants and improvement of coronary circulation.

In conclusion, reperfusion injury after ischemia is more severe in global model by normothermic CPB than in regional model by coronary ligation; *Injectio Radix Ginseng Compositae* has effectiveness in protection against myocardial reperfusion injury after ischemia; and *Injectio Radix Ginseng Compositae* might be considered as a component of cardioplegia during open heart surgery.

References

1. De Andrade RR, Tucci PJ, Silva MA, Oliverira RA, Gregorio EA, Curi PR, Hossne WS: Functional and ultrastructural evaluation of myocardial protection provided by intermittent coronary sinus perfusion in the isolated dog heart. *Braz J Med Biol Res* 1991;24 : 81-91.
2. Nishikawa Y, Yamamoto S, Ataka K, Nakamura K: The effect superoxide dismutase and catalase on myocardial reperfusion injury in the isolated rat heart. *Jpn J Surg* 1991;21 : 423-32.

ORIGINAL ARTICLE

3. Kimose HH, Ravkilde J, Knudsen MA, Helligsø P, Baandrup U: Recovery after cold cardioplegic arrest of isolated blood-perfused hearts excised from non-anesthetized pigs. *Eur Surg Res* 1990;22 : 323-35.
4. Chen YF, Lin YT, Wu SC: Inconsistent effectiveness of myocardial preservation among cardiac chambers during hypothermic cardioplegia. *J Thorac Cardiovasc Surg* 1991;102 : 684-7.
5. Ferreira R, Burgos M, Milei J, Llesuy S, Molteni L, Hourquebie H, Boveris A: Effect of supplementing cardioplegic solution with deferoxamine on reperfused human myocardium. *J Thorac Cardiovasc Surg* 1990;100 : 708-14.
6. Atkinson JB, Rybicka K, Huddleston CB, Starnes VA, Prager RL, Virmani R: The effect of verapamil cardioplegia on myocardial ultrastructure. *Am J Cardiovasc Pathol* 1988;2 : 69-77.
7. Krause SM, Jacobus WE, Becker LC: Alterations in cardiac sarcoplasmic reticulum calcium transport in the postischemic "stunned" myocardium. *Circ Res* 1989;65 : 526-30.
8. Yuan SM: Effects of myocardial preservation on enzyme levels in serum and myocardium: a clinical study comparing cold crystalloid versus warm blood cardioplegia. *Chin Med J (Taipei)* 1997;59 : 21-7.
9. Kimose HH, Ravkilde J, Helligsø P, Knudsen M, Baandrup U: Influence of post-existing ischemia on recovery from chemical cardioplegia: a study on pig hearts in an isolated blood-perfused model. *Scand J Thorac Cardiovasc Surg* 1992;26 : 23-31.
10. Forman MB, Puett DW, Virmani R: Endothelial and myocardial injury during ischemic and reperfusion: pathogenesis and therapeutic implications. *J Am Coll Cardiol* 1989;13 : 450-9.
11. Lindal S, Gunnes S, Lund I, Straume BK, Jorgensen L, Sorlie D: Ultrastructural changes in rat hearts following cold cardioplegic ischemia of differing duration and differing modes of reperfusion. *Scand J Thorac Cardiovasc Surg* 1990;24 : 213-22.
12. Schaper J, Hehrlein F, Schlepper M, Thiedemann KU: Ultrastructural alterations during ischemia and reperfusion in human hearts during cardiac surgery. *J Mol Cell Cardiol* 1977;9 : 175-89.
13. Schaper J, Schwarz F, Kittstein H, Stämmler G, Winkler B, Scheld H, Hehrlein F: The effects of global ischemia and reperfusion on human myocardium: quantitative evaluation by electron microscopic morphometry. *Ann Thorac Surg* 1982;33 : 116-22.
14. Jennings RB, Ganote CE: Mitochondrial structure and functions in acute myocardial ischemic injury. *Circ Res* 1976;38 (5 Suppl 1) : I 80-I 91.
15. Yates JC, Dhalla NS: Structural and functional changes associated with failure and recovery of hearts after perfusion with Ca⁺⁺ - free medium. *J Mol Cell Cardiol* 1975;7 : 91-103.