

# Non-Familial Haemophagocytic Lymphohistiocytosis in Children

MC Hoh, MRCP, HP Lin, FRCP, Department of Paediatrics, University Hospital, 59100 Kuala Lumpur

## Summary

Haemophagocytic Lymphohistiocytosis (HLH) is a rare clinical illness with a high mortality. There are reported effective treatment and a favourable outcome if diagnosed early. Five cases of childhood non-familial HLH seen over a 3 year period in our hospital are presented. The diagnosis was not suspected in the referring hospitals even after a bone marrow biopsy examination in two cases. Delay in referral was between 2 weeks to 2 months. A viral trigger was detected in only two cases. There were two deaths. Cause of death in both cases were *cytomegalovirus* pneumonitis and disseminated intravascular coagulopathy. Respond to treatment was better if started earlier. One case spontaneously resolved. Earlier diagnosis will lead to prompt treatment and a better outcome.

**Key Words:** Haemophagocytic lymphohistiocytosis, Histiocytosis syndromes  
Virus-associated haemophagocytic syndrome, Etoposide (VP16)

## Introduction

Haemophagocytic lymphohistiocytosis (HLH) is a rare clinical syndrome characterised by recurrent fever, hepatosplenomegaly, cytopenia, hypertriglycaemia and evidence of haemophagocytosis in the bone marrow, liver, spleen, lymph nodes and/or central nervous system<sup>1</sup>. Its pathogenesis is still unknown but there is some evidence it is related to uncontrolled T-cell mediated tissue-macrophage activation resulting in abnormal overproduction of inflammatory cytokines and prostaglandins<sup>2,3</sup>.

The term 'HLH' was derived from the Writing Group of the Histiocyte Society in 1987<sup>1</sup>. It is classified under Class II of the Histiocytosis syndromes (Table II). Histiocytes or 'tissue cells' in Greek, are formed in the bone marrow and differentiate either into mononuclear phagocytes which are antigen-processing histiocytes with phagocytosis as their main function, or into 'professional' antigen-presenting histiocytes which are non-phagocytic. When they accumulate and/or proliferate abnormally in a tissue and causes a

pathological process, the disorder is called a histiocytosis. HLH is regarded as a 'reactive' disorder of antigen-processing histiocytes while Langerhans cell histiocytosis (LCH) (Class I) which is the other commonly presenting childhood histiocytosis disorder is regarded as a 'reactive' disorder of antigen-presenting histiocytes<sup>4</sup>.

HLH comprises of two forms; familial and non-familial. The familial form first described in 1952 by Farquhar and Claireaux<sup>5</sup> as Familial erythrophagocytic lymphohistiocytosis (FEL) occurs commonly in infancy, is prone to relapses and eventually fatal if untreated. The non-familial form, described by Risdall *et al* in 1979<sup>6</sup> as Virus-associated haemophagocytic syndrome (VAHS), occurs mainly in immunocompromised children and adults. Both forms of the disease are clinically, pathologically and biochemically indistinguishable. The only distinguishing feature between the two forms may be a history of consanguinity or family history of similar illness in the familial type. The non-familial form usually has a viral or infective trigger. Although it was thought to be a

benign illness by Risdall, recent studies from the United Kingdom and Taiwan have reported mortality rates ranging from 53%<sup>7</sup> to 67%<sup>8</sup> even with aggressive cytotoxic treatment. In the familial form of HLH allogenic bone marrow transplantation has been advocated<sup>8</sup>. In Taiwan, *Epstein-Barr* and *Human Herpes virus-6* associated HLH is uniformly fatal if supportive treatment is given only<sup>9,10</sup>.

## Patients

### Case 1

A 4-year old Malay boy was referred with a 2 weeks history of fever, lethargy and petechiae over his right arm. A maculopapular rash appeared over his limbs during the initial phase of the illness. He was febrile with a temperature of 40.5°C. There was generalised lymphadenopathy and gross hepatosplenomegaly. His blood results are documented in Table 1. Bone marrow and trephine biopsy showed a marked increase in mononuclear cells and histiocytes with haemophagocytosis (Fig 1). Bacterial and viral cultures of blood, cerebrospinal fluid, stool, urine and oral secretions were negative. The Weil-Felix and Widal test including serology for hepatitis, *brucella*, *toxoplasmosis*, *parvovirus* and *cytomegalovirus* (CMV) were all negative. Despite continuous broad spectrum antibiotics, he continued to deteriorate with signs of disseminated intravascular coagulopathy (DIVC) and gross abdominal ascites. HLH was finally suspected and etoposide at 150mg/m<sup>2</sup> daily was started but he died on the second day of treatment, 45 days since admission. Post mortem was refused. Subsequent nasopharyngeal secretions was positive for *Cytomegalovirus*.

### Case 2

A 5-year-old Chinese girl was transferred to our hospital with a 2-month history of recurrent fever and hepatosplenomegaly preceded initially by a short bout of gastroenteritis. The pyrexia was unresponsive to antibiotics and she was extensively investigated with a full bacterial and virological screen including a collagen vascular screen, skeletal survey, bone marrow examination and a cervical lymph node biopsy in the referring hospital. Blood results are as in Table I. A repeat bone marrow aspirate examination showed a

marked increase in the number of histiocytes with haemophagocytic activity. She continued to be pyrexial despite receiving various combinations of antibiotics. The fever finally responded to an amphotericin B infusion but returned when it was stopped after 4 days. On restarting it, the fever again subsided. She eventually received 21 days of amphotericin B. We were unable to isolate any fungus from her blood, urine or cerebrospinal fluid. On the 36th day after admission her full blood count returned to normal with a Hb of 12.3 g/dl, white cell count 11.2 x 10<sup>9</sup>/l and platelets 264 x 10<sup>9</sup>/l. A repeat bone marrow aspirate examination showed normal cellularity. She remains well 2 years from the illness except that a year ago when she was diagnosed with systemic juvenile chronic arthritis.

### Case 3

A 20-month-old Chinese boy was referred with a one-month history of abdominal distension and recurrent fever. Ultrasound of his abdomen showed gross hepatosplenomegaly. Bacterial cultures and serological tests for infectious organisms were negative. A bone marrow biopsy was reported to be normal at the referring hospital. He did not respond to antibiotics and the fever was as high as 40.0°C. Blood investigations are as in Table I. Further bacteriological and virological screening showed a positive IgM reaction to *cytomegalovirus* only. Repeat bone marrow biopsy in our hospital showed an abundance of histiocytes and marked haemophagocytosis. The fever responded to amphotericin B infusion but returned on

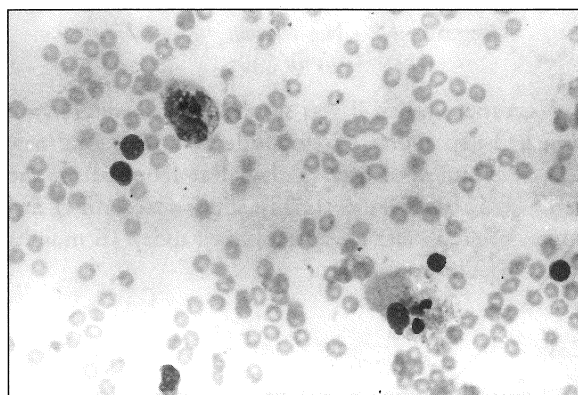


Fig. 1: Active Haemaphagoaytesis in bone marrow aspirate

**Table I**  
**Patients clinical features, laboratory data on admission and outcome**

Age Sex	Patient no.				
	1 4 years Male	2 5 years Female	3 20 months Male	4 2 years Female	5 2 years Female
Fever	Yes	Yes	Yes	Yes	Yes
Splenomegaly	Yes	Yes	Yes	Yes	Yes
Hepatomegaly	Yes	Yes	Yes	Yes	Yes
Lymphadenopathy	Yes	No	No	Yes	No
Neurological deficits	No	No	No	No	No
Bleeding tendency	Yes	No	No	No	No
Haemoglobin (g/d <sup>9</sup> )	7.7	9.2	7.6	8.1	5.7
Neutrophils (X10 <sup>9</sup> /L)	0.35	0.21	1.3	0.35	0.14
Platelets (x10 <sup>9</sup> /L)	31	271	59	61	16
Triglycerides (mmol/L)	ND	5.1	3.8	5.2	2.2
AST (iu/L)	N	N	N	500	142
CSF findings	N	N	N	N	ND
DIVC screen	Pos	Neg	Neg	Pos	Neg
Bone marrow findings	Pos	Pos	Pos	Pos	Pos
Viral trigger	No	No	Yes (CMV)	Yes (HHV6)	No
Etoposide	Yes	No	Yes	Yes	No
Methylprednisolone	Yes	No	Yes	Yes	No
Outcome	Died	Alive	Alive	Died	Alive
Follow-up period	NR	2 years	16 months	NR	1 year

AST - Aspartate amino-transferase, CSF - Cerebrospinal fluid  
 DIVC - Disseminated intravascular coagulation, CMV - Cytomegalovirus,  
 HHV6 - Human herpes virus 6, ND - Not done, N - Normal, Pos - Positive,  
 Neg - Negative, NR - Not relevant

two occasions when it was stopped. We therefore gave him a 3-day course of etoposide at 150 mg/m<sup>2</sup>/day. The fever subsided after 2 days but returned on the third day. It subsided finally after a second 3-day course of etoposide. He remains well today 16 months since the illness.

#### Case 4

A 2-year-old Chinese girl was referred with a one-month history of recurrent fever following a booster injection of the diphtheria, tetanus and polio vaccine.

Blood results are as in Table I. There was generalised lymphadenopathy and gross hepatosplenomegaly. Her fever was remittent with a peak of 40°C. Her cardiac enzymes were raised with AST 500iu/l and HBDH 950 iu/l. Urate level was also raised at 1067 umol/l. Electrocardiogram and chest radiograph showed no arrhythmias or cardiomegaly. A full bacteriological and virological screen done earlier on in her illness was negative. She was unresponsive to antibiotics and amphotericin B. Bone marrow aspirate examination findings were typical of HLH with increased histiocytes and haemophagocytosis. 2 weeks after admission she

went into disseminated intravascular coagulopathy with diffuse pulmonary infiltrates and cardiomegaly on echocardiography. She was started on etoposide and methylprednisolone but only received 2 days therapy. On the third day she suddenly deteriorated with hypotension, ventricular arrhythmias and died. Post mortem was refused. Subsequent cultures of the nasopharyngeal secretions was positive for *cytomegalovirus* and her bone marrow aspirate tested positive for the *Human herpes virus-6*.

**Table II**  
**Histiocytosis syndromes working classification**

Class I	Langerhans cell histiocytosis (LCH)
Class II	Haemophagocytic lymphohistiocytosis (HLH) – Genetic – Sporadic
Class III	Malignant disorders of histiocytes – Acute monocytic leukaemia (FAB M5) – Malignant histiocytosis
Class IV	Other histiocytosis syndromes – sinus histiocytosis with massive lymphadenopathy – Xanthogranuloma – Reticulohistiocytoma

Writing Group of the Histiocyte Society classification 1987.

### Case 5

A 2-year-old Chinese girl was referred with a 6-week history of recurrent fever, cough, progressive pallor and lethargy. She also had generalised lymphadenopathy and gross hepatosplenomegaly. Blood results are as in Table I. Bone marrow biopsy showed prominent histiocytes with foamy cytoplasm and haemophagocytosis. Bacteriological and virological cultures were negative. After 7 days of antibiotics here, her fever settled. She continued to improve and on review 4 weeks after admission her Hb was 10.9 g/dl, white cell count  $8.1 \times 10^9/l$  and platelet count  $379 \times 10^9/l$ . Her lymphadenopathy and hepatosplenomegaly subsided completely. She remains well today 10 months since her illness started.

### Discussion

HLH is a potentially treatable illness if diagnosed early. Proven therapeutic agents include etoposide, cyclosporin, prednisolone and immunoglobulins<sup>7</sup>. Allogenic bone marrow transplantation has also been shown to be effective<sup>8</sup>. In our series of patients the duration of illness prior to referral ranged from 2 weeks to 2 months. Most had extensive investigations prior to referral including a bone marrow biopsy in two cases. Referring centres were government or private hospitals. In the 2 fatal cases, cytotoxic therapy was commenced late in the illness. Supportive therapy alone did not work except in case 5 where we suspect the recovery was due to spontaneous resolution rather than antibiotic therapy. In case 2, we suspected the

**Table III**  
**Diagnostic criteria of the FHL Study Group<sup>9</sup>**

1. Fever	– duration > 7 days with peaks > 38.5°C
2. Splenomegaly	
3. Cytopenia	– Affecting at least two of three lineages in the peripheral blood:- i) Hb < 9.0 g/dl ii) Neutrophils < $1.0 \times 10^9/l$ iii) Platelets < $100 \times 10^9/l$
4. Hypertriglyceridaemia	– Serum triglyceride > 2.0 mmol/l
5. Histopathological	– Haemophagocytosis in bone marrow and/or lymph nodes without evidence of malignancy

hydrocortisone routinely added to amphotericin to prevent allergic reactions, was the therapeutic agent rather than amphotericin B itself. Etoposide and methylprednisolone was effective in treating case 3 but only after 2 courses. The causes of death in cases 1 and 4 were due to CMV pneumonitis and severe DIVC respectively.

The clinical features of our patients conforms to the five diagnostic criteria for HLH laid down by the FHL Study Group of the Histiocytic Society<sup>11</sup> (Table III). None of our patients however had neurological signs of convulsions, cranial nerve palsies or cerebellar dysfunction described by Henter and Elinder<sup>12</sup>. Cerebrospinal fluid obtained in all patients except number 5 was normal. Bleeding symptoms at presentation were present in only one patient. There was no sex preference and almost all our patients had a high remittent fever with gross hepatosplenomegaly. Laboratory data showed almost all the cases had pancytopenia (Table 1). AST was raised in only two patients. Hyperbilirubinaemia or hyponatraemia was not present in our cases. A viral trigger was identified in cases 3 and 4 only.

The only reported incidence of HLH is from Sweden which suggests one or two cases per million per year<sup>13</sup>. In Malaysia we may therefore expect to see 18 to 36 new cases per year. The symptoms of recurrent pyrexia, hepatosplenomegaly and pancytopenia could easily be mistaken for severe sepsis of unknown origin (PUO), a malignancy or a collagen vascular disease. Subsequent extensive investigations delays treatment and the indiscriminate use of multiple antibiotics usually leads to overwhelming superinfection with viral or fungal infections. The clinical picture is further complicated by the increasingly severe neutropenia and T-cell dysfunction which itself encourages severe bacterial and viral infections.

Diagnosis requires a high degree of suspicion. In cases 2 and 3 the bone marrow was reported normal by the referring hospital's pathologist. Our patients were referred mainly because of a suspicion of a malignancy or for further investigation of a PUO. Although this condition is rare, it has a high mortality rate and is potentially treatable. It is hoped that this illness will be better recognised so that earlier treatment can be initiated.

## References

1. The Writing Group of the Histiocyte Society. Histiocytosis syndromes in children. *Lancet* 1987;i : 208-9.
2. Oyama Y, Amano T, Hirakawa S *et al*. Haemophagocytic syndrome treated with cyclosporin A: a T-cell disorder. *British Journal of Haematology* 1989;73 : 276-8.
3. Watson HG, Goulden NJ, Manson LM, McDermid G, Gray JA, Parker AC *et al*. Virus-associated haemophagocytic syndrome: further evidence for a T-cell mediated disorder. *British Journal of Haematology* 1994;86 : 213-5.
4. Pritchard J, Broadbent V. Histiocytosis - An introduction. *Br.J.Cancer* 1994;70 (Suppl.XXIII) : S1-S3.
5. Farquhar JW, Claireaux AF. Familial haemophagocytic reticulosis. *Arch Dis Child* 1952;27 : 519-25.
6. Risdall RJ, McKenna RW, Nesbit ME *et al*. Virus-associated haemophagocytic syndrome. *Cancer* 1979;44 : 993-1002.
7. Chen RL, Lin KH, Lin DT *et al*. Immunomodulation treatment for childhood virus-associated haemophagocytic lymphohistiocytosis. *British Journal of Haematology* 1995;89 : 282-90.
8. Hirst WJR, Layton DM, Singh S *et al*. Haemophagocytic lymphohistiocytosis: experience at two U.K. centres. *British Journal of Haematology* 1994;88 : 731-9.
9. Huang LM, Lee CY, Lin KH *et al*. Human herpes virus-6 associated with fatal haemophagocytic syndrome. *Lancet* 1990;336 : 60-1.
10. Su IJ, Hsieh HC, Lee CY. Histiocytic medullary reticulosis: a lethal form of primary EBV infection in young children in Taiwan. *Lancet* 1989;i : 389.
11. Henter JI, Elinder G, Ost A. and FHL Study Group of the Histiocyte Society. Diagnostic guidelines for haemophagocytic lymphohistiocytosis. *Seminars in Oncology* 1991;18 : 29-33.
12. Henter JI, Elinder G. Cerebrospinal haemophagocytic lymphohistiocytosis. *Lancet* 1992;339 : 104-7.
13. Henter JI, Elinder G, Soder O, Ost A. Incidence in Sweden and clinical features of familial haemophagocytic lymphohistiocytosis. *Acta Paediatr Scand* 1991;80 : 428-35.