

manifestation of local disease. It is categorised as stage IIE (nodal disease with direct extension to an adjacent extralymphatic site) if it is confined above the diaphragm. The extensive lung involvement and hepatosplenomegaly in this patient means that he was having stage IV disease.

Lung involvement by Hodgkin's disease responds well to chemotherapy and of patients given chemotherapy, those with lung involvement fare as well as those without². If the diagnosis of a lymphoma had been made preoperatively in this patient, he would not have needed a pneumonectomy.

References

1. Strauchen JA, Kleinerman JI. The Lungs in Malignant Haematological Disease. In: Fishman AP, ed. Pulmonary Diseases and Disorders, 2nd ed. New York, McGraw-Hill, 1988 : 2045-66.
2. MacDonald JB. Lung involvement in Hodgkin's disease. Thorax 1977;32 : 664-7.
3. Flint A, Smid DM. Pulmonary Hodgkin's disease and Langerhans' cell granulomatosis. Chest 1987;92 : 191-2.

Primary Non-Hodgkin's Lymphoma of the Cranial Vault Mimicking a Meningioma : A Case Report

I A Muin, MS*, H M Saffari**, Y N Hasimah, MPath***, *Department of Surgery, Division of Neurosurgery, Medical Faculty, Universiti Kebangsaan Malaysia, Kuala Lumpur, **Department of Neurosurgery, ***Department of Pathology, Hospital Kuala Lumpur

Summary

Primary non-Hodgkin's lymphoma of the brain is rare. Majority of the lesions are intraaxial, multicentric and involve the leptomeninges. We report a case of malignant primary non-Hodgkin's lymphoma arising from the cranial vault. Computed tomography of the brain showed an extraaxial lesion in the right parietal region mimicking a meningioma.

Key Words: Primary, Non-Hodgkin's lymphoma, Cranial vault, Meningioma

Introduction

Primary cerebral non-Hodgkin's lymphoma of the brain is rare. The incidence however has increased 10-fold during 1973-1990¹. Majority of the lesions are

intraaxial³. Though rare, malignant primary non-Hodgkin's lymphoma arising from the cranial vault has been reported². We reviewed the literature and found only five reports of primary non-Hodgkin's lymphoma arising from the cranial vault.

Case Report

A 60-year-old man presented with 3 months history of headache, increasing confusion, forgetfulness and left sided hemiparesis. The right fundus showed papilloedema. The left fundus was normal. There was left sided hemiparesis with motor power of grade 4/5 in both the upper and lower limbs. Examination of other systems were normal. Computed tomography of the brain showed an inhomogenous extraaxial mass which enhanced with contrast injection in the right parietal region. There was also moderate oedema with compression of the ipsilateral ventricle (Fig. 1).

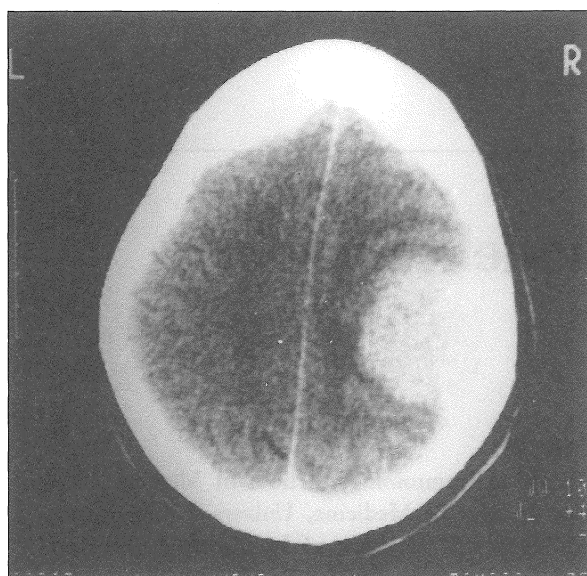


Fig. 1: Computed tomography scan showing an enhanced extraaxial lesion in the right parietal region

At surgery the tumour was noted to be greyish, firm and clearly demarcated from the normal brain tissue. The tumour was attached to the dura. The parietal bone was thickened and infiltrated by the tumour. The intra-operative findings were in keeping with that of a meningioma. A total macroscopic removal of the tumour was achieved. The infiltrated dura was excised. The tumour from under surface of the bone was curetted and the bone flap replaced. He developed weakness of the left upper limb (power grade 3/5) on the third post-operative day. Computed tomography of the brain revealed a small extradural blood collection

with gross cerebral oedema. He responded well to steroid therapy. Histological examination of the tumour reported a high grade non-Hodgkin B-cell lymphoma. A search for peripheral, abdominal and mediastinal lymphadenopathy proved to be negative.

As the tumour originated from the parietal bone, the bone flap was subsequently removed. He was also given post-operative external beam radiotherapy and adjuvant chemotherapy comprising of cylophosphamide, adriamycin, oncovin and prednisolone. A repeat CT brain after 8 months showed no tumour recurrence.

Discussion

Primary lymphoma of the brain is rare and accounted for only 1.2% of all non-Hodgkin's lymphoma cases¹. In recent years however, the incidence of cerebral lymphoma amongst immunocompromised patient is on the rise. The tumours are mostly intraaxial, multicentric and frequently invade the leptomeninges³. Non-Hodgkin's lymphoma involving the cranial vault is extremely rare. To our knowledge only five such cases has been reported in the literature. As evident by our case the radiological differentiation between a meningioma and a non-Hodgkin's lymphoma arising from the cranial vault is difficult.

The non-Hodgkin's lymphoma was assumed to arise from the cranial vault as the tumour was extraaxial in location and involved the parietal bone. Infiltration of the dura matter is common. The lesion is also known to involve both sides of the cranial vault, the pericranium and the subcutaneous tissue².

As the lesion is potentially treatable by surgery, post-operative radiotherapy and chemotherapy, the clinicians should always maintain a high index of clinical suspicion when dealing with suspicious cases of meningioma. Minimal cortical destruction should alert the clinicians to suspect a malignant lymphoma as the tumour frequently show a permeative growth pattern with a soft tissue component. An intra-operative histological diagnosis should be requested so that optimum surgical treatment can be achieved. Removal of the involved skull bone is mandatory to prevent tumour recurrence.

Acknowledgement

The authors would like to thank Mr. Kamaruzaman of the Medical Education Department, Universiti Kebangsaan Malaysia for the photography.

References

1. Lutz JM, Coleman MP. Trends in primary cerebral lymphoma. *Br J Cancer* 1994;70 : 716-8.
2. Parekh HC, Sharma RR, Keogh AK, *et al.* Primary Malignant non-Hodgkin's Lymphoma of Cranial Vault: A Case Report. *Surg Neurol* 1993;39 : 286-9.
3. Parekh HC, Sharma RR, Lynch PG, *et al.* Primary cerebral lymphoma: report of 24 patients and review of the literature. *Br J Neurosurg* 1992;6 : 563-73.

Severe Combined Immunodeficiency in a Malaysian Child

L M Noh, FRCPE*, H L Amir, MBBS**, Hung LC, MRCP***, Zulkifli I, MMed Paeds**, B A Nasuruddin MD****, *Dept of Immunology, School of Medicine, Universiti Sains Malaysia, Kelantan, **Dept of Paediatrics, Faculty of Medicine, Universiti Kebangsaan Malaysia, Kuala Lumpur, ***Dept of Paediatrics, Hospital Ipoh, ****Division of Immunology, Institute for Medical Research, Kuala Lumpur

Summary

A 3-month-old Malay male infant presented with multiple infections (candidiasis, *Pseudomonas aeruginosa*, Cytomegalovirus), persistent pneumonia, intractable diarrhoea and failure to thrive. There was lymphopaenia affecting both T and B subsets. He developed Graft versus Host disease weeks following transfusion with non irradiated blood. In spite of aggressive microbicidal and supportive therapy including regular immunoglobulin infusions, the child succumbed to infection before a bone marrow transplant could be instituted.

Key Words: Severe combined immunodeficiency, Recurrent infections, Graft versus host disease

Introduction

Severe combined immunodeficiency (SCID) is probably the rarest of the known entities of the primary

immunodeficiencies, with an estimated prevalence of 1 per 50 – 100,000 live births. They can present early in life but classically in the first 3 months with chronic infectious diarrhoea and failure to thrive. Abnormal