

Ileocolic Neobladder Reconstruction Following Cystectomy for Carcinoma of Bladder

M M Abdullah, FRCS*, K Noordin, FRCS*, C C M Lei, FRCS**, A Khairullah, FRCS**,

*Division of Urology, Department of Surgery, Universiti Kebangsaan Malaysia, Kuala Lumpur,

**Department of Urology, Hospital Kuala Lumpur, 50586 Kuala Lumpur

Summary

Six patients who had ileocolic neobladder reconstructed following cystectomy for carcinoma of bladder were studied. All were male patients ranging in age from 38 to 78 years. There was no operative mortality. One patient developed deep wound infection postoperatively. Two patients developed long term complications; one had spontaneous perforation and the other developed bladder stone. Functionally, all patients were continent and only one had nocturnal enuresis. Initially one patient could not void spontaneously and required intermittent self-catheterisation. The volume of the neobladder ranged from 250 to 714 ml. and filling cystometry showed a compliant system. In conclusion, we found the results of neobladder reconstruction to be encouraging.

Key Words: Cystectomy, Carcinoma of bladder, Neobladder

Introduction

The options available for urinary tract reconstruction following cystectomy are incontinent diversion, continent diversion and orthotopic bladder replacement (or neobladder). Orthotopic bladder replacement was first performed by Camey and LeDuc¹ in 1979. Even though it seems to be the most desirable form of urinary tract reconstruction, its acceptance was slow because of difficulty in performing the procedure. As more and more urologists became well versed with the procedure, many different methods of pouch reconstruction have been devised in an attempt to achieve the goal of a neobladder that functions as well as a normal bladder. One of this was the Mainz pouch ileocolic neobladder².

We performed neobladder reconstruction using the Mainz pouch technique on 6 patients following radical cystectomy for carcinoma of bladder since February 1993. To evaluate the results of the procedure, these patients were studied clinically, radiologically and urodynamically. The results of this study are presented.

Materials and Methods

The study population consisted of 6 male patients who had undergone radical cystectomy for bladder carcinoma with creation of a Mainz pouch ileocolic neobladder. Mean patient age at operation was 59.5 years (range 38 to 78). During cystectomy, care was taken to preserve the neurovascular bundle, the pelvic diaphragm and a well-defined urethral stump. The caecum and ascending colon were then mobilised. After ascertaining that the dependent part of the caecum was able to reach the urethral stump, a 45 cm segment of bowel (consisting of 15 cm of colon and 30 cm of ileum) was isolated. Continuity of the intestinal track was reestablished using a standard ileocolic anastomosis. Appendicectomy was then performed. After adequate irrigation with normal saline, the isolated ileocolic segment was placed in an S configuration (Fig. 1) and detubularised. A broad plate of bowel was created by suturing the apposing margins of the 3 limbs of the S with a running 3-0 absorbable suture. A button-hole resection was made at the most dependent portion of the caecum and

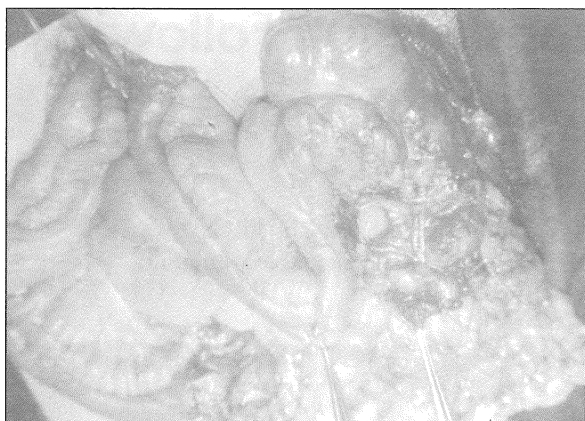

Fig. 1: The isolated ileocolic segment being placed in an "S" configuration

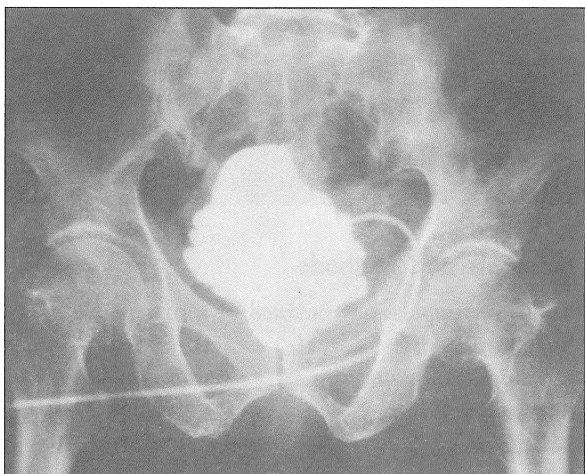


Fig. 2: Cystogram done 2 weeks postoperatively showing intact neobladder

cecourethral anastomosis was made with 4 interrupted 4-0 absorbable sutures over an 18F Silastic Foley's urethral catheter. The left ureter was brought under the sigmoid mesocolon and both ureters were reimplemented over stents in the colonic portion of the neobladder by the Le Duc's technique. A 24F Foley's catheter was placed in the neobladder as a suprapubic catheter. The neobladder was closed with running 3-0 absorbable sutures.

Postoperatively the patient usually stayed in hospital for 2 weeks and discharged after the ureteral stents

had been removed. He returned home with urethral and suprapubic catheters in place. After a further 2 weeks the patient was readmitted. A cystogram (Fig. 2) was performed and the urethral catheter removed and suprapubic catheter clamped if there was no leakage of urine. The patient was instructed to void by Valsalva manoeuvre. If it was not successful he was taught clean intermittent self catheterisation. The suprapubic catheter was then removed. Voiding charting, uroflowmetry and assessment of residual urine were done and the patient discharged. Cystometrograms and intravenous urogram were performed at 2 to 3 months postoperatively.

Results

Postoperative complications. One patient developed deep wound infection that required secondary suturing. Another patient had delayed healing of the urethrocaecal anastomosis that healed after a further 4 weeks of urethral catheterisation. Two patients developed long-term complications – one had spontaneous bladder perforation 4 months postoperatively and another bladder stone 1 year postoperatively.

Continence status. All patients were continent during the daytime. One patient had nocturnal enuresis and the residual urine in this patient was found to be 175 ml. He was instructed to self catheterise before retiring and with this manoeuvre he became dry at night.

Voiding. Five patients were able to void adequately with average voided volume of 245 ml (range 161 to 277). The mean maximum flow rate was 8.7 ml/sec (range 4.4 to 11.0). The flow pattern (Fig. 3) showed the characteristic emptying by abdominal straining. The patients who were continent both day and night had residual urine of less than 100 ml. The patient with night time incontinence had a residual urine of 175 ml as mentioned earlier. One patient was not able to void initially and was put on clean intermittent self catheterisation. Subsequently cystoscopy showed hyperplastic mucosa to be the cause of inability to void and transurethral resection was done following which the patient was able to void successfully.

Cystometrograms. The average neobladder capacity was 594 ml (range 250 to 714). The neobladders appeared

to be compliant reservoirs as demonstrated by the low basal pressures of less than 20 cm H₂O during filling cystometrogram (Fig. 4). Two patients had phasic neobladder contractions, the number and intensity of which increased at higher neobladder volumes. The mean pressure was 52 cm H₂O in one patient and 30 cm H₂O in the other patient. However, it did not lead to incontinence in the patients.

Potency. Four patients were potent preoperatively. Out of these 4 patients, only 1 patient retained potency postoperatively giving a potency rate of 25%.

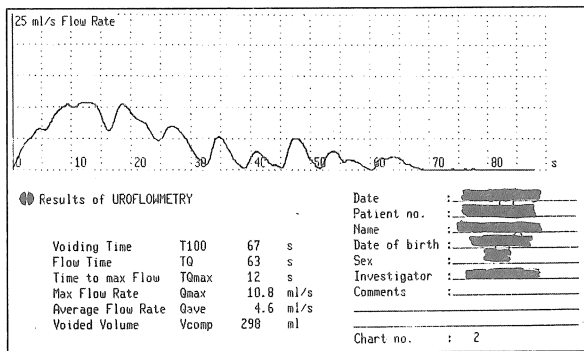


Fig. 3: Tracing of uroflowmetry showing characteristic emptying by abdominal straining

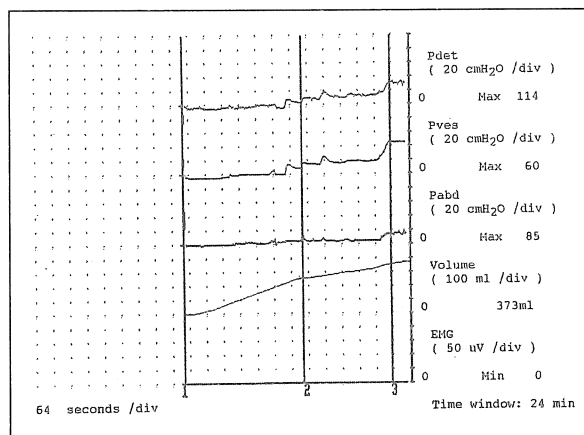


Fig. 4: Filling cystometrogram of one of the patients showing a compliant neobladder

Discussion

Traditionally, patients had to contend with an abdominal urinary stoma constructed in conjunction with an ileal conduit following cystectomy for carcinoma of bladder. The advent of orthotopic bladder replacement (neobladder) was a milestone as the patient became continent, had a normal body image and was able to void through the normal passage by Valsalva manoeuvre. Hence, neobladder reconstruction would be a desirable option in selected patients after cystectomy for carcinoma of bladder.

Continence is very much dependent on the preservation of the external sphincter apparatus during cystectomy. This can be achieved by making sure that Santorini's plexus is accurately and effectively controlled to allow excellent visualisation during skeletonising of the urethra³. Also preservation of the autonomic nerve supply to the corpora cavernosa may enhance innervation to the membranous urethra and improve urinary continence⁴. Besides improving continence rate, it also offers the possibility of retaining potency as shown in 1 out of 4 of our patients that were potent preoperatively.

A neobladder must be compliant during filling in order to protect the upper urinary tracts from pressure-induced damages. Our study showed that ileocolic neobladders have excellent compliance at functional bladder capacities with basal pressure less than 20 cm H₂O. Similarly, Marshall⁵ demonstrated a mean pressure of 17 cm H₂O during filling in 25 ileocolic neobladders. Detubularisation of the bowel segment used to form the reservoir appears to be a critical aspect of making it very compliant⁶. This can be appreciated by comparing the compliance of the detubularised ileocolic neobladder and urethral Kock pouch⁷ to that of the nondetubularised original Camey neobladder. Roehrborn *et al*⁸ studied 14 Camey neobladders and found the basal pressure at 200 ml to be 26 cm H₂O and the basal pressure at 300 ml to be 37 cm H₂O.

A neobladder must also be stable during storage of urine. Unstable contractions can lead to incontinence and to pressure-induced damage to the upper tracts especially in patients with high leak pressure. It has

been shown that detubularised bowel reservoirs have unstable contractions during filling phase of cystometrograms^{7,8,9}. However, the mean pressure of these contractions were not high enough to lead to upper tract deterioration. As was the case with compliance, detubularisation appears to be critical to decrease phasic contraction pressures. Detubularisation interrupts the circular fibres of the bowel wall to decrease contraction pressures. Roehrborn *et al*⁶ found in the Camey neobladder a "maximum intraluminal pressure" (which appears to be the pressure of maximal contraction) of 77 cm H₂O in their 14 patients.

Neobladder reconstruction is only suitable for patients whose bladder cancer have not spread to involved extravesical tissue and who are reasonably fit as it is a

major and long operation. There must also have manual dexterity in case spontaneous micturition is not possible and self catheterisation has to be performed. Old, frail patients with poor dexterity and those who have undergone radiotherapy are not suitable candidates.

In conclusion, we believe that ileocolic neobladder reconstruction is a legitimate and best option for selected patients following cystectomy. In terms of continence, our results showed that ileocolic neobladder is indeed excellent. It is also a compliant system of good capacity that will offer protection to the upper tracks. There is also possibility of retaining potency with careful preservation of the corporal neurovascular bundle.

References

1. Camey M, and LeDuc A. L' entrocystoplastie avec cystoprostatectomie totale pour cancer de la vessie. *Ann Urol* 1979; 13 : 114-7.
2. Thuroff JW, Alken P, Riedmiller H, *et al*. The MAINZ (mixed augmentation ileum 'n zecum) for bladder augmentation and continent diversion. *World J Urol* 1985;3 : 179-83.
3. Reiner WG and Walsh PC. An anatomical approach to the surgical management of the dorsal vein and Santorini's plexus during radical retropubic surgery. *J Urol* 1979;121 : 198-206.
4. Walsh PC. Radical retropubic prostatectomy. In: Campbell's Urology, 5th Ed. Edited by PC Walsh, RF Gittes, AD Perlmutter, and TA Stamey. Philadelphia: WB Saunders Co, Vol 3 Chap 76, 1986 : 2769-71.
5. Marshall, FF. Ileocolic Neobladder After Cystectomy. *Urol Clin North Am* 1991;18 : 631-9.
6. Hinman F, Jr. Selection of intestinal segments for bladder substitution: physical and physiological characteristics. *J Urol* 1988;139 : 519-23.
7. Kock NG, Ghoneim MA, Lycke KG, *et al*. Replacement of the bladder by the urethral Kock pouch: functional results, urodynamics and radiological features. *J Urol* 1989;141 : 1111-4.
8. Roehrborn CG, Teigland CM and Sagalowsky AI. Functional characteristics of the Camey ileal bladder. *J Urol* 1987; 138 : 739-44.
9. Miller K, Wenderoth UK, de Petriconi R, *et al*. The ileal neobladder: operative technique and results. *Urol Clin N Am* 1991;18 : 623-9.