

Epidural Anaesthesia for Caesarean Section in an Achondroplastic Dwarf : An Unusually High Dose of Local Anaesthetic

L L L Oh, B S Lee, Department of Anaesthesiology, Faculty of Medicine, University of Malaya, 59100 Kuala Lumpur

Summary

We describe the anaesthetic management of a 21-year-old achondroplastic dwarf who presented for elective Caesarean section. Epidural anaesthesia has been performed in these patients, sometimes with technical difficulty due to their skeletal abnormalities. Previous reports have described using a reduced volume of epidural local anaesthetic to achieve a sensory level for Caesarean section. However, in our patient, an unusually large total volume (29 ml) of local anaesthetic had to be used; the resulting sensory level was only T₁₀. Caesarean section was performed with minimal patient discomfort. An epidurogram was performed after the Caesarean section to try to determine the cause of the low sensory level obtained.

Key Words: Anaesthesia: Obstetric, Caesarean section, Anaesthetic techniques: Epidural, Complications: Achondroplasia

Case Report

A 21-year-old primigravida who was diagnosed as an achondroplastic presented for elective Caesarean section at 38 weeks gestation. She had had an uneventful pregnancy, and no neurological or musculoskeletal symptoms. She had never had any anaesthetic prior to this proposed surgery.

On physical examination, she had the typical features of an achondroplastic dwarf. Her height was 120 cm and she weighed 54 kg. Airway assessment indicated potential intubation difficulty and was classified as Mallampati III¹. She had marked lumbar lordosis. Her baseline blood pressure was 110/70 mmHg. Pre-operative blood investigations were unremarkable. There was no pre-operative cervical spine X-ray.

The potential technical difficulties associated with general and regional anaesthesia were discussed with the patient. She consented to having a lumbar epidural

anaesthetic, failing which an awake fiberoptic intubation would be carried out prior to induction of general anaesthesia.

She was premedicated with oral ranitidine 150 mg and 0.3 M sodium citrate 30 ml. In the operating room, she was given an intravenous infusion of 500 ml of lactated Ringer's solution.

With the patient in the sitting position, the epidural space was identified with some difficulty at about L₃-L₄ interspace using an 18G Tuohy needle and loss of resistance to saline. It was difficult to identify the exact vertebral level as her marked lumbar lordosis did not allow accurate palpation of her lumbar vertebral spines.

An epidural catheter was inserted 2 cm into the epidural space. After aspiration of the catheter, a test dose of 3 ml of 0.5% bupivacaine was injected. There was no evidence of subarachnoid block after 10 minutes. A dose of 5 ml of 0.5% bupivacaine was then given. Over the

CASE REPORTS

next hour, another 21 ml of 0.5% bupivacaine with 100 µg of fentanyl was given in divided doses into the epidural space. The sensory level of blockade was tested to pin-prick at 10 minute intervals. In spite of this large total volume of local anaesthetic, the sensory blockade never went higher than T₁₀ dermatome, even though the patient was positioned head down to try to achieve a higher level of blockade.

At this point, surgery was allowed to proceed after discussion with the obstetrician. A 2.7 kg normal-looking female infant was delivered without difficulty and had an Apgar score of 9 at 1 minute and 10 at 5 minutes. The patient suffered minimal discomfort during the delivery of the baby, and the rest of the procedure was uneventful.

The patient's blood pressure and heart rate remained near the baseline level throughout the whole procedure as well as in the recovery room. Post-operatively in

the recovery room, analgesia was achieved with epidural pethidine 50 mg.

On discharge from the recovery room, epidurography was carried out. Contrast was injected into the epidural space via the epidural catheter. There was free flow of contrast upwards and downwards from the level of entry of the catheter, but the flow of contrast was arrested at the upper border of T₁₁ vertebra. However, no obvious anatomical abnormalities could be demonstrated radiologically. These findings were consistent with the level of sensory blockade achieved with the epidural anaesthesia.

The patient made an uneventful recovery and was discharged on the 7th post-operative day. Magnetic resonance imaging of her spine was planned for her at a later date. However, she defaulted post-natal follow-up and no further investigations could be carried out on her.

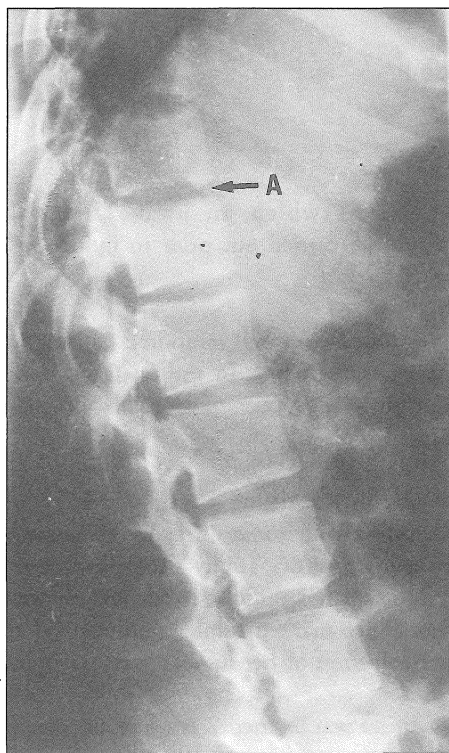


Fig. 1: Control film

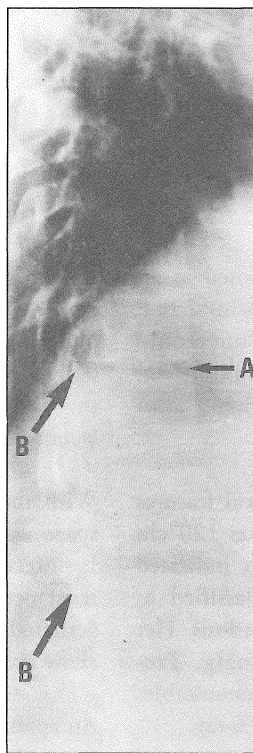


Fig. 2: With contrast in the epidural space. Arrows B show the column of contrast which is arrested at the upper border of T₁₁

Figs. 1 and 2:
Epidurogram Arrows A indicate
T₁₀-T₁₁ intervertebral space

Table 1
Summary of epidural/spinal anaesthesia in achondroplastic dwarfs

Author	No. of patients	Patient's Ht and Wt	Regional anaesthesia	Local anaesthetic	Volume test dose	Volume total dose	Sensory level	Complications
Watts ⁴ 1975	6		Subarachnoid & epidural					1 spinal - hypotension 1 abandoned attempt at spinal 1 epidural - inadvertent dural puncture
Cohen ⁶ 1980	1	122 cm 57 kg	Epidural	3% 2-chloroprocaine	3 ml	9 ml (+ 9 ml 35 min later)	T ₄	Inadvertent dural puncture Epidural catheter could not be advanced on 2 occasions
Brimacombe ¹⁰ 1990	1	121 cm 73 kg	Epidural	0.5% plain bupivacaine	2 ml	12 ml	C ₅	Difficulty in threading catheter at 1st attempt, then had venous cannulation Difficulty in threading catheter at 2nd attempt
Wardall ⁸ 1990	1	111 cm 46 kg	Epidural	0.5% bupivacaine	3 ml	5 ml	T ₄ on left T ₆ on right	
Carstoniu ⁹ 1992	1	119 cm 61 kg	Epidural	carbonated lignocaine 2% with adrenaline 1:200,000	1 ml	8 ml (+ fentanyl 50µg)	T ₅	
Crawford ¹¹ 1992	1	117 cm 44 kg	Subarachnoid (with microspinal catheter)	Hyperbaric 0.5% bupivacaine		1.0 ml (+ 0.3 ml 40 min later)	T ₄	

Discussion

Achondroplasia is the most common form of dwarfism, with a reported incidence of between 1 in 67,000 and 1 in 26,000 total births (1 in 10,000 live births). Transmission is by an autosomal dominant gene. 80% result from spontaneous mutations and 20% are familial. There is a predominance of females over males. The defect is caused by poor development and premature ossification of bones which are formed from cartilage, with normal periosteal bone formation, resulting in the characteristic craniofacial and spinal abnormalities. Fertility is low in these dwarfs².

Pregnancy in achondroplastic dwarfs exacerbates the problems faced by these patients. Cardiorespiratory compromise is probably the most serious. Thoracic kyphoscoliosis may be present. The distance between the xiphoid and symphysis pubis is also shorter than in the normal patient. The small maternal pelvis and marked lumbar lordosis prevent engagement of the foetal head, causing the uterus to remain as an abdominal organ, thus greatly reducing the FRC to a greater extent than in normal pregnancies. These characteristics lead to decreased lung and chest wall compliance and increased shunting of deoxygenated blood³.

CASE REPORTS

There were few reports of anaesthesia for Caesarean section in achondroplastic dwarfs prior to 1990. General anaesthesia used to be recommended as the technique of choice in achondroplasia⁴ although difficulty in intubation was reported. Limited extension at the atlanto-occipital joint, together with the abnormal shape of the head and mandible and a large tongue give rise to this difficulty. Three reports^{5,6,7} of general anaesthesia in achondroplastic dwarfs, however, did not encounter difficulty in intubation. Our patient had no pre-operative X-rays of the cervical spine, but as the initial assessment of the airway indicated possible difficulty in intubation, we decided that an epidural anaesthetic would be safer for the patient, albeit technical problems with the procedure.

Regional anaesthesia in the achondroplastic dwarf is also fraught with problems. Anatomical abnormalities, including kyphoscoliosis, stenosis of the vertebral canal, shortening of the pedicles, reduced interpedicular distance and osteophyte formation, makes it more difficult to perform extradural or spinal anaesthesia, with increased risk of inadvertent dural puncture. Recently, however, there have been reports of successful epidural anaesthesia for achondroplastic dwarfs^{8,9,10}. The optimum test dose and total dose of epidural local

anaesthetic in the achondroplastic dwarf are uncertain. Most reports indicate the need for a much reduced dose of local anaesthetic, as illustrated by Wardall⁸. Crawford¹¹ described the use of spinal anaesthesia using a microspinal catheter, which produced good operating conditions for Caesarean section.

This is the first report of such a high dose of local anaesthetic used without achieving the usual desired sensory level of T₄-T₆ for Caesarean section. In the event that the epidural failed, the use of awake fiberoptic intubation would have avoided the risks of difficult or failed intubation under anaesthesia for a pregnant patient at term.

Our patient probably had stenosis of the thoracic vertebrae at T₁₀-T₁₁. Although she did not have any neurological deficit at this time, it is known that achondroplastic dwarfs may develop neurological manifestations of their vertebral abnormalities only in their third or fourth decade of life.

As demonstrated by this case, anaesthesia for the achondroplastic dwarf is a challenge to the anaesthetist, whatever technique is chosen.

References

1. Mallampati SR, Gatt SP, Gugino LD, *et al.* A clinical sign to predict difficult tracheal intubation: A prospective study. *Can J Anaesth* 1985;32 : 429-34.
2. Murdoch JL, Walker BA, Hall JG, *et al.* Achondroplasia - A genetic and statistical survey. *Ann Hum Genet* 1970;33 : 227-44.
3. Tyson JE, Barnes AC, McKusick VA, *et al.* Obstetric and gynecologic considerations of dwarfism. *Am J Obstet Gynecol* 1970;108 : 688-704.
4. Walts LF, Finerman G, Wyatt GM. Anaesthesia for Dwarfs and other Patients of Pathological Small Stature. *Canadian Anaesthetists' Society Journal* 1975;22 : 703-9.
5. Bancroft GH, Lauria JI. Ketamine Induction for Caesarean Section in a patient with Acute Intermittent Porphyria and Achondroplastic Dwarfism. *Anesthesiology* 1983;59 : 143-4.
6. Cohen SE. Anesthesia for Caesarean Section in Achondroplastic Dwarfs. *Anesthesiology* March 1980;52 : 264-6.
7. McArthur RDA. Obstetric Anaesthesia in an Achondroplastic Dwarf at a Regional Hospital. *Anaesthesia and Intensive Care* 1992;20 : 376-8.
8. Wardall GJ, Frame WT. Extradural Anaesthesia for Caesarean Section in Achondroplasia. *British Journal of Anaesthesia* 1990;64 : 367-70.
9. Carstoniu J, Yee I, Halpern S. Epidural anaesthesia for Caesarean Section in an achondroplastic dwarf. *Canadian Journal of Anaesthesia* 1992;39 : 7 : 708-11.
10. Brimacombe JR, Caunt JA. Anaesthesia in a gravid achondroplastic dwarf. *Anaesthesia* 1990;45 : 132-4.
11. Crawford M, Dutton DA. Spinal Anaesthesia for Caesarean section in an achondroplastic dwarf. *Anaesthesia* 1992;47(11) : 1007 (letter).