

References

1. Lishman WA. Organic Psychiatry – The Psychological Consequences of Cerebral Disorder. (2nd ed). Blackwell Scientific Publications, 1987.
2. Bond MR, Reid J. Organic Disorders. In: Kendall RE, Zealley AK (eds). Companion to Psychiatric Studies (5th ed). Churchill Livingstone, 1993 : 295-341.
3. Lee MK, Ng WK, Jeyakumar D. Huntington Disease: Report of First Case Documented in Malaysia. Med J Mal 1994;49 : 297-300.

Bladder Outflow Obstruction Masquerading as Pelviureteric Junction (PUJ) Obstruction

C L Teh, FRCS (Edin)*, C C M Lei, FRCS (Urol)**, A Khairullah, FRCS (G)*, * Department of Urology, Hospital Kuala Lumpur, 50586 Kuala Lumpur, ** Universiti Malaysia Sarawak

Summary

We report a case of bladder outflow obstruction presenting with upper tract dilatation mistaken initially as pelviureteric junction (PUJ) obstruction. The lower tract obstruction ought to be dealt with first before upper tract obstruction is assessed because the renal pelvic pressure is significantly affected by vesical filling and high bladder pressure.

Key Words: Bladder outflow obstruction, Pelviureteric junction obstruction

Introduction

Patients with bladder outflow obstruction commonly present with obstructive symptoms such as hesitancy and poor stream. In this case the patient developed upper tract symptoms associated with renal impairment. Due to the tendency to develop upper tract dilatation, the dilated renal pelvis might be mistakenly construed as pelviureteric junction obstruction.

Case Report

Mr. C.S. is a 59-year-old gentleman who was referred to the Department of Urology Hospital Kuala Lumpur for the management of a solitary right kidney with hydronephrosis and renal impairment. He gave a 9-

year history of intermittent left loin ache for which he usually consulted his general practitioner. In April 1994, he sought treatment in a private hospital in Ipoh for severe acute left renal colic associated with fever and vomiting. Further investigations with intravenous urography and retrograde pyelography demonstrated his left kidney to be non-functioning & grossly hydronephrotic associated with a narrow pelviureteric junction (Fig. 1); the right pelvicalyceal system appeared normal. At exploration there was pyonephrosis and a simple nephrectomy was undertaken based on the assumption of a left non-functioning and pyonephrotic kidney with pelviureteric junction (PUJ) obstruction. His postoperative recovery was uneventful.

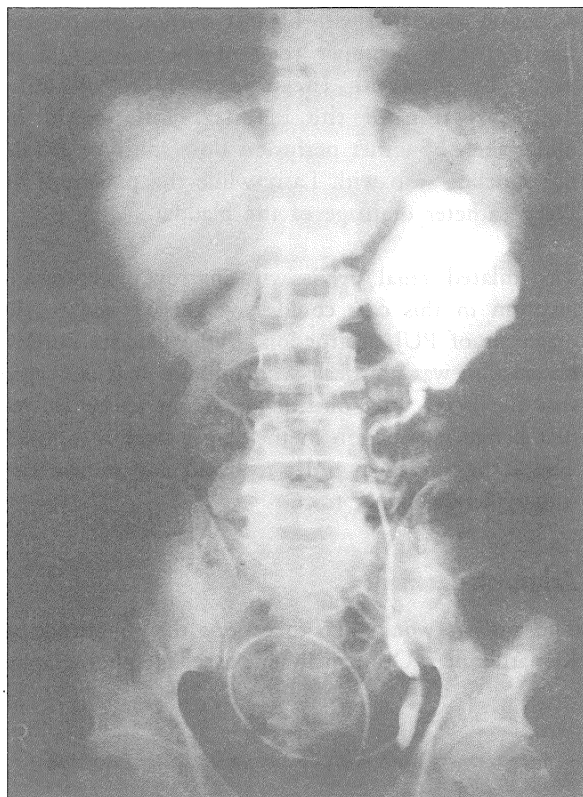


Fig. 1: Gross hydronephrosis and narrow pelviureteric junction seen in left retrograde pyelogram

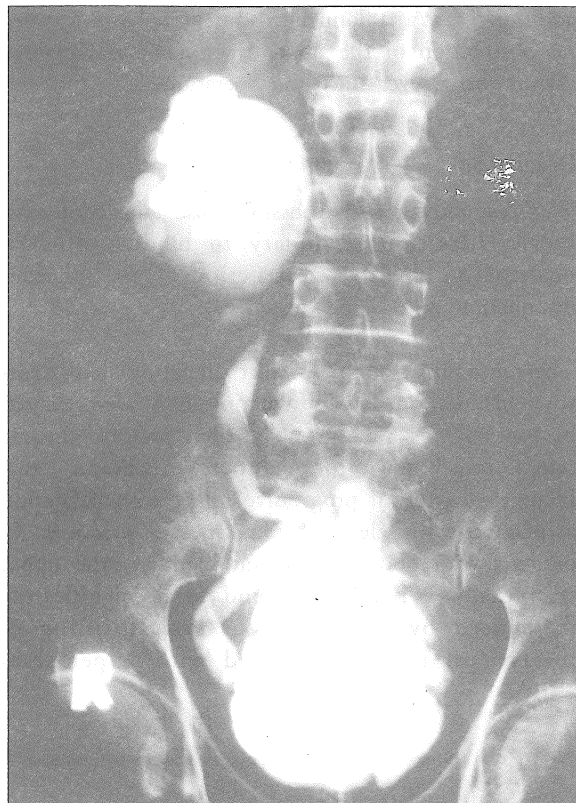


Fig. 2: Retrograde pyelogram showed grossly dilated right renal pelvis and hydroureter. Bladder was markedly trabeculated

Five months later he began to develop similar attacks of renal colic on his right side. In addition he had poor stream and hesitancy for a number of years. However, there was no episode of acute urine retention or urinary tract infection. Physical examination was unremarkable. No bladder distention was noted. His prostate gland was small and soft on rectal examination.

Intravenous urography at this time showed right hydronephrosis with narrow pelviureteric junction, suggestive of PUJ obstruction. A micturiting cystourethrogram revealed a severely trabeculated bladder with no vesicoureteric reflux. A Foley catheter was inserted to drain the bladder because of significant residual urine (250 mls).

The clinical picture indicated bladder outflow obstruction and possible PUJ obstruction. His serum creatinine was elevated at 354 $\mu\text{mol/L}$ on admission and had dropped to 274 $\mu\text{mol/L}$ a week after Foley catheter insertion. A right retrograde pyelogram done a week later revealed a tortuous right ureter and grossly dilated renal pelvis and calyces (Fig. 2). Urodynamics confirmed a low compliant bladder and high voiding pressure with maximum voiding pressure of 263 cm water (normal < 60 cm water), confirming bladder outflow obstruction.

A transurethral incision of the prostate was undertaken on 6/10/94. His creatinine improved to 153 $\mu\text{mol/L}$ one month postoperatively. The postoperative voiding cystometrograph and uroflowmetry showed normal voiding detrusor pressure and peak flow rate. In

CASE REPORTS

addition DTPA radionuclide scan with Lasix revealed no obstruction of the upper tract. He has remained asymptomatic ever since the operation.

Discussion

This case illustrates the possible misdiagnosis of renal pelvic dilatation secondary to bladder outflow obstruction as PUJ obstruction if the bladder dysfunction were to be missed.

The mechanism of upper tract dilatation in patients with bladder outflow obstruction had been elicited by Jones *et al*¹. Such group of high pressure chronic retention is known to predispose to chronic renal failure by virtue of progressive upper tract dilatation associated with elevated renal pelvic pressure. In patients with poorly compliant bladders, the upper tract drainage had been found to be significantly influenced by the degree of vesical filling & intravesical pressure^{2,3}. Faced with upper tract

dilatation associated with bladder outflow obstruction, the diagnosis of upper tract obstruction could be made by studying the upper tract following decompression of the bladder. This could be undertaken by either perfusion flow study or DTPA radionuclide scan with Lasix while the patient is on Foley catheter drainage of the bladder.

The dilated renal pelvis with narrow pelviureteric junction in this case could have misled one to the diagnosis of PUJ obstruction, if the bladder outflow obstruction was not dealt with initially. It is envisaged that the lower tract obstruction ought to be tackled first before obstruction in the upper tract is assessed. This is important in order to avoid any unnecessary surgery of the upper tract.

Acknowledgement

The authors would like to express their gratitude to Kamarulzaman Othman for his excellent photography.

References

1. Jones DA, Holden D and George NJR. Mechanism of upper tract dilatation in patients with thick walled bladders, chronic retention of urine and associated hydronephrosis. *J Urol* 1988;140 : 326-9.
2. George NJ, O'Reilly PH, Barnard RJ *et al*. Practical management of patients with dilated upper tracts and chronic retention of urine. *Br J Urol* 1984;56 : 9-12.
3. Styles RA, Neal DE, Griffiths CJ *et al*. Long term monitoring of bladder pressure in chronic retention of urine : the relationship between detrusor activity and upper tract dilatation. *J Urol* 1988;140 : 330-4.