

# Splenorrhaphy : Omental Pouch

T R Lazim, FRCS

M Salleh

A S Abu Bakar, DVM

Universiti Sains Malaysia,  
16150 Kubang Kerian, Kelantan

## Summary

This work studies the efficacy of an autogenous viable omental pouch as a means of splenorrhaphy for saving the traumatised spleen.

One sheep and 9 goat spleens were mobilised and their vascular pedicles clamped. All spleens were subjected to AAST grade IV trauma. The injured spleens were put into omental pouches and manual pressure was applied for 10 minutes after removal of the vascular clamp. Bleeding was controlled in 8 animals which became fully active 12-36 hours postoperatively. Two animals died, one due to aspiration of gastric contents during surgery and the other due to bleeding 24 hours postoperatively. All remaining spleens were harvested after 6 weeks. They were surrounded by a fibrous capsule and the previously inflicted injuries were easily identifiable.

Viable omental pouch based on left epiploic vascular pedicle offers itself as a good autogenous alternative to other methods used for saving the injured spleen. This method has been used in two humans so far.

**Key Words:** Splenic injury, Splenorrhaphy, Omental pouch

## Introduction

Attempts at saving the spleen are almost 90 years old. Various techniques of suturing the injured spleen have been used<sup>1,2,3,4,5</sup>. Some of the pioneers did not trust simple repair alone, therefore splenic artery ligation was added<sup>6</sup>. Other more cautious surgeons repaired the tear, tied the splenic artery, wrapped the spleen with omentum and cocooned the lot with chromic cat gut<sup>7</sup>. However, more recent innovators used absorbable mesh<sup>8,9</sup> and others used amniotic membrane wrapping<sup>10</sup>.

These materials cost money, are not available in many hospitals across the world and because they are foreign bodies, their use is not recommended in septic situations such as bowel injury.

The present animal experimental study was undertaken to test the hypothesis that viable omentum can be used as a substitute for the use of mesh, or amniotic membrane wrapping.

## Materials and Methods

One sheep and 9 adult local goats (*Capra hircus*) weighing 12-25kg (mean 14kg) were used.

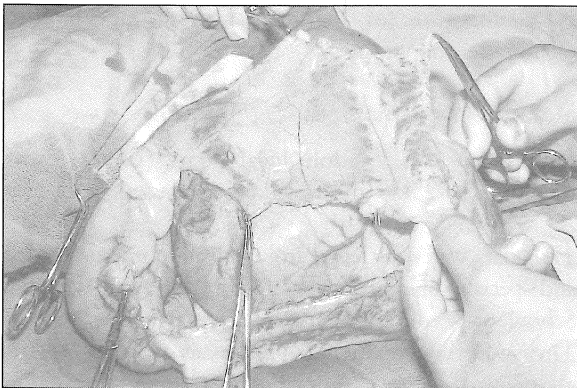
The goats were purchased from private domestic sources and specially bred and maintained in the Animal House, School of Medical Sciences, Universiti Sains Malaysia. They were housed in individual pens (2.1m x 1.05m) and allowed to graze freely in the pastures surrounding the pens. Feeding chaff and concentrates were also provided in the hopper as feed supplements.

### Anaesthetic administration

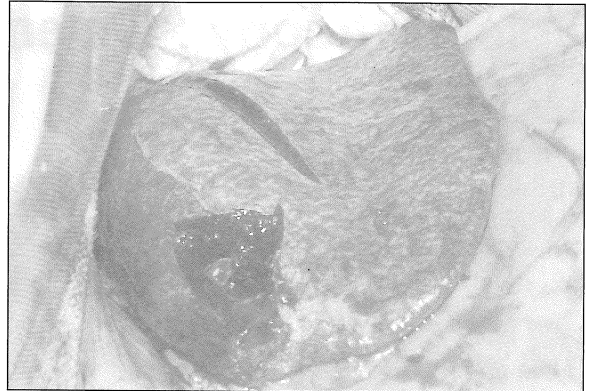
Food was withheld for 24 hours prior to general anaesthesia in order to reduce the volume of the stomach contents. The ten animals were anaesthetized with Tiletamine/Zolazepam (Zoletil, Virbac Co., France) at a dose of 11mg/kg body weight, administered intravenously via the external jugular vein. Each regimen included Atropine at a dose rate of 0.5mg/kg 15 minutes before surgery.

Access to the peritoneal cavity was gained through an upper midline incision in 5 subjects and via a transverse subcostal incision in the remaining group.

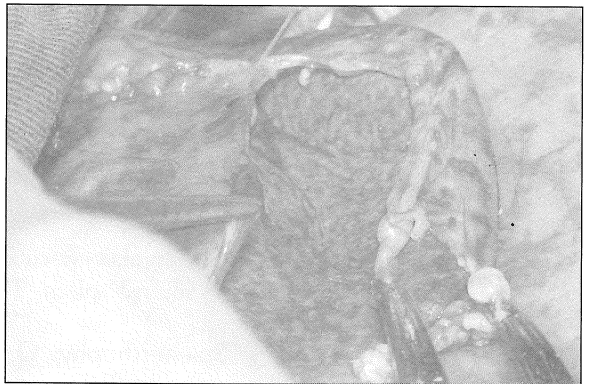The spleen was mobilised and delivered into the wound. A rotation flap of omentum was fashioned of a size large enough to wrap the spleen (Fig. 1). The flap was then rotated and spread like a carpet underneath the spleen. The splenic vascular pedicle was clamped with a vascular clamp. A transverse incision 60mm long and 30mm deep was inflicted upon the spleen. Furthermore an area of the capsule 20x20x1mm was shaved off the spleen (Fig. 2). The long incision was approximated by two chromic catgut stitches. The omental pouch was fashioned using 2/0 plain catgut (Fig. 3). Care was taken to ensure that there was no tear in the omentum and the only loose area of omental wrapping was around the vascular pedicle of the spleen.



**Fig. 1:** A piece of omentum is fashioned. Observe the precarious blood supply. Unlike the vascular arrangement in the human omentum



**Fig. 2:** Injuries inflicted upon goat's spleen



**Fig. 3:** Omental pouch in the process of being fashioned

Manual pressure was applied on the spleen. Then the vascular clamp was removed. Pressure was maintained for 10 minutes before retaining the spleen and the stomach into the abdominal cavity.

It is important to point out that none of the animals were transfused with colloid, plasma expanders, or blood. The abdominal wall was closed with 2.0 linen and the skin with subcuticular 2/0 Dexon.

### Postoperative care

The subjects were covered with towels or blankets to regulate their body temperature and were then transferred to the recovery room after surgery, placed on a dry hay or straw bed and watched closely.

All animals were administered with Buprenorphine

hydrochloride analgesia (Terragesic, Reckitt & Coleman) at a dose of 0.02mg/kg/body weight I.M. on the first post operative day every 12 hours.

The animals were parentally administered with intravenous infusions of electrolytes, amino acid, dextrose and vitamin B complex (Duphalyte infusion – Solvay Duphar B.V. Weesp, Holland) at a dose of 50ml per 5 kg body weight. Amoxycillin (Norbrook Laboratories Ltd., UK) at a dose of 15 mg/kg of body weight given intramuscularly and Prednisolone acetate 1% (Atarost, West Germany) at a dose of 25mg/kg were also administered intramuscularly to animals suspected of aspiration.

## Results

During surgery, the thin membranous diaphragm was breached on two occasions, causing pneumothorax. The tears were blocked with a wet towel during expiration until the end of the procedure. Before closure of the abdominal wall, a nasogastric tube was placed in the pleural cavity through the tear. Negative suction was applied through the tube after closure of the abdominal wall. The tube was then removed. No untoward effects resulted.

In all animals, bleeding from the shaved capsular area was more difficult to control than that from the incised area. In 2 animals there was profuse and alarming bleeding from the injured spleen, despite clamping the pedicle, which may suggest the presence of accessory blood supply. Bleeding was controlled after fashioning the omental pouch and application of manual pressure.

Five animals bled between 250-500ml (mean 440ml) after removal of the vascular pedicle clamp. In 3 of these, the bleeding was through gaps in the stitching line used to fashion the pouch and in 2 of the latter 3, the bleeding was alarming. The presence of a tear in the omentum encouraged a continuation of bleeding which was controlled by repair of the omental tear and by reapplication of manual pressure.

The other 5 animals bled 50-200ml (mean 110ml). However, one animal that bled about 100ml during surgery, started to bleed 6 hours postoperatively. This

animal died 24 hours later; post-mortem revealed antimortem blood clots outside and inside the pouch almost encasing the spleen. Death was attributed to cardio-respiratory failure precipitated by blood loss. A second goat died on the operating table after aspirating a large amount of gastric contents. Postmortem study of this animal did not show intraperitoneal bleeding. The remaining 8 animals were grazing in the field 12-36 hours postoperatively.

All remaining animals were sacrificed 6-8 weeks postoperatively and the spleens were harvested. There were dense adhesions surrounding the spleens. The omentum used for wrapping the spleen was largely not recognised and it was replaced by a white capsule around the spleen and in all animals, saponification nodules caused by fat necrosis was found. The area of splenic injury previously inflicted continued to be recognised through the fibrous tissue capsule. Some spleens were normal sized and others were smaller than preoperatively by about 1/3.

## Discussion

Goat and sheep spleens are slightly larger than the normal human spleen and occupy almost the same anatomical position. The key issue in this technique is complete spleen mobilisation and clamping of the vascular pedicle. The magnitude of injury inflicted upon the spleen in this work is equivalent to grade IV, according to organ injury classification by the American Association for Surgery of Trauma<sup>11</sup>. The two chromic catgut stitches used to approximate the gaping wound in the spleen left 3 gaps in the splenic tissue, each 20mm long and 30mm deep. Therefore, these stitches were not considered to provide adequate haemostasis. Our protocol is designed not to transfuse the animals with plasma, plasma expanders, or blood; it is therefore prudent to adopt such measures which one would use in human surgery.

Shaving 1mm thickness of splenic tissue with the splenic capsule proved to be a persistent bleeder that was rather difficult to control. This may explain why many surgeons prefer to excise the spleen in human surgery rather than attempt a splenorrhaphy, for fear of rebleeding postoperatively. Control of bleeding after fashioning the omental pouch was made difficult by

the presence of omental tears, or a loose stitching line. All intact omental pouches developed small soft haematoma. These findings highlight the importance of low pressure tamponade, akin to interstitial pressure, in controlling bleeding. The presence of an omental layer enhances the haemostatic effect of blood clots formed on the injured areas of the spleen.

Although the momentum of splenic saving procedures is becoming strong and justifiable, splenectomy may continue to be required in many patients, because of the magnitude of splenic injury. In such a situation another surgical modality may be used i.e. splenic autotransplantation, or ligation of the splenic artery.

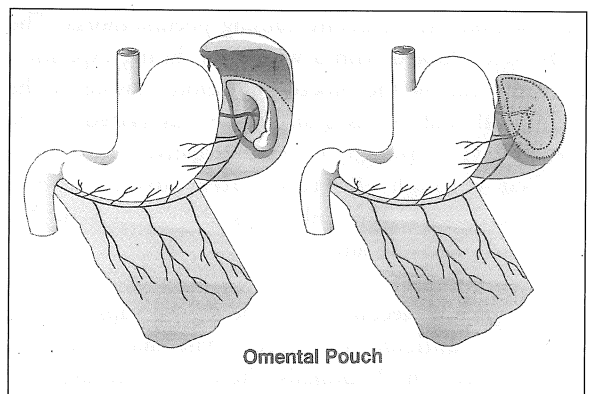
Splenic autotransplantation continues to be an intriguing, but unproven modality. Ligation of the splenic artery and autotransplantation lack two important factors in order to maintain adequate splenic function and protection from overwhelming post splenectomy infection. These are the presence of a critical mass of splenic tissue (about 1/3 of the spleen) receiving a critical volume of blood flow<sup>12-18</sup>.

Splenic salvage, not only maintains a functional spleen, but is also superior to other modalities of management. The morbidity and mortality associated with splenectomy is much greater than that associated with splenorrhaphy<sup>19,20</sup>. Although nonoperative management in a stable patient with an injured spleen is attractive, nonetheless, one has to keep in mind that deterioration of such patients may be sudden and unexpected. Failed nonoperative management results in splenectomy 4 times as often as it does in splenorrhaphy<sup>21</sup>.

Other methods of conserving the spleen are absorbable mesh<sup>8,9</sup>, amniotic sac<sup>11</sup> and glue gel foam<sup>22,23</sup>. These materials may not be available in many parts of the world. They cost money and may not be used where intraperitoneal contamination is present. The omentum is a natural material, almost always available and free; its role in septic and inflammatory situations is well known.

Successful application in humans of absorbable mesh and amnion wrapping is very encouraging, especially the latter method that is very similar to the omental pouch and supports its application. Omentum is widely used in surgery. A pedicle of omentum based upon one gastroepiploic vessel was effectively used as an autogenous pack to stop bleeding from hepatic laceration<sup>24-26</sup>. We propose an omental pedicle based upon the left gastroepiploic vessels (Fig. 4) to fashion a viable and efficient pouch. This method was used successfully by one the authors (TRL) in two humans with ruptured spleens (unpublished data).

We recommend that this method be used in conjunction with other known, or customary methods of splenorrhaphy, where these methods alone are felt not sufficient to secure adequate haemostasis.



**Fig. 4: The proposed method of fashioning omental pouch in humans**

#### Acknowledgements

We thank the members of the Medical Illustration Department at the Universiti Sains Malaysia, Kubang Kerian, Kelantan, particularly Mr. Noradzaman Mohd. Noor, Mr. Zainury Ghazali, Mrs Engku Ramlah Engku Mat and Miss Malica Renga Sami.

## References

1. Dretzka L. Rupture of the spleen. *Surg Gynecol Obstet* 1930;51 : 258-61.
2. Mazel MS. Traumatic Rupture of the spleen. *J Pediatr* 1945;26 : 82-8.
3. Mishalany HG, Mahour GH, Andrassy RJ, Harrison MR, Wolley MM. Modalities of preservation of the traumatized spleen. *Am J Surg* 1978;136(6) : 697-700.
4. Lynn HB. A re-evaluation of splenectomy (editorial). *Pediatr Ann* 1976;5(10) : 12-7.
5. Buntain WL, Lynn HB. Splenorrhaphy: changing concepts for the traumatized spleen. *Surgery* 1979;86(5) : 748-60.
6. Sherman NJ, Asch MJ. Conservation surgery for splenic injuries. *Pediatrics* 1978;61 : 267-71.
7. Ratner MH, Garrow E, Valda V, Shashikumar VL, Somers LA. Surgical repair of the injured spleen. *J Pediatr Surg* 1977;12 (6) : 1019-25.
8. Lange DA, Zaret P, Merlotti GJ, Robin AP, Sheaff C, Barrett JA. The use of absorbable mesh in splenic trauma. *J Trauma* 1988;28 : 269-75.
9. Delany HM, Porreca F, Mitsudo S, Solanki B, Rudavsky A. Splenic capping. An experimental study of a new technique for splenorrhaphy using woven polyglycolic acid mesh. *Ann Surg* 1982;196 : 187-93.
10. Erdener A, Ulman I, Ilhan H, Soydan S. Amniotic membrane wrapping: an alternative method to the splenorrhaphy in the injured spleen. *Eur J Pediatr Surg* 1992;2(1) : 26-8.
11. Moore EE, Shackford SR, Pachter HL, *et al.* Organ injury scaling: spleen, liver and kidney. *J Trauma* 1989;29 : 1164-666.
12. Pabst R, Kamran D, Creutzig H. Splenic regeneration and blood flow after ligation of splenic artery or partial splenectomy. *Am J Surg* 1984;147 : 382-6.
13. Van Wyck DB, Witte MH, Witte CL, Thies AC. Critical splenic mass for survival from experimental pneumococemia. *J Surg Res* 1980;28 : 14-7.
14. Horton J, Ogden ME, Williams S, Coln D. The importance of splenic blood flow in clearing pneumococcal organisms. *Ann Surg* 1982;195(2) : 172-6.
15. van Wyck DB, Witte MH, Witte CL. Compensatory spleen growth and protective function in rats. *Clin Sci* 1986;71 : 573-9.
16. Livingston CD, Levine BA, Sirinek KR. Site of splenic autotransplantation affects protection from sepsis. *Am J Surg* 1983;146 : 734-7.
17. Cooney DR, Dearth JC, Swanson SE, Dewanjee MK, Telander RL. Relative merits of partial splenectomy, splenic reimplantation and immunization in preventing postsplenectomy infection. *Surgery* 1979;86 : 561-9.
18. Schwartz AO, Zadeh M, Goldstein R. Antibody response to intravenous immunization following splenic autotransplantation in Sprague-Dawley rats. *Blood* 1977;49 : 779-83.
19. Schweizer W, Bohlen L, Gilg M, Blumgart LH. Prospective study of the early postoperative course of splenic rupture: spleen preservation versus splenectomy. *Helv Chir Acta* 1992;58(5) : 647-53.
20. Feliciano DV, Bitondo CG, Mattox KL, Rumisek JD, Burch JM, Jordan GL Jr. A four-year experience with splenectomy versus splenorrhaphy. *Ann Surg* 1985;5 : 568-75.
21. Wisner DH, Blaisdell FW. When to save the ruptured spleen. *Surgery* 1992;111(2) : 121-2.
22. Scheele J, Gentsch HH, Matteson E. Splenic repair by fibrin tissue adhesive and collagen fleece. *Surgery* 1984;95 : 6-13.
23. Kram HB, Del Junco T, Clark SR, Ocampo HP, Shoemaker WC. Technique of splenic preservation using Fibrin glue. *J Trauma* 1990;30(1) : 97-101.
24. Stone HH, Lamb JM. Use of a pedicled omentum as an autogenous pack for control of hemorrhage in major injuries of the liver. *Surg Gynecol Obstet* 1975;141 : 92-4.
25. Pachter HL, Spencer FC, Hofstetter SR, Coppa GF. Experience with finger fracture technique to achieve intra-hepatic hemostasis in 75 patients with severe injuries of the liver. *Ann Surg* 1983;197 : 771-7.
26. Fabian TC, Stone HH. Arrest of severe liver hemorrhage by an omental pack. *South Med J* 1980;73 : 1487-90.