

Fatal Intra-Cranial Haemorrhage in 2 Cases of Beta-Thalassaemia Major

K F Lee, MRCP

Paediatrics Unit, Hospital Kuala Terengganu, Terengganu

Summary

Spontaneous intracranial haemorrhage is one of the cerebrovascular complications in beta-thalassaemia major patients. This is a report of 2 cases of fatal intracranial haemorrhage. Their ages were 12 and 7 years respectively, and they had been receiving regular blood transfusion for the past 3 and 2 years respectively. They developed acute onset of headache, loss of consciousness and convulsions at 5 and 2 days respectively after their last blood transfusion. C-T scan of the brain showed massive intracranial haemorrhage with extension into the ventricles. The spontaneous intracranial haemorrhages in these two cases was probably multi-factorial in origin. The predisposing factors included recent blood transfusion, prolonged prothrombin time and partial thromboplastin time as well as reduced platelet count.

Key Words: Intracranial haemorrhage, Beta-thalassaemia major

Introduction

Beta-thalassaemia major remains a distressing disease for the patient, his or her family as well as the attending doctor. Most hospitals in Malaysia can only provide symptomatic relief to these patients by regular blood transfusion. In November 1992 and January 1993, two patients developed fatal intracranial haemorrhage out of 62 beta-thalassaemia major patients on our follow-up.

Case 1

HA was a 12-year-old girl with beta-thalassaemia major. The available records documented that she had been receiving blood transfusion from the age of 5 years. From 9 years of age, she was on monthly to two monthly blood transfusion. For the past 2 years her average pre-transfusion haemoglobin was 4.1 g/dl, the volume of packed red cells transfused per year was 220 mls per kg body weight, and volume of packed cells given per admission was 20 to 30 mls per kg body weight over 3 to 4 hours.

On 8-11-92, her pre-transfusion haemoglobin was 5.3 g/dl. Her blood pressure was 100/60 mmHg. Examination of her abdomen revealed an enlarged liver palpable 12 cm below right subcostal margin and spleen extending 16 cm below left subcostal margin. She was transfused 18 mls per kg body weight on that day followed by another 15 mls per kg on 10-11-92.

She was admitted on 12-11-92 because of a short episode of headache with reduced level of consciousness and clonic movement of the right upper limb. Examination on admission revealed slight increase in tone and reflexes of the right upper and lower limbs which resolved nine hours later. There was no other neurological deficit. Examination of the optic fundi did not reveal any haemorrhages. Investigations done revealed haemoglobin of 13.7 g/dl, reduced platelet count of 60,000/mm³, prothrombin time 17 seconds and partial thromboplastin time 47 seconds (normal range 32 to 45 seconds). However, her headache recurred the following day (13-11-92) and lasted 4 hours. Blood pressure taken at that time was 140/70

mmHg. She felt well over the following 2 days and discharge was granted at her own request on 15-11-94.

On 16-11-94 (five days after the last transfusion), she was readmitted with complaints of sudden onset of severe headache, loss of consciousness and right-sided fits. Her blood pressure on admission was 140/80 mmHg. She was very drowsy and could only utter in response to calling. Investigations done revealed a haemoglobin of 9.5 g/dl, reduced platelet count of 40,000/mm³, bleeding time 3.5 minutes, clotting time 5 minutes, prolonged prothrombin time of 19 seconds (with prolonged prothrombin ratio of 1.36) and prolonged partial thromboplastin time of 130 seconds (normal range 32 to 45 seconds). C-T scan of brain showed massive intracerebral haemorrhage in the left occipito-parietal region with extension into the lateral ventricles (Figure 1). There was no ventilator available and she died 10 hours after admission from raised intracranial pressure.

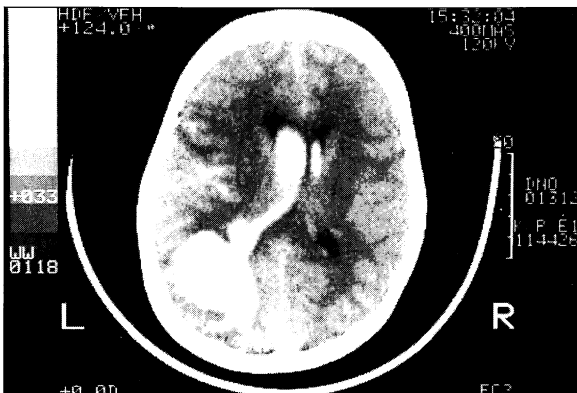


Fig. 1: Case 1 (haemorrhage in left occipito-parietal region)

Case 2

TM was a 7-year-old boy who was diagnosed as beta-thalassaemia major since the age of 11 months. He did not come regularly for his blood transfusion. For the past 2 years, his average pre-transfusion haemoglobin was 5.1 g/dl, the volume of packed red cells transfused per year was only 100 mls per kg body weight, and the volume of packed cells transfused per admission was 20 to 25 mls per kg body weight.

On 3-1-93, his pre-transfusion haemoglobin was 2.1

g/dl. Examination of his abdomen revealed liver palpable 5 cm below right subcostal margin and spleen extending 7 cm below left subcostal margin. He was clinically in heart failure and was given oxygen via face mask, diuretics and was transfused packed red cells of volume 12 mls per kg body weight daily for the following three days. On 9-1-93, his haemoglobin was 7.1 g/dl and blood pressure was 110/70 mmHg. He was given another 16 mls per kg of packed cells and discharged home on 10-1-93.

On 11-1-93 (48 hours after his last blood transfusion), he was re-admitted with problem of sudden onset of headache, reduced level of consciousness and 2 episodes of generalised tonic-clonic fits. He had another episode of generalised tonic-clonic convulsion 15 minutes after admission. His blood pressure taken then was 130/90 mmHg. Investigations done revealed a haemoglobin of 11.1 g/dl, reduced platelet count of 80,000/mm³, bleeding time 4.5 minutes, clotting time 5 minutes, prothrombin time 17 seconds (control of 14 seconds and prothrombin ratio of 1.21), prolonged partial thromboplastin time of 58 seconds (normal range 32 to 45 seconds) and thrombin time of 7 seconds. Four hours after admission, he was alert, able to follow commands and did not appear to have any localising neurological deficit. However, he developed an episode of left-sided convulsion the following hour and his level of consciousness progressively deteriorated. He was intubated and ventilated 9 hours after admission. The following day (22 hours after admission), his pupils were already fixed and dilated. C-T scan of the brain showed

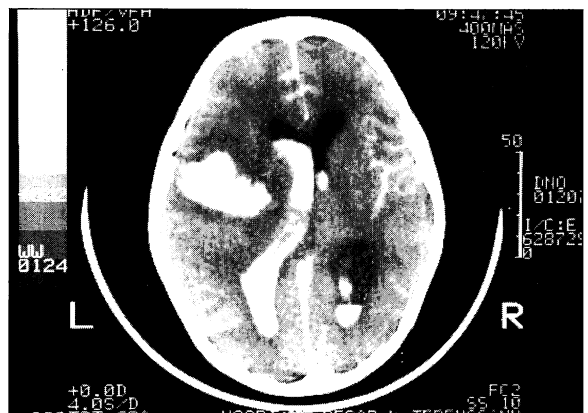

Fig. 2: Case 2 (haemorrhage in left temporo-parietal region)

CASE REPORT

massive intracerebral haemorrhage in the left temporo-parietal region with extension into the lateral ventricles (Figure 2). By that time he was probably brain dead and had cardiorespiratory arrest one week later.

Discussion

There is a variety of cerebro-vascular diseases affecting beta-thalassaemia patients. These include intracranial haemorrhage¹ and ischaemic arterial thrombosis². Wasi¹ described a syndrome of hypertension and convulsion in 8 patients with 3 deaths, of which 2 post-mortems were done. The brain autopsies showed changes similar to hypertensive cerebral haemorrhage. Michaeli² reported 4 patients with unusual thrombo-embolic manifestations, namely recurrent arterial occlusion, recurrent pulmonary thromboembolism, venous thrombosis and a fatal case of middle cerebral artery occlusion.

Our two cases clearly had catastrophic intracerebral haemorrhage with extension into the lateral ventricles as shown on the C-T scan of the brain. Furthermore, case 1 had headache, localised convulsion and hemiparesis which occurred 3 days before the massive haemorrhage and the hemiparesis resolved 9 hours later. Case 2 had episodic convulsions and fluctuating level of consciousness in the preceding 9 hours of the massive bleed. Therefore, it would appear that there might be 'smaller' haemorrhages or even thrombo-embolic phenomenon before the massive haemorrhage.

Hypervolaemia during blood transfusion did not seem to be a predisposing factor, for the intracranial haemorrhage occurred days later after the transfusion. Hypertension was episodic and probably occurred secondarily to the intracranial haemorrhage rather than causing the haemorrhage.

Bleeding and coagulation abnormalities are likely to predispose beta-thalassaemia major patients to intracranial haemorrhage.

Both our cases had low platelet count although their bleeding time was still within normal limit. Case 1 had prolonged prothrombin time and both cases had prolonged partial thromboplastin time. Caocci³ studied the bleeding and coagulation profile in 30 beta-

thalassaemia major patients. The bleeding time, platelet count, prothrombin time and partial thromboplastin time showed minor variations in his patients. The vitamin-K dependent clotting factors were slightly reduced due to hepatic impairment. However, clotting factors XI and XII were markedly reduced, probably secondary to activation of intrinsic coagulation following intravascular haemolysis and multiple blood transfusion.

The fatal intracranial haemorrhage occurring in beta-thalassaemia major is probably multi-factorial in origin. For the 2 cases, the predisposing factors included low platelet count secondary to hypersplenism, and reduced clotting factors with resultant prolonged prothrombin time and partial thromboplastin time. The combination of factors leading to intracranial haemorrhage may be different for each patient. Thus it may be difficult to predict which patient may be predisposed to intracranial haemorrhage.

However, the trigger factor for the intracranial haemorrhage was most likely to be due to the recent blood transfusion. On reviewing the case reports in the literature, many of these patients had two or more blood transfusions within the week of the haemorrhage. Therefore, it might be advisable to transfuse not more than 20 mls of packed cells per kg for each admission, and not more than once a week (with the exception of those with heart failure secondary to anaemia).

Fatal intracranial haemorrhage occurred in two beta-thalassaemia major patients a few days after blood transfusion. A combination of factors including low platelet count and reduced clotting factor predisposed these patients to intracranial haemorrhage. Presently, it may seem difficult to predict and prevent intracranial haemorrhage in beta-thalassaemia patients and further studies need to be done. However, multiple blood transfusion within a week should probably be avoided.

Acknowledgement

I would like to thank the Director-General of Health, Malaysia for permission to publish this article.

References

1. Wasi P, Pootrakul, Piankijagum A. A syndrome of hypertension, convulsion and cerebral haemorrhage in thalassaemia patients after multiple blood transfusion. *Lancet* 1978;2 : 602-4.
2. Michaeli J, Mittelman M, Grisaru D. Thromboembolic complications in beta thalassaemia major. *Acta Haemat* 1992; 87 : 71-4.
3. Caocci L, Alberti M, Burrat P. Screening coagulation tests and clotting factors in homozygous beta-thalassaemia. *Acta Haemat* 1978;60 : 358-64.