

MRI Findings in Failed Back Surgery Syndrome

Y F Fan, FRCR

V F H Chong, FRCR

*Department of Diagnostic Radiology,
Singapore General Hospital, Outram Road, Singapore*

Summary

The failed back surgery syndrome (FBSS) is a difficult diagnostic problem both clinically and radiologically. Forty-three patients were evaluated prospectively with magnetic resonance imaging (MRI) and forty-five scans were obtained. Fifteen patients (33%) showed recurrent disc prolapse; 15 (33%) patients postoperative epidural fibrosis; 8 (18%) both recurrent disc prolapse and epidural scarring; 4 (9%) patients spinal stenosis, 2 whom also had both epidural fibrosis and recurrent disc prolapse; 2 (4%) normal scans; 2 (4%) patients arachnoiditis and 1 (2%) patient postoperative pseudomeningocele formation. Gadolinium-diethylenetriaminepenta-acetic acid (Gd-DTPA)-enhanced MRI was particularly helpful in differentiating recurrent disc prolapse and epidural fibrosis. Surgical findings in 11 patients were available. MRI correctly predicted recurrent disc prolapse in 6 patients, epidural fibrosis in 4 patients and spinal stenosis in 1 patient illustrating the value of this modality in the evaluation of FBSS.

Key Words: Gadolinium, Pseudomeningocele, Epidural fibrosis, Recurrent disc prolapse, Arachnoiditis

Introduction

Failed back surgery syndrome (FBSS) refers to pain and functional incapacitation of varying degrees following spinal surgery for low back pain. The reported frequency is 10%-40%¹. There are many causes of FBSS and they include recurrent disc prolapse, postoperative epidural fibrosis, spinal stenosis, pseudomeningocele formation, arachnoiditis, mechanical instability after laminectomy, nerve injury and even wrong level surgery. The two commonest causes by far are recurrent disc prolapse and epidural fibrosis or a combination of both. Gd-DTPA enhanced MRI is particularly valuable in differentiating disc and scar²⁻⁵. This prospective study describes the various abnormalities seen in the postoperative spine and how they may be recognised on MRI.

Patients and Method

Forty-three consecutive patients with previous lumbar spine surgery were included in this prospective study.

The initial indication for spinal surgery was disc prolapse. A total of 45 scans were performed and two patients were scanned twice. There were 24 (59%) males and 19 (41%) females. The average age of male patients was 39.7 years (range 20-52 years) and females 43.9 years (range 20-78 years). The average age of all patients was 41.6 years.

The examinations were performed on a 1.0 tesla superconducting magnet (Siemens Magnetom Impact) using a 28cm oval surface coil. The patients were examined with the following protocol initially: a) sagittal spin echo (SE) T1-weighted (500/15; repetition time [TR] msec/echo time [TE]), sagittal SE T2-weighted (TR/TE 2200/80) and b) axial SE T1-weighted (TR/TE 500/15). After the injection of contrast (Magnevist 0.1 mmol/kg body weight) axial images were obtained (TR/TE 500/15). The imaging matrix was 256 x 256 with a slice thickness of 4mm and a 10% interslice gap (0.4 mm). The T1-weighted images were performed with three excitations while the

T2-weighted scans used only one excitation. The post-contrast scans were performed with minimal delay following injection of contrast to avoid possible confusion arising from delayed contrast enhancement in prolapsed discs. Surgical findings were available in 11 patients for correlation with MRI diagnosis.

Results

Fifteen patients (33%) showed recurrent disc prolapse. A diagnosis of recurrent disc is based on the presence of a soft tissue mass which appears to be in contiguity with the parent disc. When large enough space occupying effect may be seen. It should show no contrast enhancement and of low signal intensity in the T2-weighted sequence. Fig. 1a is a sagittal T1-weighted image showing a soft tissue lesion in contiguity with the L4/L5 intervertebral disc causing slight impingement of the thecal sac. In the axial T1-

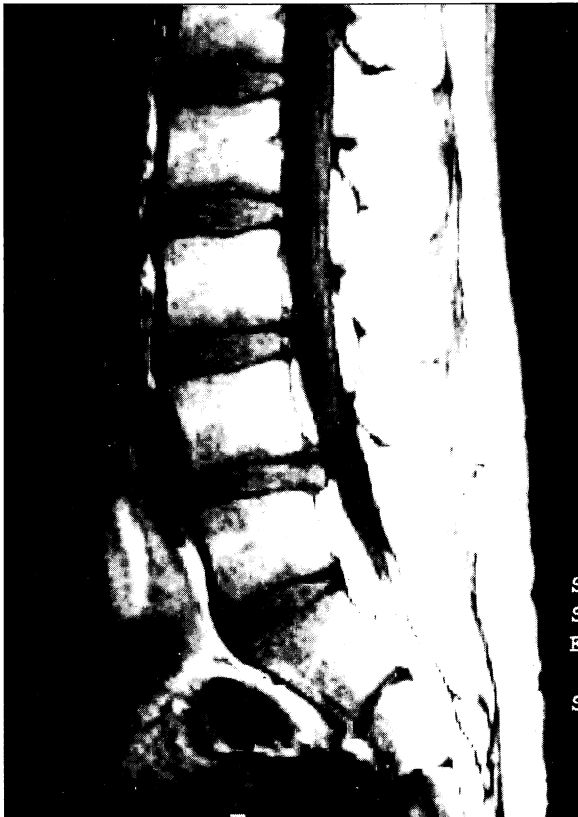

Fig. 1a: Sagittal T1-weighted image showing a soft tissue lesion impinging the thecal sac at L4/L5

weighted image (Fig. 1b), the lesion is isointense with disc. In the post-contrast examination (not shown), no contrast enhancement is evident indicating the presence of a recurrent central disc prolapse.

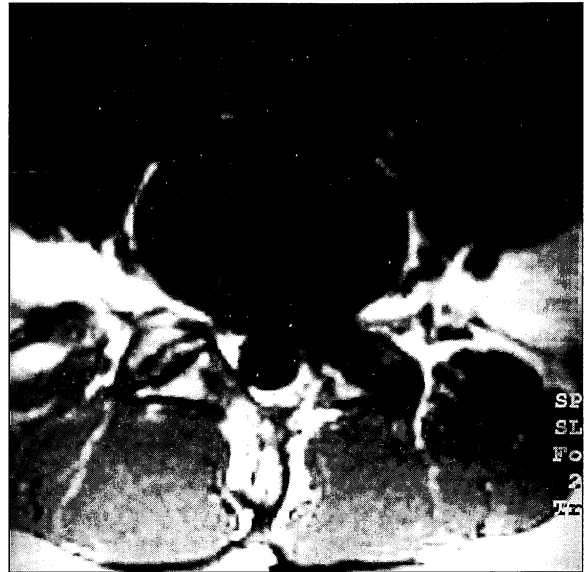


Fig. 1b: Axial T1-weighted scan illustrating a central lesion isointense with disc

Another fifteen patients (33%) had postoperative epidural fibrosis. A diagnosis of epidural scar is made in the presence of a soft tissue mass with contrast enhancement. Epidural fibrosis may or may not be associated with space occupying effect. It should also be of low signal intensity in the T2-weighted sequence. Fig. 2a is a sagittal T1-weighted image showing a lesion at L5/S1 level. In the axial T1-weighted scan (Fig. 2b), a soft tissue lesion could be identified on the left side of the spinal canal obliterating the epidural fat. In addition, the nerve root appears obscured. Following the injection of contrast (Fig. 2c), there was good contrast enhancement proving the presence of scar tissue encasing the nerve root.

Eight patients (18%) had both recurrent disc prolapse and epidural scarring. These patients show both enhancing and nonenhancing intraspinal soft tissue lesions. This diagnosis is made in the presence of a nonenhancing soft tissue mass surrounded by an enhancing lesion. Fig. 3a is an axial T1-weighted image

at level L5/S1 showing a soft tissue lesion on the left side of the spinal canal. There is effacement of the epidural fat and the spinal canal appears narrowed. After the administration of contrast (Fig. 3b), there was no enhancement in the central portion while the rest of the lesion demonstrated an increase in signal intensity. These findings are typically seen in recurrent disc prolapse with associated fibrosis.

Four patients (9%) were noted to have spinal stenosis, 2 of whom also had both epidural fibrosis and recurrent disc prolapse. Fig. 4 is an axial T1-weighted scan showing a narrowed left lateral recess as a result of facet hypertrophy. The adjacent nerve root is impinged. Note also the thickened contralateral ligamentum flavum.

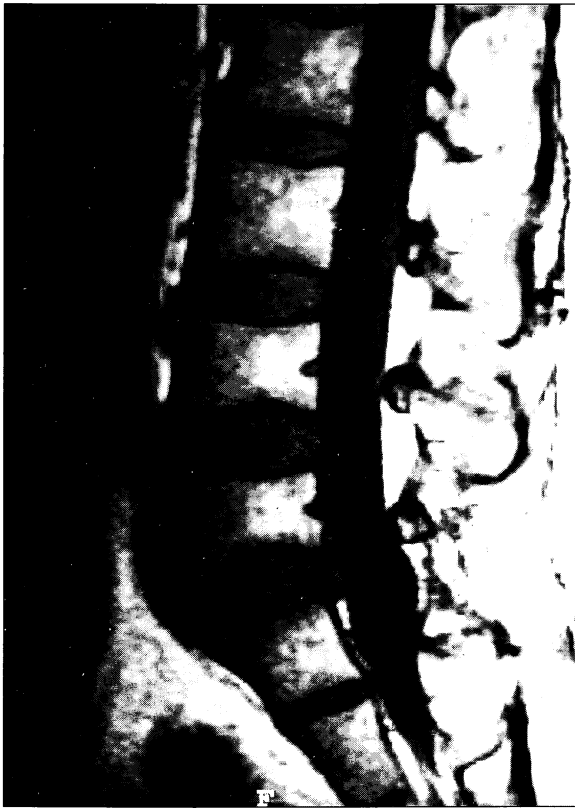

Fig. 2a: Sagittal T1-weighted image demonstrating a lesion in contiguity with the L5/S1 disc causing slight displacement of the thecal sac

Two patients demonstrated features of postoperative arachnoiditis with clumping of the nerve roots centrally within the thecal sac.

In one (2%) patient an epidural cystic lesion could be identified posteriorly from T11 down to L2. The

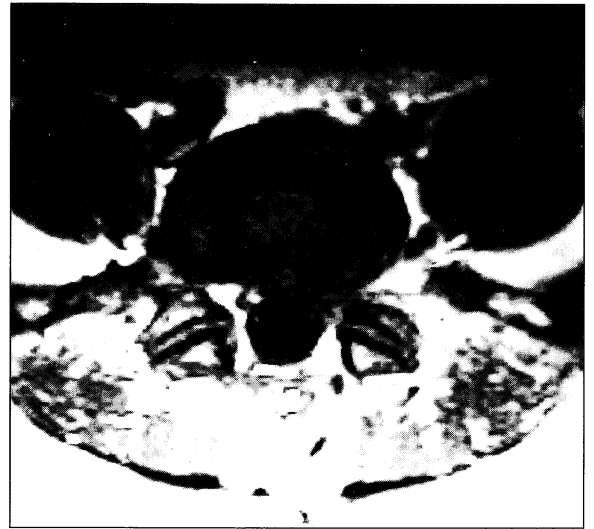


Fig. 2b: Axial T1-weighted scan shows the lesion on the left side of the spinal canal

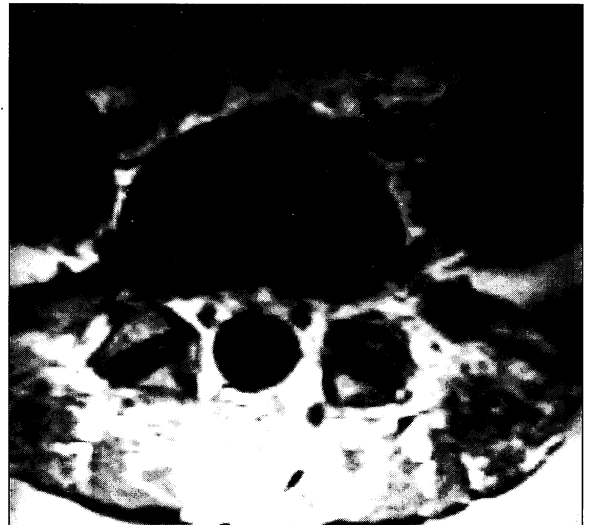


Fig. 2c: Post contrast scan illustrating contrast enhancement of scar tissue encasing the nerve root

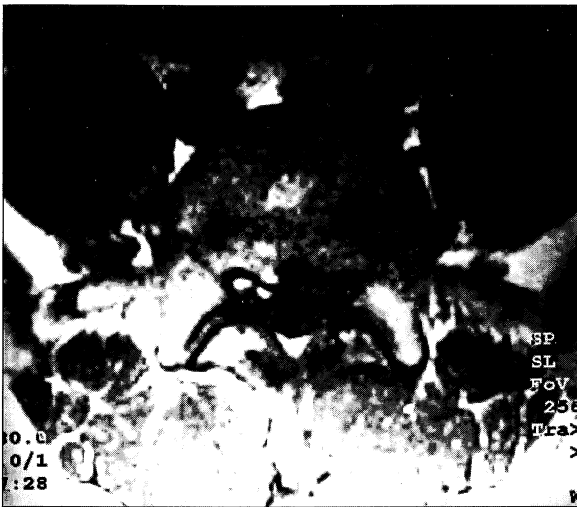

Fig. 3a: Axial T1-weighted scan showing a lesion effacing the epidural fat on the left side of the spinal canal

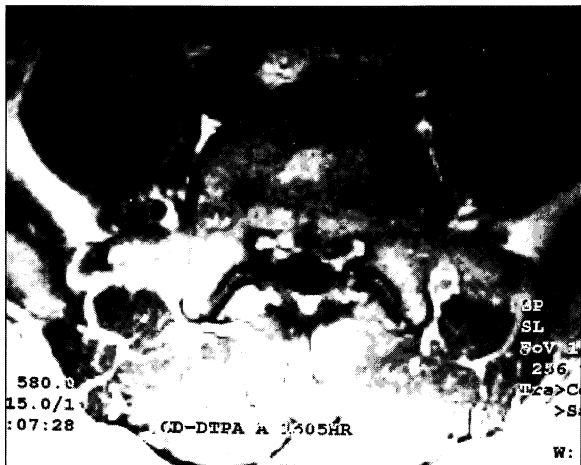

Fig. 3b: Axial contrast enhanced scan demonstrating a nonenhancing disc with surrounding enhancing scar tissue

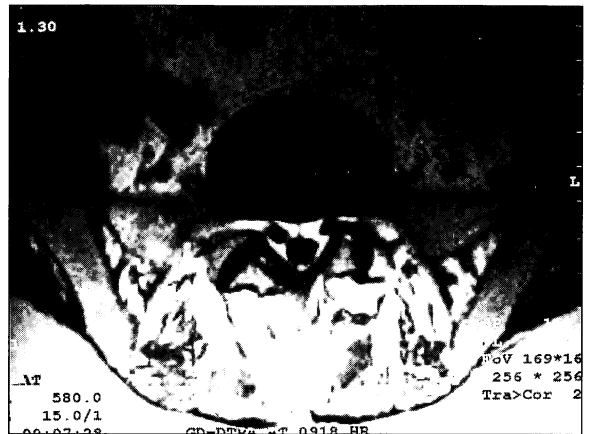


Fig. 4: Axial T1-weighted scan showing narrowing of the left lateral recess. Note the facet hypertrophy and impingement of the adjacent nerve root

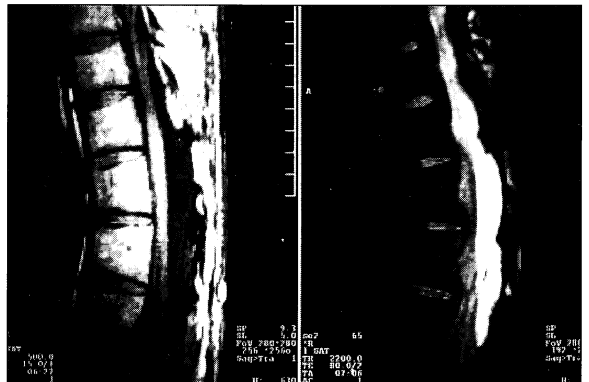

Fig. 5a & b: Sagittal T1-weighted image showing a low signal lesion at the thoracolumbar junction posteriorly. The T2-weighted scan shows high signal intensity indicating a cystic lesion

patient had a previous operation 12 years ago at L2/L3 for disc prolapse. There was no previous mention of such a cystic lesion prior to surgery and no previous films were available for correlation. Although the cystic lesion may have been overlooked in the preoperative evaluation, this observation could be a case of an unusual postoperative pseudomeningocele. Fig. 5a and 5b are sagittal T1 and T2-weighted scans showing a

cystic lesion located in the thoracolumbar epidural space posteriorly. In the axial T1-weighted scan a low signal intensity lesion posterior to the thecal sac with no contrast enhancement was noted. The high signal on the T2 sequence with no enhancement in the T1 sequence after Gd-DTPA injection indicate the presence of a cystic structure such as a cerebrospinal fluid (CSF) collection.

Two (4%) patients in spite of severe symptoms showed normal scans and the cause of pain was not elucidated by the MRI scans.

Eleven patients were re-operated. Surgery confirmed the preoperative diagnosis of recurrent disc prolapse in 6 patients, epidural fibrosis in 4 and facet joint hypertrophy with impingement of nerve root in 1 patient. No false positive or false negative diagnosis was encountered in this small series of patients with operative correlation.

Discussion

The failed back surgery syndrome is a common clinical disorder. The recurrence of backache or the failure of pain relief after surgery is distressing to both the patient and the surgeon concerned. Before the introduction of computed tomography and magnetic resonance imaging, the differentiation between recurrent disc prolapse and epidural fibrosis was difficult. Although high dose contrast enhanced CT scan showed promising results with published accuracy between 67% and 100%^{6,7}, this technique did not gain universal acceptance.

Both CT and MR differentiation between disc and fibrosis is based on the vascularity of the tissues concerned^{8,9}. The increased vascularity within scar tissue is reflected by contrast enhancement. On the other hand intervertebral disc is relatively avascular and therefore contrast enhancement is not expected. However, disc prolapse may show peripheral irregular enhancement as a result of disc being wrapped in scar tissue⁴. In addition, disc may show a variable amount of enhancement in delayed scans (greater than 30 minutes post contrast infusion). This is the result of contrast diffusion from adjacent vascularised tissues into the capacious extracellular spaces of the relatively avascular disc. It is, therefore, mandatory to scan the patient as soon as possible after the administration of contrast to avoid possible confusion. All our patients had their post-contrast scans started within 2 minutes following contrast injection.

Scar tissue enhancement may be seen in patients whose surgery have taken place more than 20 year ago⁵. The peak enhancement of scar tissue is 5-6 minutes after

contrast injection. Hence, early scanning for accurate diagnosis is mandatory especially when disc is known to enhance in delayed scans. Although scar is generally believed to demonstrate retraction, a space occupying effect (akin to keloid formation) is often noted. Space occupying effect per se, therefore, should not be used as a major discriminator of disc and scar^{4,6,7}.

Recurrent disc prolapse and epidural fibrosis may coexist and they are not mutually exclusive. This coexistence may be demonstrated by the combination of enhancement characteristics of disc and scar. This is not an uncommon finding and may be seen in up to 55% of cases⁴. In our series 18% of the patients belong to this category. Not all scar tissue is secondary to surgery. It is known that a prolapsed disc may incite fibrosis in the absence of surgery. Hence, the scarring noted in conjunction with recurrent disc prolapse may be a response to the presence of disc material rather than the result of surgical trauma.

In a study of 44 patients by Hueftle *et al*⁴, Gd-DTPA enhanced MRI showed 96% accuracy in differentiating epidural fibrosis from recurrent disc prolapse. The results of our initial experience is most encouraging. The number of surgically proven cases in our series are small (n=11) and a 100% diagnostic accuracy does seem disturbing. These results, however, do indicate the tremendous value of contrast enhanced MRI in the differentiation of recurrent disc prolapse and scarring.

In patients who fail to gain symptomatic relief from disc surgery, spinal stenosis may be the cause of pain. Up to 60% of patients have lateral bony stenosis implicated as a cause of FBSS¹. Another cause of stenosis is the upward migration of the superior articulating facet (with resultant narrowing of the intervertebral foramen) secondary to loss of height after discectomy. The patient illustrated in Fig. 3 is an example of initial back pain attributed to intervertebral disc disease. Laminectomy was performed at levels L3/L4 and L4/L5 but the patient continued to experience low backache with subsequent development of left S1 root sign. He was reoperated and the left S1 root appeared stretched by the hypertrophied superior articulating facet of L5. There was tremendous improvement after surgery.

The aetiology of arachnoiditis is diverse and include trauma secondary to surgery, infection, nontraumatic subarachnoid haemorrhage, intraspinal anaesthetic agents, reaction to intraspinal contrast media and detergents in syringes used to introduce these substances. Arachnoiditis may cause persistent pain following surgery in 6%-16% of patients¹⁰. In the initial phase of the pathogenesis of postoperative arachnoiditis, fibrinous exudates are present with few cellular infiltrates. The fibrincovered nerve roots adhere to each other and to the wall of the thecal sac. During the subsequent repair stage dense collagenous tissue form producing a mass like lesion.

MR features of postoperative arachnoiditis have been described^{11,12}. They can be categorised into three types: type 1 demonstrates clumping of nerve roots in the centre of the thecal sac; type 2 shows thickened nerve roots adherent to the wall of the thecal sac, and type 3 consists of soft tissue masses occupying the subarachnoid space. Arachnoiditis shows variable contrast enhancement. In our patients, arachnoiditis showed the type 1 pattern and they did not demonstrate significant contrast enhancement.

References

- Burton CV, Kirkaldy-Willis WH, Yong-Hing K, Heithoff KB. Causes of failure of surgery on the lumbar spine. *Clin Orthop* 1981;157 : 191-9.
- Bundschuh CV, Modic MT, Ross JS, Masaryk TJ, Bohlman H. Epidural fibrosis and recurrent disc herniation in the lumbar spine: assessment with magnetic resonance. *AJNR* 1988;9 : 169-78.
- Ross JS, Masaryk TJ, Modic MT, Bohlman H, Delamarter R, Wilber G. Lumbar spine: postoperative assessment with surface coil MR imaging. *Radiology* 1987;164 : 851-60.
- Hueftle MG, Modic MT, Ross JS, Masaryk TJ, Carter JR, Wilber RG *et al*. Lumbar spine: postoperative MR imaging with Gd-DTPA. *Radiology* 1988;167 : 817-24.
- Ross JS, Modic MT. Current assessment of degenerative disease with magnetic resonance imaging. *Clin Orthop* 1992;279 : 68-81.
- Teplick JG, Haskin ME. Computed tomography of the postoperative lumbar spine. *AJR* 1983;141 : 865-84.
- Braun IF, Hoffman JC, Davis PC, Landman JA, Tindall GT. Contrast enhancement in CT differentiation between recurrent disk herniation and postoperative scar: prospective study. *AJNR* 1985; 6: 607-12.
- Schubiger O, Valvanis A. CT differentiation between recurrent disc herniation and postoperative scar formation: the value of contrast enhancement. *Neuroradiology* 1982;22 : 251-4.
- Weiss T, Treish J, Kazner E, Kohler D, Collmann H, Claussen C. CT of the postoperative lumbar spine: the value of intravenous contrast. *Neuroradiology* 1986;28 : 241-5.
- Jorgensen J, Hansen PH, Steenskov V, Ovesen N. A clinical and radiological study of lower spinal arachnoiditis. *Neuroradiology* 1975;9 : 139-44.
- Ross JS, Masaryk TJ, Modic MT. MR imaging of lumbar arachnoiditis. *AJR* 1987;8 : 885-92.
- Monajati A, Wayne WS, Rauschnig W, Ekholm SE. MR of the cauda equina. *AJNR* 1987;8 : 893-900.
- Teplick JG, Peyster RG, Teplick S, *et al*. CT identification of post laminectomy pseudomeningocele. *AJNR* 1983;4 : 179-82.

A pseudomeningocele is due to a dural tear caused by surgery. The cerebrospinal fluid (CSF) collection may be formed as the arachnoid herniates through the defect and proliferates into an arachnoid pouch. Alternatively CSF may accumulate in the soft tissues with subsequent development of a fibrous capsule¹³. Symptomatic compression as a result of the fluid collection may occur resulting in a failed back surgery syndrome.

Mechanical instability including facet subluxation or spondylolisthesis and pseudoarthrosis as a result surgery is often difficult to evaluate with MR. In this respect, plain films or CT are better suited for demonstration of bony abnormalities.

Conclusion

Before the advent of MRI and the introduction of paramagnetic contrast media, the postoperative lumbar spine was a difficult area to evaluate. Gd-DTPA enhanced MRI is an extremely useful method of studying failed back surgery syndrome. It can accurately diagnose recurrent disc prolapse, epidural fibrosis or a combination of both by their characteristic contrast enhancement pattern. It is now the modality of choice in the evaluation of the post operative spine.