

# Herpes Gestationis: One of the Rare Skin Lesions in Pregnancy

K Naganathan, MRCP

S A R Doi, MBBS

H Jamiyah, M.Med\*

*Departments of Medicine, and \*Obstetrics,  
Faculty of Medicine, University of Malaya, 59100 Kuala Lumpur*

## Summary

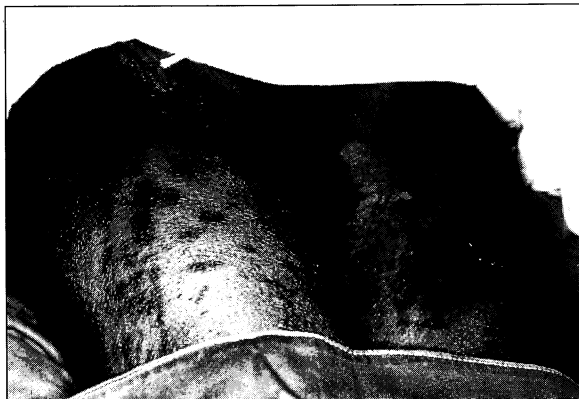Herpes gestationis is a rare disease in pregnancy. A 35-year-old G3P2 presented during her third trimester with erythematous pruritic papular eruptions. Direct immunofluorescence of a skin biopsy confirmed the diagnosis of herpes gestationis. The patient responded well to prednisolone treatment.

**Key Words:** Herpes gestationis

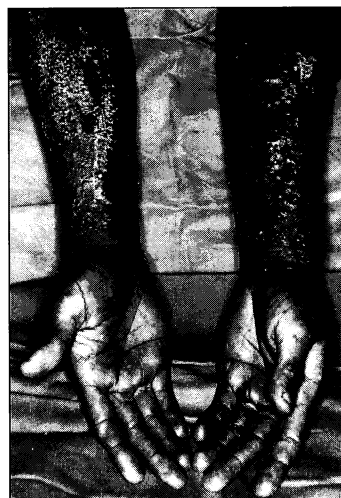## Introduction

Herpes Gestationis (HG) as a name is a misnomer as it is in no way related to the herpes virus. It is characterised by pruritic clear-fluid filled blisters which arise on normal looking or erythematous skin or at the periphery of areas of frank urticaria (Figs. 1 & 2).

The initial lesions are erythematous or oedematous papules, vesicles or urticarial plaques. The distribution of the lesion is widespread and symmetric. As these lesions progress they develop erosions and crusts. The diagnosis of HG is based on the demonstration of linear deposits of the third component of complement along the basement membrane zone (BMZ) of normal

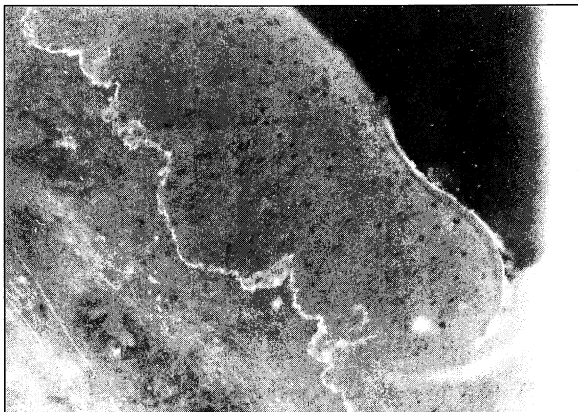


**Fig. 1:** Erythematous papules and areas of frank urticaria on the thighs of the patient with Herpes Gestationis. Skin biopsy site is noted

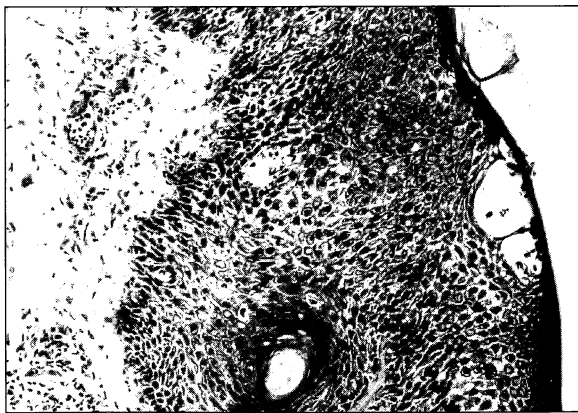


**Fig. 2:** Grouped erythematous papules and vesicles on the upper limbs of the patient with Herpes Gestationis

or peri-lesional skin, a finding crucial for the diagnosis of HG (Fig. 3). Such depositions may persist for several months to a year after skin lesions have cleared. Light microscopy findings are indistinguishable from that of bullous pemphigoid with the initial lesion being the formation of subepidermal blisters in association with eosinophils within the blister cavity as well as marked oedema of dermal papillae and spongiosis of hyperplastic epidermis (Fig. 4).



**Fig. 3: Linear deposition of C3 along the basement membrane zone in Herpes Gestationis by direct immunofluorescence**



**Fig. 4: Subepidermal vesicle formation and edema of dermal papilla in Herpes Gestationis with infiltrates of eosinophils, histiocytes and lymphocytes**

### Case Report

KK was a 35-year-old G3P2 who presented with an intensely pruritic eruption at the end of the seventh month of her third pregnancy. The lesions began on the abdomen as erythematous pruritic papular eruptions (Fig. 1) and over the next 24 hours spread to her limbs and trunk. This was her first episode of such a rash. The lesions began to form vesicles (Fig. 2) soon after the onset of the rash and she presented to the hospital four days after the onset of the skin lesions. Her past obstetric history consisted of two Caesarean sections for suspected cephalo-pelvic disproportion in 1982 and a footling breech presentation in 1984. All children were alive and well. She has had no family history of a similar problem and has been married 11 years. She is not hypertensive or diabetic although she has a positive family history for both.

On arrival in hospital, skin scrapings taken from the lesions to identify the Herpes virus were negative. A diagnosis of herpes gestationis was made clinically by the dermatologist and a skin biopsy was done after which the patient was started on prednisolone at 60mg/day. On the fourth day, the diagnosis was confirmed by direct immunofluorescence of peri-lesional skin which showed C3 deposited along the BMZ (Fig. 3). Other laboratory studies disclosed a haemoglobin of 143g/L and WBC count of 20,300/ $\mu$ L with 77% polymorphs, 10% lymphocytes, 6% eosinophils and 3% monocytes. Urinalysis was negative and the RPR and HBsAg were negative. She was blood group O+ve. Serum complement fixing antibodies (HG factor) were negative in maternal serum by an indirect immunofluorescent technique. Over the next few days of treatment no new lesions appeared, and vesicular lesions had also subsided with a marked relief of pruritus. She was discharged on the eighth day with prednisolone tapered down to 30mg/day. The skin lesions had almost completely resolved. She was to return after one week but presented five days later with labour pains. A Caesarean section was done a few hours post admission and she delivered a 2kg male child who had no skin lesions. On the first post-delivery day she re-developed papular erythematous plaques over her anterior chest and back. The prednisolone was increased to 40mg/day. On her 7th

post-delivery day, skin lesions had improved, vesicles were absent and itch was markedly less, although she still had erythematous papules and areas of frank urticaria. She was discharged with a follow-up appointment at the skin clinic in two weeks on tapering doses of prednisolone.

### Discussion

Herpes Gestationis (HG) is a rare pruritic vesiculobullous disease of pregnancy with an approximate incidence of 1 per 50,000 births in the Caucasian population<sup>1</sup>. It has never been reported to be associated with systemic manifestations nor does it adversely affect maternal prognosis. It is most common in the second and third trimesters of pregnancy<sup>1,2</sup> and has a distinct tendency to recur in subsequent pregnancies with or without post-partum exacerbations. In some, successive pregnancies are associated with an earlier onset and greater severity of the disease. HG can be dramatically alleviated by corticosteroids, usually prednisolone in a dosage of 20-40mg/day<sup>2</sup>.

Corticosteroids is the mainstay of therapy, and the response is within 24 hours of onset of treatment by a marked reduction in pruritus and suppression of formation of new lesions. In milder cases topical therapy alone may be adequate, but a few with very severe disease may also require adding on of azathioprine (100-150mg/day)<sup>2</sup>. Post-partum flare-ups usually remit completely within a few weeks after delivery but may require increased doses of prednisolone which are then tapered gradually. Other cutaneous lesions resembling HG noted in the newborn are usually transient and require no therapy. Therapy in most cases of HG does not affect the fetus<sup>3</sup> although there is a postulated possibility of fetal adrenal suppression. Fetal prognosis in cases of maternal HG is slightly worse off due to an increase in low birth weights and "small for dates"<sup>3</sup>. Good obstetric and perinatal care however usually results in a favourable outcome and infant mortality in most series is usually due to coincidental problems unrelated to HG. The administration of corticosteroids in pregnancy has not been reported to adversely affect fetal outcome<sup>3</sup>.

### References

1. Shornick JK, Bangert JL, Freeman RG, Gilliam JN. Herpes gestationis: Clinical and histological features of 28 cases. *J Am Acad Dermatol* 1983;8 : 214.
2. Lawley TJ, Stingl G, Katz SI. Fetal and maternal risk factors in herpes gestationis. *Arch Dermatol* 1978;114 : 552-5.
3. Holmes RC, Black MM. The fetal prognosis in pemphigoid gestationis (herpes gestationis). *Br J Dermatol*, 1984;110 : 67-72.