

Identification from Dental Characteristics

N Phrabhakaran, M.Sc. Dentistry
Dean's office, Faculty of Dentistry,
University of Malaya, 59100 Kuala Lumpur

Summary

Law enforcing authorities need to provide a scientific basis for the identification of any unknown individual. In recent years, dental records comparison has developed into one such credible method of confirming the identity of a deceased. This method is however restricted as dentists are not making and maintaining adequate records of their patients. Fortunately the advent of inexpensive cameras and print processing procedures has enabled the availability of ample antemortem photographs. Photographs in which a person expresses his/her teeth 'gleefully' has provided a sound scientific basis for the identification by comparing dental characteristics of the deceased.

Key Words: Dental characteristics for identification, Forensic medicine

Introduction

Teeth are the hardest tissue in the human body. They undergo various destruction during a person's lifetime but have excellent postmortem preservation. In addition, they can withstand extreme heat, cold and chemical destruction. Teeth also provide certain useful information concerning the identification of an unknown person. For example, the age, race, oral hygiene habits, occupation and diet can be determined from them. The enamel portion of the teeth is ectodermal in origin and it provides a unique shape which is categorically characteristic to the individual. It is not surprising that the chances of two individuals having the same dentition has been computed to be 1 in 2.5 billion in occurrence¹. Even identical twins do not have the same dentition². Furthermore, the individuality of the dentition is further augmented when there are spacing, rotation, malalignment and missing teeth. Fractures, stains and restorations placed on them adds further to their uniqueness.

In general, the useful methods of identification of unknown bodies performed by forensic scientists are as follows:

- a) comparison with existing dental records.
- b) comparison of dental characteristics from antemortem photographs.
- c) craniofacial superimposition³.
- d) facial reconstruction.

The last two methods requires elaborate equipments and is very time consuming. It may not be appreciated by the immediate relatives of the deceased as the skull has to be specially treated before the investigation is carried out.

In the following cases, dental records were not available for comparison but adequate number of antemortem photographs of the deceased were available for useful comparison.

Case Report 1 (Fig 1a and 1b)

On December 1992 a charred body was recovered from a hotel room in Johor Bahru by firemen. Following investigations, the police arrested a foreigner in connection with the immolation of his wife. Although the deceased had dental restorations, a search for her dental records was futile. A search amongst the number of photographs provided by the family, a

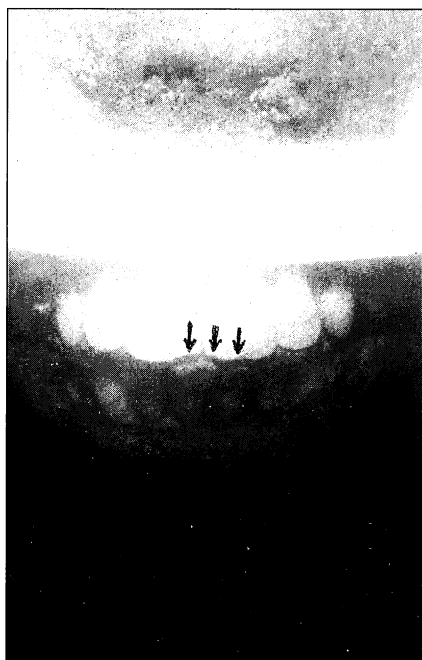


Fig. 1a Characteristic features found on the anterior dentition of the deceased person.

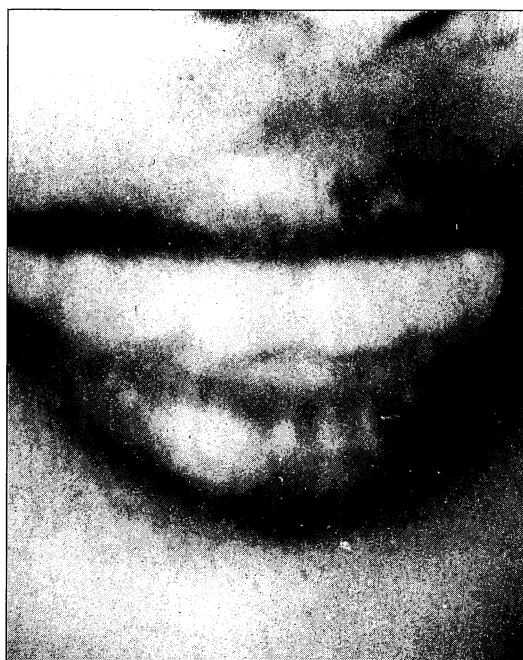


Fig. 1b Corresponding features found on the dentition of the foreigner's wife. The photograph has been enlarged to demonstrate the unique features.

good photograph of the deceased 'smiling' was selected. Certain characteristics on the upper central incisors were particularly peculiar to the missing person.

- a) The mesioincisal angles of both the central incisors were chipped.
- b) A distinctive notch was observed on the incisal edge of the upper left central incisor.

These findings corresponded to the teeth of the deceased and were particularly unique. Furthermore, the shape, arrangement and the axial alignment of the other upper anterior teeth were also consistent and these observations confirm the identity of the deceased as indeed the wife of the foreigner.

Case Report 2 (Fig. 2a & Fig. 2b)

On May 1993, a very decomposed body was discovered in an oil palm estate near Batu Pahat. At

the same period, a young Malay factory girl was reported missing by her relatives. Although personal effects of the deceased were recovered at the site of the discovery, the police requested for a more scientific basis of her identification.

Close examination of the skull, jaws and teeth revealed that twelve teeth were missing postmortem from the body. Further search at the site of discovery of the body was organized and five more teeth were subsequently recovered. These teeth were reattached into their appropriate sockets and relevant photographs taken. It was observed that the deceased had spacing distal to the right lateral incisor and a similar spacing distal to the lower canine. These spacing which are not present in an ideal dentition were particularly unique for the deceased. These dental evidence corresponded with the observed dental characteristics from the antemortem photograph of the deceased. Therefore these findings were sufficient to support the identification of the missing Malay girl.

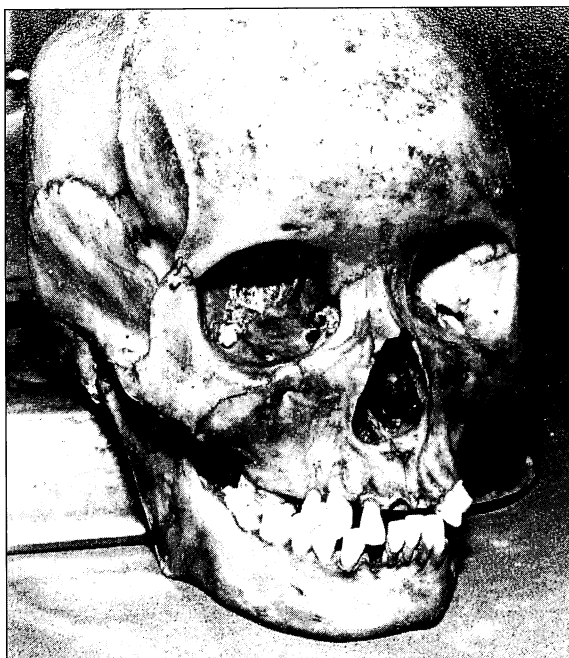

Fig. 2a Characteristic spacing distal to the right upper lateral incisor and the lower canine. The other front teeth have been lost postmortem and not recovered at the site of discovery of the body.

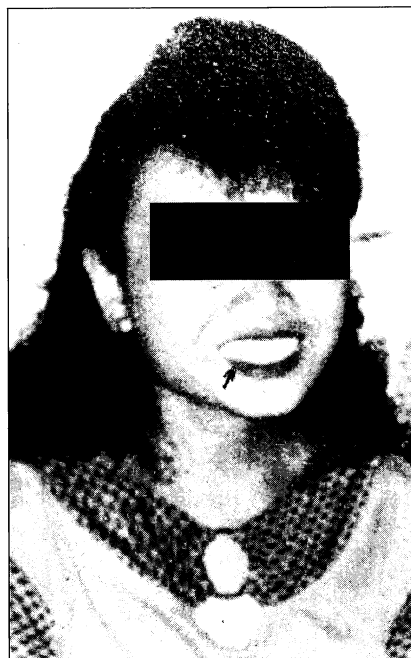

Fig. 2b Corresponding spacing observed in the dentition.

Discussion

Teeth are not only functionally and aesthetically important but also helps in the identification of unknown deceased persons. Their usefulness in identification becomes satisfactory only if they are intact. Great caution must be exercised in order to interpret the dental evidence accurately. Instances when they are badly incinerated, mutilated or even lost, their use for comparison becomes limited. Furthermore, antemortem photographs must be of good quality and

have the deceased in 'smiling' situations to reveal the boundaries of the teeth. If the deceased has very low lip line, the exposure of the teeth becomes limited.

Although this method of comparison has its limitations, its usefulness cannot be ignored altogether. It is necessary that whoever interprets the comparison, should have a sound knowledge of the morphology of the anterior teeth. It provides a simple valid method which can be advocated to confirm, support or to exclude an identification.

References

1. Berndt T. Forensic dentistry's hottest frontier. *Flo Dent J* 1982;53 : 22-43.
2. Sognnaes RF, Rawson RD, Gratt BM, Nguyen NB. Computer comparison of bitemark patterns in identical twins. *J Am Dent Assoc* 1982;105 : 449-51.
3. Brown KA. Developments in craniofacial superimposition for identification. *J For Odonto-Stomato* 1983;1 : 57-64.