

# Patterns of Superficial Veins of the Cubital Fossa in Malays

A S Dharap, MS

M Y Shaharuddin

School of Medical Sciences, Universiti Sains Malaysia,  
16150 Kubang Kerian, Kelantan

## Summary

Patterns of superficial veins of the cubital fossa were studied in 170 male and 96 female Malays. Six venous patterns were observed. The less commonly known but clinically important patterns observed included absence of communication between basilic and cephalic veins (in 7.3% females and 8.8% males); an arched median cubital vein (in 2.0% females and 6.5% males); absence of the cephalic vein (in 1.0% females and 2.9% males) and two median cubital veins (in 1 male only). Awareness of these uncommon cubital venous patterns and their approximate incidence would be very useful for those performing venepuncture or venesection in Malays, especially under emergency conditions.

**Key Words:** Patterns, Superficial veins, Cubital fossa, Malays

## Introduction

Superficial veins of the cubital fossa are commonly used for blood sampling and transfusion and for intravenous injections, often under conditions of emergency<sup>1</sup>. Cubital veins are also used for the introduction of cardiac catheters to obtain blood samples from cardiac chambers and for cardio-angiography.

The arrangement of the superficial veins in the cubital fossa, however, is subject to considerable variation<sup>2-4</sup>. Different patterns of superficial cubital veins and their percentages of occurrence have been reported in various races<sup>5-8</sup>.

We planned this prospective study in Malays since (i) the superficial veins in the cubital fossa are important clinically, (ii) their arrangement is subject to racial variation, (iii) we were unable to find any report in available literature, describing superficial cubital venous patterns in Malays, and (iv) it would be informative to compare the venous patterns in Malays with those reported in other races.

## Materials and Method

In this study 170 males and 96 females were randomly selected from among the staff and students of the Universiti Sains Malaysia's School of Medical Sciences in Kelantan, Malaysia. All subjects were Malays, were 18 years and more in age, and were free from any obvious vascular diseases. After taking the subject's consent, the superficial veins of the cubital fossa were made prominent by applying a tourniquet about 10 cm proximal to the crease at the elbow and by active movements of the forearm. The veins were marked on the skin and the pattern of veins in each case was accurately drawn on a sheet of paper which was identified with the name, sex and age of the subject; venous patterns on the right and left sides were noted separately. Small veins were ignored. All the drawings obtained were carefully studied and analysed.

## Results

In the present study we observed six patterns of arrangement of superficial veins of the cubital fossa (Fig. 1A, B). There was no significant difference between the

venous patterns on the right and left sides in males or in females. In pattern no. 1 the median cubital vein arose from the cephalic vein a few centimetres below the elbow, joined the basilic vein a few centimetres above the level of the elbow joint and received tributaries from the front of the forearm. This pattern was more common in females (78.2%) than in males (62.4%) (Fig.1 B-1, A-1). Pattern no. 2 consisted of one median antebrachial vein branching into two in the cubital fossa with one branch ending in the basilic vein and the other branch in the cephalic vein. This pattern was more frequent in males (18.8%) than in females (11.5%) (Fig. 1 A-2, B-2). In pattern no. 3, seen in 7.3% of females and in 8.8% of males, there was no communication between the cephalic and the basilic veins (Fig. 1 B-3, A-3). In

2.0% of females and 6.5% of males, the cephalic vein and the basilic vein were connected by an arching vein, with concavity of the arch facing proximally, into which drained two or more veins from the front of the forearm (Fig. 1 B-4, A-4). This was pattern no. 4. Pattern no. 5 was found in 1% of females and in 2.9% of males and showed only the presence of the basilic vein; the cephalic vein was absent (Fig. 1 B-5, A-5). Pattern no. 6 was seen only in one male subject (0.6%); no female subject showed this pattern. Two median cubital veins were seen joining the cephalic and basilic veins. The lower of these two veins corresponded with the usual description of the median cubital vein but the upper vein was arched with the convexity of the arch facing proximally (Fig. 1 A-6, B-6).

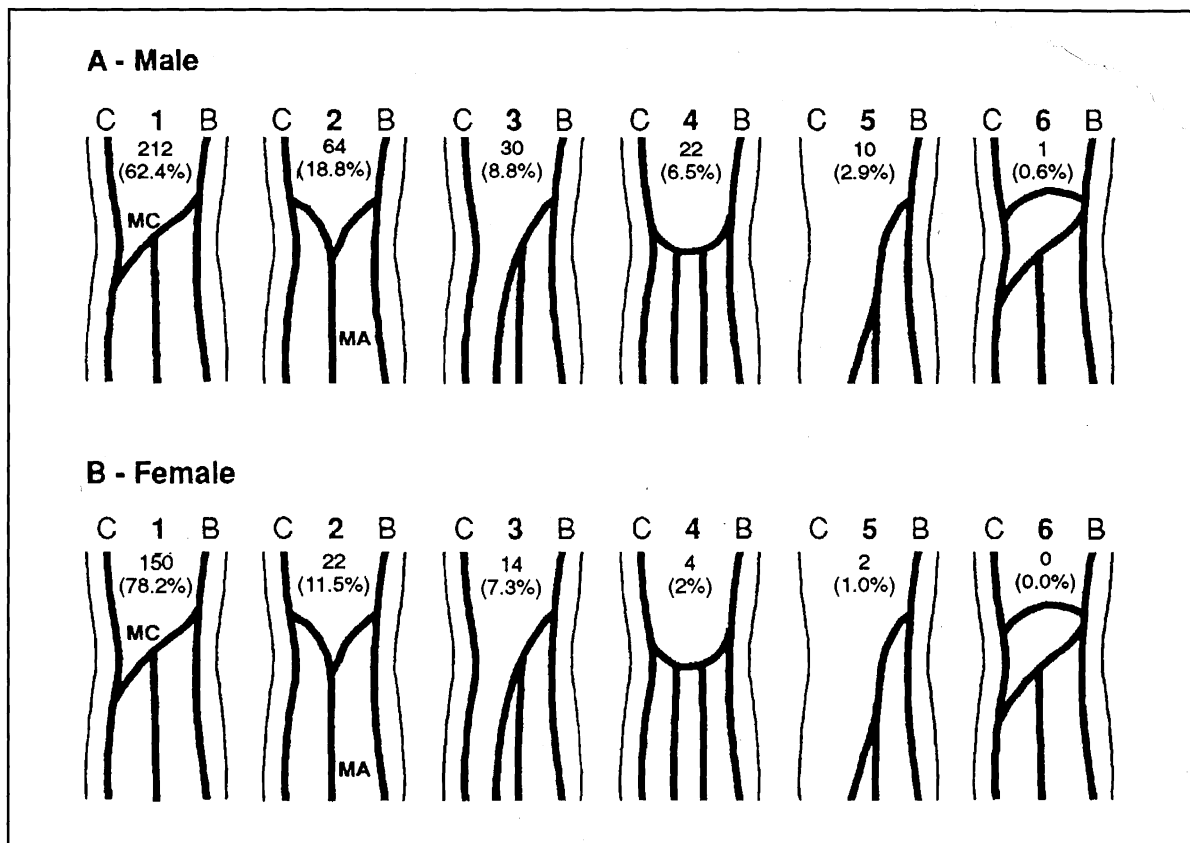


Fig. 1: Diagrams showing patterns of superficial veins of the cubital fossa in 532 upper limbs of living Malay subjects (340 male and 192 female). Numerals above the percentage values indicate the number of upper limbs showing that particular venous pattern. See text for details of description. B = Basilic vein; C = Cephalic vein; MA = Median Antebrachial vein; MC = Median cubital vein

## Discussion

Standard textbooks of anatomy<sup>2,4</sup> state that the cephalic vein runs on the lateral side and the basilic vein runs on the medial side, below the front of the elbow. The cephalic vein gives off the median cubital vein which passes upwards and medially to join the basilic vein. This was the most common arrangement seen in our study, being present in 78.2% of females and 62.4% of males. Others<sup>3</sup> mention that a single median antebrachial vein ascends in the front of the forearm and divides into median cephalic and median basilic veins which join the cephalic and basilic veins respectively. We found this pattern in 11.5% of females and in 18.8% of males. Most clinicians are aware of these two patterns.

In our study we found four other arrangements of superficial cubital veins, with which many clinicians may not be familiar. In 7.3% of females and 8.8% of males studied, the median cubital vein was absent and there was no communication between the cephalic and basilic veins. This pattern (no. 3, Fig. 1) has also been seen to have a low incidence in Americans<sup>6</sup> and in Indians<sup>8</sup> (8% and 10% respectively), with a particularly low incidence (0.7%) in Britishers<sup>5</sup>. The clinical significance of this pattern is obvious.

The next pattern (no. 4, Fig. 1) found in our study is rare and was observed in 2.5% of females and in 6.5% of males; it has so far been reported only in Nigerians<sup>7</sup> with a similar low incidence. In this pattern the cephalic and basilic vein were joined by an arched vein, with concavity of the arch facing proximally, into which

drained two or more veins from the forearm. A similar pattern (no. 6, Fig. 1) consisted of the cephalic and basilic veins being joined by two median cubital veins; the upper vein was arched while the lower one corresponded to the usual descriptions of the median cubital vein. This pattern, however, was observed in one male subject only (0.6%) but none of the females. We have been unable to find any mention of this pattern in available literature. It is important to be aware of this venous pattern as these persons have one extra vein in each cubital fossa which could conveniently be used for venepuncture or venesection.

Finally in 1% of females and in 2.9% of males in our study (pattern no. 5, Fig. 1), we were unable to see the cephalic vein and presume it was absent. This fact is important to bear in mind when repeated attempts fail to display the cephalic vein in a patient.

## Conclusion

Superficial veins in the cubital fossa, which are commonly used in many clinical procedures, show considerable racial variation. In the majority of Malays studied, the venous patterns match those commonly described in textbooks. However, some rare venous patterns were noted in this study in a small percentage of Malay subjects. An awareness of these uncommon arrangements of superficial cubital veins, such as absence of median cubital and cephalic veins and double or arched median cubital vein, and their percentages of occurrence would be important when locating veins for venepuncture or venesection in Malays, particularly in circumstances of emergency.

## References

1. Kyle J. *Pye's Surgical Handicraft*, 20th edn. Bristol: John Wright and Sons Ltd., 1977.
2. Warwick R, Williams R. *Gray's Anatomy*, 36th edn. London: Churchill Livingstone, 1980.
3. O'rahilly R. *Gardner - Gray - O'rahilly's Anatomy*, 5th edn. Philadelphia: W.B. Saunders Company, 1986.
4. Basmajian JV, Slonecker CE. *Grant's method of Anatomy*, 8th edn. Baltimore: Williams and Wilkins, 1989.
5. Berry RJ, Newton HAS. A study of the superficial veins of the superior extremity in 300 living subjects. *Anat Anz* 1908;335 : 591-601
6. Charles CM. On the arrangement of the superficial veins of the cubital fossa in American white and American negro males. *Anat Rec* 1932;54 : 9-4.
7. Singh JD. Patterns of superficial veins of the cubital fossa in Nigerian subjects. *Acta Anat* 1982;112 : 217-9.
8. Tewary SP, Singh SP, Shamer S. The arrangement of superficial veins in the cubital fossa in Indian subjects. *J Anat Soc India* 1971;20 : 99-102.