

# Beri-beri in Immigrant Workers – A Report of Three Cases

D Jeyakumar, MRCP

Medical Unit, District Hospital, Teluk Intan, Perak

## Summary

Three East Timorese immigrants presented with signs and symptoms of heart failure in early December 1992. One of them also had features of peripheral neuropathy. Another collapsed within 24 hours of admission and attempts at resuscitation failed. The other two showed dramatic response to oral thiamine therapy. An investigation into their dietary history established gross deficiency in fresh vegetables.

**Key Words:** Beri-beri, Sudden death in immigrant workers

## Introduction

Thiamine deficiency causes a high output heart failure in individuals who have adequate calorie intake and are physically active. Alternatively it can cause a spectrum of neurological disorders ranging from a mixed sensori-motor peripheral neuropathy to Wernicke's and Korsakoff's psychosis<sup>1</sup>.

Thiamine is present in fresh vegetables and is abundant in the outer layer of cereal grains. Meat is a relatively poor source of thiamine. Deficiency syndromes develop quite rapidly once an individual is put on a thiamine-free diet as the body's reserves of thiamine only last a week or two.

Beri-beri was endemic in Colonial Malaya, especially before World War Two among the immigrant labourers<sup>2,3</sup>. However, it has become distinctly uncommon since independence. This paper describes three immigrant workers who presented with beri-beri at Teluk Intan District Hospital.

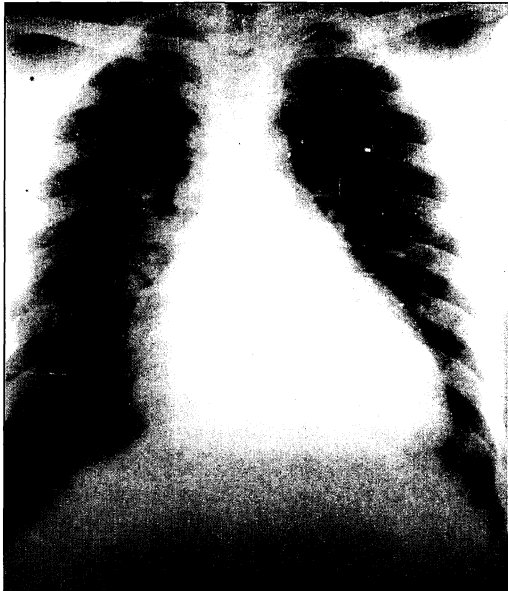
## Patient Reports

### Case 1

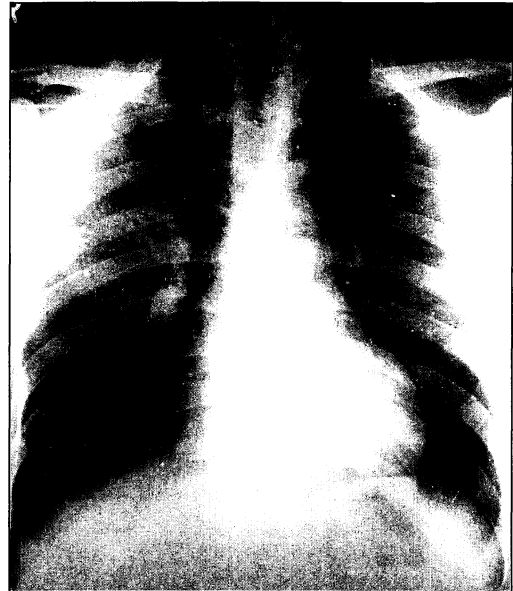
FSD, a 19-year-old East Timorese, was admitted on November 25, 1992 with a month's history of exertional dyspnoea and ankle oedema. He had no history of heart or kidney disease in the past. He had been in Malaysia for about 18 months and stayed with a group of other Indonesian workers, taking his meals at a nearby Indian-Muslim shop.

He appeared well-nourished and comfortable at rest. He had ankle oedema but no basal lung crepitations. The pulse was large-volume and a systolic murmur could be heard in the left sternal edge.

His ECG was normal except for ST depression in the inferior as well as lateral leads. There was cardiomegaly on chest X-Ray with a cardio-thoracic ratio of 16.3/26.4. A 2D-echocardiography



**Case 1: November 27, 1992**



**Case 1: December 16, 1992**

revealed a dilated but active left ventricle with a diameter of 58cm. The aortic and mitral valves appeared normal.

A diagnosis of "High Output Failure" was made and an appointment was made with the cardiologist in Universiti Kebangsaan Malaysia to establish the cause of his cardiac problem. The patient was discharged with diuretics while awaiting this date.

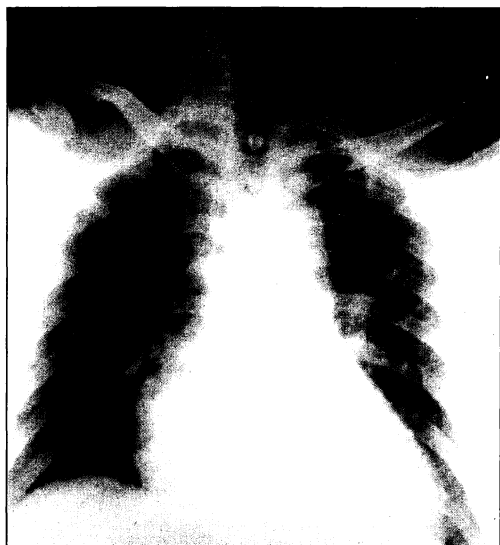
FSD was readmitted on December 9, 1992 complaining of pain and paraesthesia of both lower limbs, and progressive difficulty in walking over the previous four days. He had diminished pain sensation over the lower limbs and his Romberg's was positive. Power was reduced to 4/5 for both upper and lower limbs, and his tendon reflexes were markedly decreased. He had marked difficulty in sitting up from a lying position. Beri-beri was finally diagnosed and he was started on oral thiamine on December 11, 1992.

His cardiac symptoms resolved rapidly. A repeat chest X-Ray on December 16 showed that his cardiac-thoracic ratio had decreased from 16.3/26.4 to 12.8/24.0. The neurological symptoms took longer to resolve. On follow-up examination in mid-January 1993, he still had mild weakness of his lower limbs.

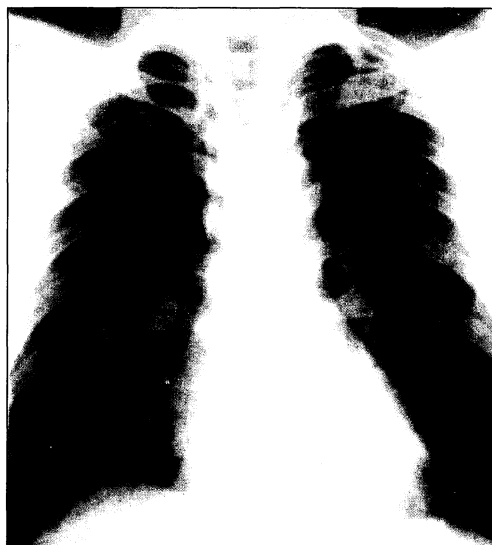## **Case 2**

FW, a 40-year-old illegal immigrant from East Timor was brought in on December 7, 1992 from the Detention Centre with a one day history of exertional dyspnoea and chest discomfort. He had been having leg swelling on and off for several weeks. He had no history of diabetes mellitus or hypertension, but admitted to smoking. He had been in the Detention Centre for seven months.

His pulse was 120/min with a blood pressure of 140/56 mmHg. There was bilateral pitting oedema up to the knees and the jugular venous pulse was 12cm. There were no cardiac murmurs



**Case 2: December 7, 1992**



**Case 2: December 15, 1992**

or lung crepitations. No neurological deficits were elicited. His investigations were as follows:

- Haemoglobin - 11.9g%
- Blood urea - 3.6mmol/L
- Creatinine phosphokinase - 240 u/l (within normal)
- ECG - entirely normal
- Chest X-Ray - cardiomegaly with CT ratio of 15.7/25.2

Frusemide 40mg bid was started on December 8, 1992 and oral thiamine was commenced on December 10. By December 14, his pulse had settled to 80/min with a blood pressure of 110/80mmHg. The ankle oedema had resolved by then and the the chest X-ray showed a normal sized heart (C.T. ratio - 12.2./27.4).

### Case 3



BH, a 25-year-old illegal East Timorese immigrant was brought in from the detention camp on December 9, 1992, complaining of epigastric pains for the previous two days associated with anorexia and vomiting. He had come to Malaysia 1½ years before and had been in the detention camp for illegal immigrants for the previous five months.

On examination, he was afebrile and did not appear overtly malnourished. There was no jaundice or pallor. His liver was 4cm below the costal margin and there was epigastric tenderness. The abdomen was otherwise soft. Signs of cardiac decompensation were not specifically looked for. Neither was an ECG or an X-ray done.

He was diagnosed as a case of acute gastritis and given magnesium trisilicate and buscopan tablets. He collapsed suddenly at 10pm on December 10 and died despite attempts of resuscitation. His temperature and blood pressure charts were all normal up till the last reading before the collapse. Investigations done earlier included:

- Haemoglobin - 15g%

## CASE REPORT



**Electrocardiograms of Case 1**

- Total white count - 11,500/m<sup>3</sup>, Polymorphs = 68%
- Platelets - 130,000
- Blood urea - 7.5mmol/L
- Serum potassium - 4.9mmol/L
- Random blood sugar - 5.2mmol/L
- Serum amylase - 43u/l

A post-mortem was carried out. No intracranial bleed, pneumothorax, pericardial effusion, aortic rupture or perforated abdominal viscus was found. The heart was mildly enlarged and microscopy revealed some pink fluid in the alveoli. Microscopic examination of the liver, spleen, kidneys and brain was otherwise normal. A presumptive diagnosis of fatal ventricular arrhythmia secondary to cardiac beri-beri was made.

A dietary investigation revealed that provision of food for the 150 odd detainees in the centre had been subcontracted out to a private supplier at the rate of RM1.56 per person per day. This diet was grossly deficient in fresh vegetables. The first case, FD, also admitted to diet deficient in vegetables.

### Discussion

The diagnosis of thiamine deficiency in all three patients is based on their clinical presentations and on the rapid resolution of cardiac symptoms on institution of thiamine replacement. The development of mixed sensori-motor peripheral neuropathy in the first case, FSD, lends further support to the clinical diagnosis. Biochemical confirmation in the form of erythrocyte transketolase levels would have been very useful. This test is offered at the Institute for Medical Research but requires the specimen to be sent fresh. We did not get to do it because of the logistics involved.

The diagnosis of beri-beri for the third case, BH, might sound tenuous. However, the autopsy did not find any other cause of sudden death. There was no biochemical evidence of liver or kidney dysfunction. Nor was there any clinical evidence of infection. Given these negative findings, a ventricular arrhythmia appears to be the most probable cause of death. Munger R.G. *et al*<sup>5</sup> have suggested that thiamine deficiency can cause a prolonged QTc interval which in turn causes an increased propensity to fatal arrhythmias. Phua K.H. *et al*<sup>6</sup> conclude that cardiac beri-beri has several manifestations including an acute, pernicious type that is fatal without clearcut signs of heart failure. They go on to note that "one distressing symptom was an intense pericardial agony often felt in the epigastrium and the feeling of heaviness, constriction and oppression." As BH's diet was grossly deficient in thiamine, cardiac beri-beri with fatal ventricular arrhythmia appears to be the most likely cause of death.

There was a regrettable delay in the diagnosis of beri-beri in FSD, the first case. Though high-output cardiac failure was diagnosed and careful physical examination made for thyrotoxicosis intracardiac shunts, valvular heart diseases as well as for peripheral atriovenous fistulae, the possibility of thiamine deficiency was not entertained during his first admission. A diagnosis at that stage would have spared FSD considerable neurological morbidity and might have averted BH's death. The recent influx of immigrant labour to Malaysia poses this additional challenge to clinicians. We will now see diseases which are not common in our population and therefore, the differential diagnoses and schemata developed in relation to the Malaysian population may be inadequate when dealing with illnesses in immigrant workers who often are unable to give a coherent history.

### Acknowledgements

Perpustakaan Perubatan Universiti Malaya and Dr. T.K. Lim, National University of Singapore were very helpful in tracing and providing papers on beri-beri. Mr. S.K. Chang and Mr. T. Elyas rendered invaluable assistance in the preparation of the manuscript and the photographs. I also wish to thank the Director-General of the Ministry of Health for permission to publish this article.

### References

1. Braunwald E. Harrison's Principles of Internal Medicine (Eleventh Edition) : 412-13.
2. Daniel C.W. Observations in the Federated Malay States on Beri-beri. Studies from the Institute of Medical Research, Federated Malay States, 1906 : 4,1.
3. Hawes R.B. *et al*. The treatment of acute cardiac beri-beri or "shoshin" with massive doses of Vitamin B1. 7 Mal. Br BMA 1937;1(2) : 87-96.
4. Munger R.G. *et al* Prolonged QT interval and risk of sudden death in South-East Asian men. Lancet 1991;338 : 280-81.
5. Phua K.H. *et al*. Thiamine deficiency and sudden deaths: lessons from the past. Lancet 1991;335 : 1471.