

# Absent Pulmonary Valve Syndrome - A Case Report

S.P. Ram, MD\*

M.K. Lim, MRCP\*\*

A. Mazeni, MRCP\*\*

\* *Department of Paediatrics, Hospital Universiti Sains Malaysia,  
16150 Kubang Kerian, Kelantan.*

\*\* *National Heart Institute, Jalan Tun Razak, Kuala Lumpur.*

## Summary

A 7-year old female child was admitted for recurrent bronchopulmonary since one week of life. She was diagnosed to have ventricular septal defect and was treated conservatively. At seven years of life, repeat echocardiogram revealed a large perimembranous ventricular septal defect, absent pulmonary valve with overriding of aorta, narrow pulmonary artery annulus, and dilated main pulmonary artery and its branches. She was treated conservatively, discharged and followed-up at the National Heart Institute Kuala Lumpur, for corrective surgery.

**Key words:** Tetralogy of Fallot, Absent pulmonary valve.

## Introduction

Cheevers in 1947 described tetralogy of Fallot (TF) with absent pulmonary valve (APV). This condition comprises of ventricular septal defect, absent pulmonary valve, annular stenosis and dilatation of either the pulmonary trunk or one or both of its branches<sup>1</sup>. We describe a female child with tetralogy of Fallot associated with absent pulmonary valve.

## Case report

A seven-year old female child was examined as an outpatient for recurrent bronchopneumonia and failure to thrive since one week of life and recurrent wheeze for the past seven years. This baby was born at term by spontaneous vertex delivery and cried at birth. She was the eldest of the two siblings and her parents were unrelated. The younger male child was normal. Her development and milestones were normal. At one month of age she was diagnosed to have a small to moderate perimembranous ventricular septal defect and was treated conservatively.

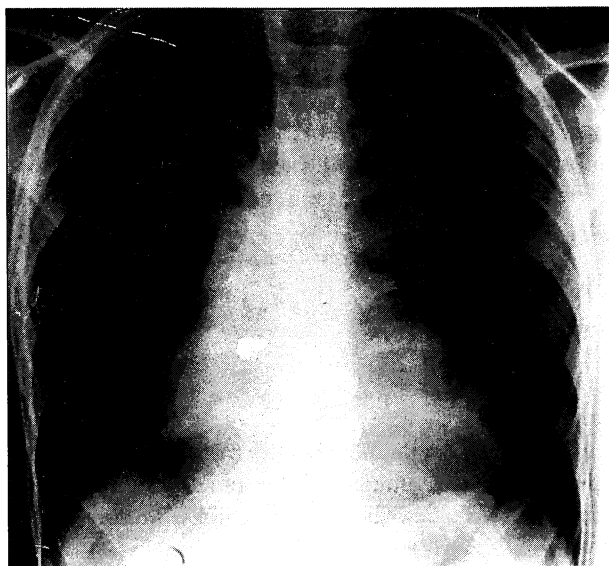
On examination, she was tachypnoeic, afebrile but was not cyanosed or clubbed. Her weight was 16.5 kg (25th to 50th centile) and height 117cm (25th to 50th centile). The pulse was 110/minute, regular, respiratory rate 30/minute and BP 90/60 mm Hg. Cardiovascular examination revealed an apex beat seen and felt at the left fifth intercostal space 2 cm lateral to midclavicular line, a normal first and single second heart sounds with systolic thrill, grade 4/6 mid-systolic and diastolic murmurs over the left third and second intercostal space respectively. Auscultation of the lungs showed normal

## CASE REPORT

breath sounds with bilateral scattered rhonchi. Liver was palpable 1 cm below the right costal margin. Other systems were normal.

Investigations revealed: haemoglobin 15 g/dl, PCV 38 per cent and no evidence of toxic granules in the peripheral smear. The chest X-ray showed plethoric lung fields with huge dilatation of the main pulmonary artery-associated with cardiomegaly (Fig 1). Twelve-lead electrocardiogram (ECG) revealed sinus rhythm, QRS axis  $+30^\circ$ , monophasic R waves measuring 12 mm in leads aVR, V1 and V2. Two dimensional echocardiogram (2D ECHO) showed a large perimembranous ventricular septal defect, overriding of aorta, dilated main, right and left pulmonary arteries, absent pulmonary valve and narrow pulmonary artery annulus.

Follow up of the child during the seven years showed recurrent wheeze, cough and failure to thrive. She was treated for acute respiratory tract infection six months ago and was last seen one month ago for an acute abdomen which was treated conservatively.



**Fig. 1 :** The chest x-ray showing plethoric lung fields with huge dilatation of main pulmonary artery associated with cardiomegaly.

### Discussion

The incidence of APV is 2.4 per cent to 6.3 per cent of patients with TF. The main abnormality in APV is either completely absent or rudimentary connective tissue at the pulmonic valve. The site of obstruction in APV is pulmonary annulus. The infundibulum is dilated and is more commonly associated with aneurysmal dilatation of the pulmonary trunk and one or both of its central branches. Emmanouilides *et al*<sup>3</sup> postulated that the disturbed intrauterine haemodynamics associated with absent foetal ductus arteriosus is the cause for the dilated pulmonary trunk and its branches. The altered haemodynamics in children with TF associated with APV include increase in right ventricular stroke volume due to regurgitant flow across the said pulmonary valve and absent ductus arteriosus leading to dilatation of central pulmonary arteries<sup>4</sup>. The clinical features in infants with APV include wheezing, right ventricular failure, emphysema, atelectasis, pulmonary infection and rarely sudden death. The degree of cyanosis in patients with APV diminishes with increasing age<sup>5</sup>.

The infundibular dilatation in patients with APV is seen in chest X-ray as a hump-shaped shadow

on the left side. Two-dimensional echocardiography is useful in delineating the dilated pulmonary trunk with echo-dense ridges at the expected site of the pulmonic valve<sup>4, 6</sup>.

The major complications in children with TF with APV are due to compression of trachea and major bronchi by dilated pulmonary arteries and minor bronchi by abnormal branching patterns of intrapulmonary arteries and also right ventricular failure due to nonrestrictive ventricular septal defect. Thus, prognosis in children with APV is related to the extent of tracheobronchial compression by the dilated central pulmonary arteries<sup>7</sup> and right ventricular failure.

Various modalities of surgical therapy for children with APV in TF like aneurysmorrhaphy, aneurysmectomy, transection of the dilated pulmonary artery have so far been found to be ineffective<sup>7</sup>. Recently Calder et al described corrective surgery with or without replacement of pulmonary valve done in older children may be useful in TF with APV<sup>8</sup>.

In this child, the findings like recurrent bronchopneumonia since one week of life, later on recurrent wheeze for the past seven years, failure to thrive, absence of cyanosis, aneurysmal dilatation of the pulmonary trunk in the chest X-ray, monophasic R wave in V1 and V2 in ECG and 2D ECHO features of absent pulmonary valve, overriding aorta, narrow pulmonary artery annulus and dilated main pulmonary artery and its branches were suggestive of TF with APV syndrome. The cause of recurrent wheeze in this child is probably due to large dilated right pulmonary artery compressing the right main stem bronchus.

This case report highlights that absence of cyanosis does not rule out TF and the definitive role of 2D ECHO in delineating the exact type of TF. The need for close monitoring and follow-up of all ventricular septal defects and if needed to revise the initial diagnosis, as described in this child, is emphasised.

### Acknowledgement

We thank Dr. (Mrs.) Uma K. for her help in preparing this manuscript.

### References

1. Cheevers N, Retrecissement Congenital de l'oritice Pulmonaire. Arch Med Fourth Series 1947;15 : 488-9.
2. Lev M, Eckner FA. The pathological anatomy of tetralogy of Fallot and its variations. Dis Chest 1964; 45 : 251-2.
3. Emmanouilides GC, Thanououlos B, Siassi B *et al*. Agenesis of ductus arteriosus associated with the syndrome of tetralogy of Fallot and absent pulmonary valve. Am J Cardiol 1976; 37 : 403-4.
4. Perloff JK. Ventricular septal defect with pulmonary stenosis N: Perloff JK, eds. The clinical recognition of congenital heart disease. Philadelphia; WB Saunders Company, 1987;431-2.
5. Pinsky WW, Nihill MR, Mullins CE *et al*. The absent pulmonary valve syndrome. Circulation 1978;57 : 159-60.
6. Disegni JA, Pieroni DR, Gingell RL. Familial pulmonary atresia. Am J Dis Child 1980;134 : 506-7.
7. Emmanouilides GC, Robin W, Doroshov W. Congenital absence of the pulmonary valve. In: Adams FH, Emmanouilides GC, Riemenschneider TA, eds, Moss' heart disease in infants, children and Adolescents 4th ed. Baltimore: Williams and Wilkins, 1989; 306-7.
8. Calder AL, Brandt PW, Barret-Boyes BG *et al*. Variant of tetralogy of Fallot with absent pulmonary leaflets and origin of one pulmonary artery from the ascending aorta, Am J Cardiol 1980;45 : 106-7.