

Extraskkeletal Osteosarcoma of the Thigh

K.S. Dhillon, FRCS*

S. Suntharalingam, FRCS*

H.J.W. Maurer**

* Dept. of Orthopaedic Surgery, University Hospital, Kuala Lumpur.

** Dept. of Radiology, University Hospital, Kuala Lumpur.

Summary

To our knowledge extraosseous osteosarcoma has not been reported in the Malaysian literature. We report a case of extraosseous osteosarcoma which was treated by intra-arterial chemotherapy, embolization, wide resection of tumour and salvage of limb with good functional result.

Key word: Osteosarcoma.

Introduction

Extraskkeletal osteosarcoma is a rare mesenchymal neoplasm characterised by production of osteoid or bone but has no connection with the skeletal structure. Though first reported by Wilson in 1941, upto 1988 a total of 250 cases has been reported in the English literature (Bane *et al*)¹. Extraskkeletal osteosarcoma unlike skeletal osteosarcoma occurs predominantly in persons older than 30 years. Prognosis appears to be poor and the best mode of treatment of this tumour remains uncertain.

Here we report a case of extraskkeletal osteosarcoma of the left thigh in a 49 year old male which was treated by intra-arterial adriamycin infusion, with gel-foam embolization of the tumour followed by complete resection of the tumour with good post operative functional result.

Case Report

A 49 year old Malay male presented to us in October 1990 with a history of left thigh swelling of one year's duration. The swelling when first noticed by the patient was about 1 cm. by 1.5 cm. in size on the anterior aspect of left upper thigh. It gradually increased in size over a one year period and initially was pain-free and did not affect his daily activities. Two months prior to consultation, he felt some discomfort over the swelling and noticed associated reddish discoloration of the skin over the swelling. There was no previous history of trauma or radiation to that part of the thigh. There was no history of weight loss, fever, cough or haemoptysis.

On examination, there was a 15 by 20 cm. swelling on the anterior lateral aspect of the left thigh extending from the inguinal ligament to the mid thigh. It was non-tender, warm, firm with diffuse margin and attached to the quadriceps muscles. There was no attachment to the bone. There was also an erythematous discoloration of the skin in the lower part of the swelling. There was no neurovascular involvement and the overlying skin was not adherent to the swelling.

Blood biochemistry including alkaline phosphatase was normal except for a raised erythrocyte sedimentation rate of 90 mm/hr. Radiograph of the left femur showed a large soft tissue swelling with a small area

CASE REPORT

of calcification in the soft tissue. The bone was normal with no evidence of periosteal reaction. A C.T. scan of the left thigh (Fig 1) showed a large soft tissue mass in the anterior thigh extending from 2 cm. proximal to the greater trochanter to the mid-thigh measuring 9.5 cm x 11.5 cm x 24 cm. A few spots of calcification were seen in the lower part of the mass. The femur was normal and there was no periosteal new bone formation. A C.T. scan of the lungs was normal. A technetium diphosphate bone scan showed no evidence of bony involvement.

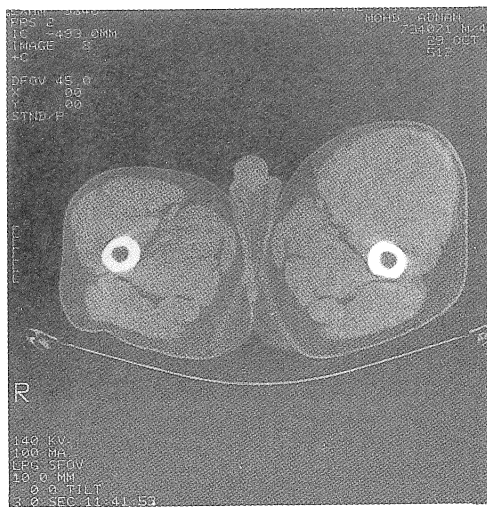


Fig. 1: A C.T. scan of both thighs showing a large soft tissue mass on the anterior aspect of the left thigh measuring 9.5 cm x 11.5 cm x 24 cm

An incision biopsy of the tumour was carried out and histopathology of the tumour showed it to be an extraskeletal osteosarcoma.

An angiography (Fig 2) was carried out to delineate the extent and vascularity of the tumour and for tumour embolization prior to limb salvage surgery.

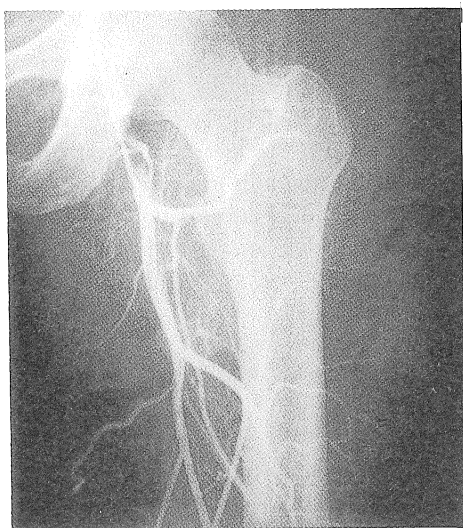


Fig. 2: A left femoral angiography showing a vascular soft-tissue tumour with feeder vessels from the profunda femoris artery.

Infusion of adriamycin followed by Gel-foam embolization was carried out on 23rd November 1990. This was followed by remarkable regression of the tumour. On 30th November 1990 wide resection of the tumour was carried out with preservation of the femoral artery and vein which were not involved. At operation, 90% of the bulk of the quadriceps was removed along with the tumour. Post-operatively the limb was immobilised in a long leg plaster-of-paris slab till the wound healed. This was followed by post operative chemotherapy consisting of vincristine, cisplatin, adriamycin and cyclophosphamide. After three courses, the patient refused further chemotherapy. At 30 months following surgery he is well with no evidence of recurrence.

Pathology

The gross appearance of the open biopsy showed fragments of brownish tissue 4 cm. in aggregate. The histology showed a highly malignant tumour with extensive areas of necrosis and haemorrhage. Viable areas showed proliferation of malignant polygonal to spindle cells, all of which had markedly pleomorphic hyperchromatic nuclei exhibiting brisk abnormal mitosis. Numerous osteoclastic type of giant cells were noted throughout the viable areas, accompanied by proliferation of malignant tumour giant cells. Osteoid production (Figure 3) by malignant cells was prominent in several foci.

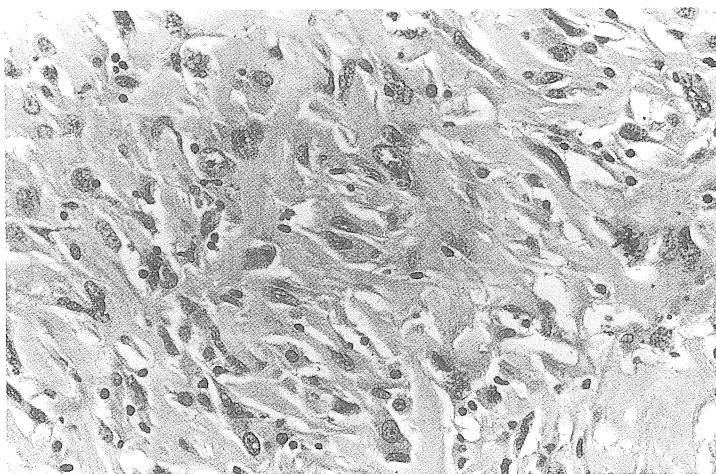


Fig. 3: Photomicrograph of extraosseous osteosarcoma showing many spindle cells with abundant osteoid in stroma. Moderate cellular pleomorphism and frequent atypical mitosis seen. (H and E x 250).

The subsequent specimen sent on excision of the tumour measured 30 cm. x 18 cm. x 6 cm. weighing 1.7 kg. The histology appearance of this tumour was similar to the biopsy specimen and was consistent with the diagnosis of extraskeletal osteosarcoma. The surgical margins were free of tumour.

Discussion

Extraskeletal osteosarcoma is a rare soft tissue tumour which has been reported to constitute approximately 4% of osteosarcomas and 1.2% or less of all soft tissue sarcoma (Wurlitzer *et al*)². It should be differentiated from myositis ossificans, paraosteal osteosarcoma and a variety of sarcomas with osteoid formation viz. malignant fibrous histiocytoma. The histological and clinicopathological differentiation from benign, reactive pseudo malignant processes of soft tissue and other sarcoma has been addressed by previous authors (Bane *et al*)¹.

CASE REPORT

Tumour size has been found to be the only predictor of final outcome (Bane *et al*)¹. Tumours smaller than 5 cm. have better prognosis. Tumour pattern, cellularity, nuclear pleomorphism, tumour necrosis and mitotic activity have not been found to be significant prognostic factors (Bane *et al*)¹.

Definitive statements regarding the best mode of treatment have been precluded by the small number of patients and varied treatment regimes used in each published series.

Following the principles of treatment of skeletal osteosarcoma and other soft tissue sarcomas, we treated this patient with wide excision of the tumour followed by chemotherapy. Amputation was avoided and limb salvage became feasible in the patient with a large tumour due to use of pre-operative intra-arterial adriamycin infusion and gel foam embolization of the tumour. Excision of about 90% of the quadriceps was consistent with satisfactory function of the lower limb. Patient attained full range of motion of the left knee with a mild extension lag and was able to ambulate without a splint, brace or other aids.

Acknowledgement

The authors wish to thank Ms. Sharmini Devi for typing the manuscript and the Medical Illustration Unit, Medical Faculty, University of Malaya for photographs.

References

1. Bane B.L., Evan H.L., Ro.J.Y. *et al*. Extraskkeletal osteosarcoma. A clinopathologic review of 26 cases. *Cancer* 1990;12 : 2762-2770.
2. Wurlitzer F., Ayala A., Romsdahl, M. Extraosseous osteogenic sarcoma. *Arch. Surg.* 1972;105 : 691-695.